

Whipple's Disease

Wilfried Obst Ulrike von Arnim Peter Malfertheiner

Department of Gastroenterology, Hepatology and Infectious Diseases, Otto von Guericke University of Magdeburg, Germany

Keywords

Whipple's disease · Malabsorption syndrome · *Tropheryma whipplei*

Summary

Background: Whipple's disease (WD) is rarely the cause of a malabsorption syndrome. The disease is a chronic infection of the intestinal mucosa with the bacterium *Tropheryma whipplei*, which leads to a lymphostasis with an impaired absorption of the nutrition. Due to its low incidence (1:1,000,000) and the non-specific early symptoms, the disease is often diagnosed only after many years. **Methods:** Based on a selective literature review and the clinical experience of the authors, the current knowledge of WD regarding pathogenesis, clinical presentation, diagnosis, and therapy are presented in this paper. **Results:** Recent studies suggest that a host-specific dysfunction of the intestinal macrophages is responsible for the chronic infection with *T. whipplei*. Prior to patients reporting symptoms of a malabsorption syndrome (chronic diarrhea/steatorrhea, weight loss), they often suffer from non-specific symptoms (polyarthralgia, fever, fatigue) for many years. Misdiagnoses such as seronegative polyarthritis are frequent. Furthermore, neurological, cardiac, ocular, or dermatological symptoms may occur. The standard method concerning diagnosis is the detection of PAS(periodic acid-Schiff)-positive macrophages in the affected tissues. Immunohistochemical staining and PCR(polymerase chain reaction)-based genetic analysis increase the sensitivity and specificity of conventional detection methods. Endoscopically, the intestinal mucosa appears edematous with lymphangiectasias, enlarged villi, and white-yellowish ring-like structures. The German treatment recommendations include a two-week intravenous induction therapy with ceftriaxone, which is followed by a three-month oral maintenance therapy with trimethoprim/sulfamethoxazole. **Conclusion:** WD is rarely responsible for a malabsorption syndrome. However, if WD is not recognized, the disease can be lethal. New diagnostic methods and prospectively approved therapeutic concepts allow an adequate treatment of the patient. Due to the host-specific susceptibility to *T. whipplei*, a lifelong follow-up is necessary.

Schlüsselwörter

Morbus Whipple · Malabsorptionssyndrom · *Tropheryma whipplei*

Zusammenfassung

Hintergrund: Der Morbus Whipple kann selten die Ursache für ein Malabsorptionssyndrom sein. Ursächlich ist eine chronische Infektion der intestinalen Mukosa mit dem Bacillus *Tropheryma whipplei*, die zu einem Lymphstau mit einer gestörten Aufnahme der Nahrung führt. Aufgrund der geringen Inzidenz (1:1 000 000) und des unspezifischen Symptombeginns wird die Erkrankung oft erst nach vielen Jahren diagnostiziert. **Methoden:** Anhand einer selektiven Literaturrecherche sowie der klinischen Erfahrungen des Autorenteam werden aktuelle Erkenntnisse der Pathogenese, der klinischen Symptomatik sowie der Diagnostik und Therapie der Erkrankung dargestellt. **Ergebnisse:** Aufgrund aktueller Studien wird vermutet, dass eine wirtsspezifische Fehlfunktion der intestinalen Makrophagen ursächlich für die chronische Infektion mit *T. whipplei* ist. Bevor die Patienten über Symptome eines Malabsorptionssyndroms (chronische Diarrhö/Steatorrhö, Gewichtsverlust) klagen, leiden sie oft langjährig an unspezifischen Beschwerden (Polyarthralgien, Fieber, Abgeschlagenheit). Fehldiagnosen wie eine seronegative Polyarthritis sind in dieser Phase häufig. Neben klassischen Symptomen können neurologische, kardiale, okuläre oder dermatologische Symptome im Vordergrund stehen. Der Goldstandard der Diagnostik ist der Nachweis von PAS(periodic acid-Schiff)-positiven Makrophagen in den befallenen Geweben. Immunhistochemische Färbungen sowie PCR(Polymerasekettenreaktion)-basierte Genanalysen erhöhen die Sensitivität und Spezifität der gängigen Nachweismethoden. Endoskopisch wirkt die Darmmukosa ödematös, zeigt Lymphektasien und bildet weiß-gelbliche Tropfen aus. Die deutschen Therapieempfehlungen beinhalten eine zweiwöchige intravenöse Induktionstherapie mit Ceftriaxon, die von einer dreimonatigen oralen Erhaltungstherapie mit Trimethoprim/Sulfamethoxazol gefolgt wird. **Schlussfolgerung:** Der Morbus Whipple ist nach wie vor selten für ein Malabsorptionssyndrom verantwortlich. Wenn die Erkrankung jedoch nicht erkannt wird, kann diese für die Betroffenen fatal enden. Neue Diagnoseverfahren sowie prospektiv geprüfte Therapiekonzepte erlauben eine adäquate Behandlung der Patienten. Aufgrund der wirtsspezifischen Suszeptibilität gegenüber *T. whipplei* ist jedoch eine lebenslange Nachsorge notwendig.

Introduction

Malabsorption is caused by a number of diverse etiologies. A rare cause of impaired absorption of nutrients is Whipple's disease (WD). WD is a chronic infection of the small bowel with the bacterium *Tropheryma whipplei*. The bacterium is phagocytized by immunocompetent cells of the myeloid type, but is only lysed incompletely [1]. The English pathologist George H. Whipple first described the disease in 1907. The autopsy of a patient diagnosed with chronic diarrhea/steatorrhea, weight loss, and fever revealed fat accumulations of the small intestine as well as of the mesenteric lymph nodes. Initially, WD has been regarded as intestinal lipodystrophy [2]. In 1961, electron microscopy visualized the gram-positive, nonacid-fast, PAS(periodic acid-Schiff)-positive bacillus in macrophages. The clinical symptoms of WD include chronic diarrhea, malnutrition (weight loss), migratory polyarthralgia, abdominal pain, and/or enlarged lymph nodes [3, 4]. WD is a multisystem disease which additionally infects the nervous system, heart, and skin. Upper gastrointestinal endoscopic biopsies of the small intestine lead to the diagnosis. Morphological changes of the duodenal mucosa membrane are already seen during endoscopy [5, 6]. The diagnosis of WD is based on PAS staining of the duodenal biopsies. Villous atrophy is a second major finding in histology [7, 8]. In order to prevent complications, therapy with antibiotics is started immediately after the diagnosis of WD is established. Without suitable treatment the disease can be lethal. The standard therapy scheme in Germany comprises a two-week intravenous administration of ceftriaxone or meropenem followed by a maintenance therapy with trimethoprim/sulfamethoxazole (co-trimoxazole) over 1 year [9]. However, a current study suggests that a reduction of the co-trimoxazole administration to 3 months has the same efficacy [10]. Due to a high risk of relapse, regular check-ups are indicated to evaluate the success of the therapy. As circumstances demand, it is sensible to undertake genotyping and testing for a resistance to antibiotics if the therapy should fail.

Epidemiology

In the older literature, the incidence of WD is estimated to be less than 1 case in 1,000,000 people [11]. Due to an increased clinical awareness as well as improved diagnostic tools the number of case reports continuously increased in recent years. Hence, it can be assumed that the disease occurs more often than expected [2]. There is a predisposition for white Caucasian men around 55 years of age. A male:female ratio of 2–3:1 shows that males are predominantly affected [3, 12]. Predisposing genetic factors are MHC(major histocompatibility complex)-II/HLA (human leucocyte antigen) alleles DRB1*13 and DQB1*06 [13]. Besides classic WD, French ex-

aminations prove that the bacterium populates asymptomatic carriers. Hence, in tests on the French population, *T. whipplei* DNA has been isolated in 4.0% of stool samples [14] and 0.6% of saliva samples [15]. High prevalences (approximately 12%) were found in workers who were responsible for the cleaning of sewers. An even higher prevalence was found in fecal cultures of infants (2–4 years of age) who suffered from diarrhea. A French study from 2008 showed that approximately 15% of gastroenteritides in infants were caused by *T. whipplei* [16].

Microbiology and Pathogenesis

T. whipplei is a gram-positive, GC-rich bacterium which is, taxonomically, closely related to the group of *actinomyces* and *mycobacteria* [17]. Polymerase chain reaction (PCR) analyses attest to the ubiquitous occurrence of the bacterium in a natural environment [18]. Sewers seem to form an ecological niche as high concentrations of *T. whipplei* DNA have been detected [14]. By now, 72 genotypes are known which were identified through four highly variable gene sequences via PCR analyses [19, 20]. The most common genotypes in Europe are 1 and 3 which lead to smaller endemic infections in the form of gastroenteritis [19]. The wall of the bacterium consists of mucopolysaccharides, which are stained red by the PAS (periodic acid-Schiff) reaction. The bacterium uses essential metabolic pathways and depends on the metabolism of other cells like macrophages of the small intestine [21]. Histologically, the macrophages are presenting as foam cells with an intercellular, argyrophilic, rod-shaped structure. The surrounding intestinal mucosa is atrophic with single, 'plump' villi. Furthermore, a consistent fat accumulation occurs in the lamina propria as well as in the adjacent lymph nodes. This was the reason for the first description of 'intestinal lipodystrophy' by George H. Whipple [2, 22].

The course of *T. whipplei* infections has a wide range. No relationship of a certain genotype of the bacterium and the occurrence of WD has been found yet [19]. It can be assumed that specific traits of the host are responsible for the chronic course of the illness [13, 23]. An association between HLA alleles DRB1*13 and DQB1*06 has been suggested [13]. The impaired function of the macrophages seems to be responsible for the development of WD. Moos et al. [24] showed that *T. whipplei*, specifically in WD patients, triggers a differentiation from monocytes to M2/alternative-activated macrophages. This subclass of macrophages does not show a defect in the phagocytosis of *T. whipplei*, but an inability to degrade the bacterium in its entirety [1]. The bacterium also causes an impaired immunomodulation with an increased IL-16 secretion, a reduced IL-10 production, and a dysregulation of mucosal T helper cells [24, 25]. Further immunological anomalies were described but will not be taken into account in this paper due to their complexity.

Clinical Presentation

On the basis of organ involvement, WD can be divided into three forms: i) classic WD, ii) endocarditis-associated WD, and iii) isolated neurological WD [4, 26]. The clinical symptoms are heterogeneous and challenge differential diagnoses, such as rheumatic diseases, vasculitides, AIDS enteropathy, tuberculosis, or other chronic granulomatous diseases (Crohn's disease, sarcoidosis) [2].

Classic Whipple's Disease

Most patients (about 80%) develop the classic/systemic form of WD [3]. It has a bimodal course with a prodromal and a progressive phase [4]. In the prodromal phase, nonspecific symptoms such as arthralgia/arthritis, fever, fatigue, or lymphadenopathy are dominant. Laboratory tests often show an elevation in C-reactive protein (CRP), in the erythrocyte sedimentation rate (ESR), and in the white blood cell and platelet count. Furthermore, iron deficiency anemia, hypocalcemia, and hypoalbuminemia may be present as an expression of a malabsorption syndrome. Approximately 65–90% of the patients have joint problems [3, 26]. Patients report a migrating polyarthritis of the peripheral joints (ankles, shoulders, knees, wrists, hands) and of the axial system. In severe cases and a long-term history, a destructive joint involvement can occur [3]. The seronegativity of the rheumatoid factors leads to the diagnosis of seronegative poly-/oligoarthritis. The use of immunosuppressive therapy, especially TNF- α receptor antagonists, worsens the clinical picture [27]. Antibiotic therapy for treatment of urinary tract infection or pneumonia is followed by a short-term improvement of the arthralgia.

With an average latency of 6–8 years, WD changes into its progressive form which is characterized by gastrointestinal and neurological symptoms [28]. Furthermore, psychological, renal, dermatological (including pigmentation), or ocular pathologies are described [29, 30]. Gastrointestinal manifestations due to WD occur in about 70% of the cases [3]. They include typical symptoms of a malabsorption syndrome such as weight loss, diarrhea/steatorrhea, and deficiency symptoms such as anemia or hypoalbuminemia. The weight loss is on average 11 kg (range: 3–36 kg) [3]. The diarrhea is usually watery and occurs episodically with colicky abdominal pain. A pure steatorrhea is rather rare. The chronic *T. whipplei* infection rarely causes a hepato- and splenomegaly or is responsible for the development of ascites [26, 31].

Isolated Neurological Manifestations

In addition to a neurological involvement of classic WD, an isolated manifestation of the central nervous system (CNS) can also occur. Several case reports have been published on this topic [32, 33]. The isolated neurological involvement is much rarer than systemic WD, with patients having an average age of 47 years (range 30–56 years) [33]. Depending on the infestation, the spectrum of neurological symptoms is

wide. Patients complain of headaches, cognitive dysfunctions, and eye motility disorders. In particular, progressive supranuclear ophthalmoplegia in combination with oculomasticatory myorhythmia or oculofacioskeletal myorhythmia is considered as a pathognomonic symptom [31]. Other symptoms are insomnia, ataxia, focal cerebral features, or epilepsy [33].

Diagnosis

The diagnosis of WD is made on the basis of its typical clinical appearance and by the detection of *T. whipplei* or its specific DNA sequences. Depending on the infestation, biopsies of the affected tissue or liquid (cerebrospinal fluid (CSF), synovial fluid) are necessary. However, samples of the distal duodenum must always be taken to exclude the classic WD from an isolated organ infection. Histopathological staining and PCR are routinely used in diagnostics. Further detection methods are cultivation, serological detection of specific antibodies, and electron microscopy. Furthermore, endoscopic features provide indirect evidence for an intestinal infection. A diagnostic algorithm for the detection of WD is shown in figure 1.

Histopathological Staining

After staining biopsies with the PAS reaction, *T. whipplei* presents as magenta-colored particles within foamy macrophages. As a possible differential diagnosis, the *Mycobacterium avium* complex, also staining PAS-positive, comes into consideration. Thus, a Ziehl-Neelsen staining should be done for differentiation. The sensitivity of the PAS staining of small bowel biopsies depends on the infestation and ranges from 71% for neurological WD up to 78% for intestinal WD. If there is the suspicion of a neurological involvement, a PAS staining of the CSF or of a CNS biopsy should be done [7]. Additional immunohistochemical staining with *T. whipplei* antibodies helps to differentiate inaccuracies, especially PAS-negative tissue, due to a higher sensitivity and specificity [8].

Polymerase Chain Reaction

Besides histological staining, PCR is the second cornerstone in the diagnosis of WD. It should be carried out in parallel with the histological examination. Conventional PCR comprises the detection of the specific 16S rRNA of the bacterium. It can be extracted from histological and liquid material. In particular, a PCR analysis of the CSF should be done for each suspicion of WD in order to exclude a neurological involvement. More recent methods use the quantitative real-time PCR for the detection of specific 16S-23S rRNA intergenic spacer regions, repeated gene sequences, or the *rpoB* gene [34]. The advantages of these new targets are a lower risk of contamination and a shorter detection time. They are also characterized by a higher sensitivity at the same specificity, but are only available for special centers.

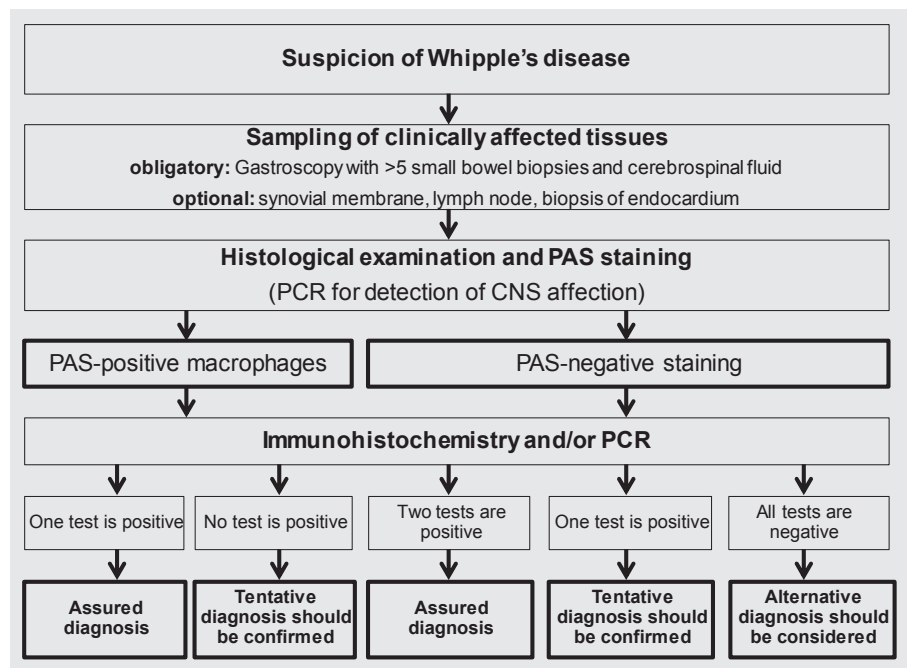


Fig. 1. Diagnostic algorithm for the detection of Whipple's disease (modified according to [40]).

Serological Antibodies

Serological antibodies play a minor role in the current routine diagnosis of WD. The determination is only possible in designated reference centers. Studies have shown that antibodies against *T. whipplei* do not only occur in patients with WD but also in healthy subjects and asymptomatic carriers [35]. Interestingly, they can even miss entirely in patients with classic WD. However, newly developed Western-Blot methods seem to differentiate serological antibodies between patients with classic WD and asymptomatic carriers [36].

Endoscopy

The upper gastrointestinal endoscopy is routinely performed in suspected WD. In addition to biopsies taken from the proximal and distal duodenum, it allows to make a first diagnosis. The endoscopic image of WD is variable but includes typical morphological changes such as mucosal erythema and edema, enlarged duodenal folds, small and large lymphangiectasias, enlarged villi, and white-yellowish ring-like structures inside of the villi [5]. In addition, new endoscopic features, such as chromoendoscopy with narrow band imaging (NBI), offer a finer representation of the mucosal alterations, including villi architecture disarrangement and altered lymphatic microvasculature [6].

Treatment

Before *T. whipplei* was identified as the cause of WD, many patients had already been treated with chloramphenicol, which led to an improvement of their clinical symptoms and survival [2]. Without antibiotic therapy, however, the disease was often

lethal. Up to now, there is no consensus on the type and duration of the antibiotic treatment. Different treatment protocols are in use in various countries. Each antibiotic therapy is based on the property of passing the brain-blood barrier. In Germany, the standard treatment comprises an intravenous induction therapy with ceftriaxone or meropenem for 14 days, followed by an oral maintenance therapy of trimethoprim/sulfamethoxazole (co-trimoxazole) for 12 months [9]. More recent data indicate that a reduction of the intake of co-trimoxazole to 3 months shows the same response as the 12-month therapy, with the risk of relapse not being increased [10].

In contrast to the German recommendations, a French group favors a combination of doxycycline and hydroxychloroquine for 1 year, followed by a lifelong administration of doxycycline along with stringent therapeutic drug monitoring [37]. The background for their recommendations are in vitro analyses of *T. whipplei* that revealed a natural resistance to trimethoprim and an acquired resistance to sulfamethoxazole [38]. Furthermore, in order to avoid a potential re-infection, a lifelong therapy with doxycycline should be taken into consideration. A selective overview of trials for the treatment of WD is shown in table 1.

Follow-up

In order to evaluate the success of treatment and to detect early treatment failures, all patients should undergo regular check-ups. These follow-ups include clinical, laboratory, and invasive investigations. Clinical symptoms should improve within a few weeks after starting the treatment. An instrumental re-evaluation is recommended for 6, 12, 24, and 36

Table 1. Selective overview of trials for establishing treatment concepts of WD

Studies	Publication year	Study design	n	Antibiotic regimes	Response rate	Duration of follow-up, months (mean)
Feurle and Marth [39]	1994	nonrandomized, partially retrospective trial	30	T or SXT	T: 13/22 SXT: 12/13	4–310 (111)
Feurle et al. [9]	2010	open-label, prospective, randomized trial	40	ceftriaxone or meropenem for 14 days, followed by SXT for 1 year	39/40 (1 patient positive PCR of the CSF)	71–128 (89)
Feurle et al. [10]	2013	open-label, prospective, non-randomized trial	40	ceftriaxone or meropenem for 14 days, followed by SXT for 3 months	36/37 (1 relapse after 63 months with <i>Tropheryma whipplei</i> arthritis)	54–102 (80)
Lagier et al. [37]	2014	retrospective, single-centre trial	29	SXT or D and H (\pm SXT or sulfadiazine)	SXT: 0/14 D/H: 13/13	7–264 (78.9)

SXT = Trimethoprim-sulfamethoxazole; T = tetracycline; D = doxycycline; H = hydroxychloroquine, PCR = polymerase chain reaction; CSF = cerebrospinal fluid.

months after diagnosis, and then annually for the first 3 years as well as every 3 years for the rest of the patient's life [22]. In follow-up examinations, subtyping of PAS-positive macrophages with an immunohistochemical staining of intestinal biopsies is the method of choice. The success of treatment is characterized by a progressive reduction of cytoplasmatic granularity and staining intensity. A transition from predominant subtype 1 macrophages to subtypes 2, 3, or 4 macrophages or to complete disappearance of PAS-positive macrophages demonstrates histological remission [36, 37]. In extraintestinal infestations, PCR is more sensitive than histolog-

ical staining and should be performed regularly. However, PCR analyses of stool or saliva are not suitable for the surveillance of patients with WD because of false-positive results of asymptomatic excretion of *T. whipplei* in healthy carriers [8].

Disclosure Statement

The authors of this publication declare that they have no conflicts of interest.

References

- Moos V, Schmidt C, Geelhaar A, Kunkel D, Allers K, Schinnerling K, Loddenkemper C, Fenollar F, Moter A, Raoult D, Ignatius R, Schneider T: Impaired immune functions of monocytes and macrophages in Whipple's disease. *Gastroenterology* 2010;138:210–220.
- Mönkemüller K, Fry LC, Rickes S, Malfertheiner P: Whipple's disease. *Curr Infect Dis Rep* 2006;8:96–102.
- Lagier J, Lepidi H, Raoult D, Fenollar F: Systemic *Tropheryma whipplei*: clinical presentation of 142 patients with infections diagnosed or confirmed in a reference center. *Medicine (Baltimore)* 2010;89:337–345.
- Biagi F, Trotta L, Corazza GR: Whipple's disease. *Intern Emerg Med* 2012;7:209–213.
- Mönkemüller K, Fry LC, von Arnim U, Neumann H, Evert M, Malfertheiner P: Whipple's disease: an endoscopic and histologic study. *Digestion* 2008;77:161–165.
- Neumann H, Mönkemüller K, Neurath M, Vieth M: Advanced endoscopic imaging using narrow-band imaging for diagnosis of Whipple's disease. *Endoscopy* 2012;44(suppl 2):E101.
- Olmos M, Smecuol E, Maurino E, Bai JC: Decision analysis: an aid to the diagnosis of Whipple's disease. *Aliment Pharmacol Ther* 2006;23:833–840.
- Baisden BL, Lepidi H, Raoult D, Argani P, Yardley JH, Dumler JS: Diagnosis of Whipple disease by immunohistochemical analysis: a sensitive and specific method for the detection of *Tropheryma whipplei* (the Whipple bacillus) in paraffin-embedded tissue. *Am J Clin Pathol* 2002;118:742–748.
- Feurle GE, Junga NS, Marth T: Efficacy of ceftriaxone or meropenem as initial therapies in Whipple's disease. *Gastroenterology* 2010;138:478–486; quiz 11–12.
- Feurle GE, Moos V, Bläker H, Loddenkemper C, Moter A, Stroux A, Marth T, Schneider T: Intravenous ceftriaxone, followed by 12 or three months of oral treatment with trimethoprim-sulfamethoxazole in Whipple's disease. *J Infect* 2013;66:263–270.
- Schneider T, Moos V, Loddenkemper C, Marth T, Fenollar F, Raoult D: Whipple's disease: new aspects of pathogenesis and treatment. *Lancet Infect Dis* 2008;8:179–190.
- Marth T, Raoult D: Whipple's disease. *Lancet* 2003;361:239–246.
- Martinetti M, Biagi F, Badulli C, Feurle GE, Müller C, Moos V, Schneider T, Marth T, Marchese A, Trotta L, Sachetto S, Pasi A, De Silvestri A, Salvaneschi L, Corazza GR: The HLA alleles DRB1*13 and DQB1*06 are associated to Whipple's disease. *Gastroenterology* 2009;136:2289–2294.
- Fenollar F, Trani M, Davoust B, Salle B, Birg M, Rolain J, Raoult D: Prevalence of asymptomatic *Tropheryma whipplei* carriage among humans and nonhuman primates. *J Infect Dis* 2008;197:880–887.
- Rolain J, Fenollar F, Raoult D: False positive PCR detection of *Tropheryma whipplei* in the saliva of healthy people. *BMC Microbiol* 2007;7:48.
- Raoult D, Fenollar F, Rolain J, Minodier P, Bosdure E, Li W, Garnier J, Richet H: *Tropheryma whipplei* in children with gastroenteritis. *Emerg Infect Dis* 2010;16:776–782.
- Raoult D, Ogata H, Audic S, Robert C, Suhre K, Drancourt M, Claverie J: *Tropheryma whipplei* Twist: a human pathogenic Actinobacteria with a reduced genome. *Genome Res* 2003;13:1800–1809.
- Schöniger-Hekele M, Petermann D, Weber B, Müller C: *Tropheryma whipplei* in the environment: survey of sewage plant influents and sewage plant workers. *Appl Environ Microbiol* 2007;73:2033–2035.
- Wetzstein N, Fenollar F, Buffet S, Moos V, Schneider T, Raoult D: *Tropheryma whipplei* genotypes 1 and 3, Central Europe. *Emerg Infect Dis* 2013;19:341–342.

- 20 Li W, Fenollar F, Rolain J, Fournier P, Feurle GE, Muller C, Moos V, Marth T, Altwegg M, Calligaris-Maibach RC, Schneider T, Biagi F, La Scola B, Raoult D: Genotyping reveals a wide heterogeneity of *Tropheryma whippelii*. *Microbiology* 2008; 154:521–527.
- 21 Bentley SD, Maiwald M, Murphy LD, Pallen MJ, Yeats CA, Dover LG, Norbertczak HT, Besra GS, Quail MA, Harris DE, von Herbay A, Goble A, Rutter S, Squares R, Squares S, Barrell BG, Parkhill J, Relman DA: Sequencing and analysis of the genome of the Whipple's disease bacterium *Tropheryma whippelii*. *Lancet* 2003;361:637–644.
- 22 Dutly F, Altwegg M: Whipple's disease and 'Tropheryma whippelii'. *Clin Microbiol Rev* 2001;14: 561–583.
- 23 Biagi F, Badulli C, Feurle GE, Müller C, Moos V, Schneider T, Marth T, Mytilineos J, Garlaschelli F, Marchese A, Trotta L, Bianchi PI, Stefano M, Cremaschi AL, Silvestri A, Salvaneschi L, Martinetti M, Corazza GR: Cytokine genetic profile in Whipple's disease. *Eur J Clin Microbiol Infect Dis* 2012; 31:3145–3150.
- 24 Moos V, Schneider T: The role of T cells in the pathogenesis of classical Whipple's disease. *Expert Rev Anti Infect Ther* 2012;10:253–255.
- 25 Ghigo E, Barry AO, Pretat L, Al Moussawi K, Desnues B, Capo C, Kornfeld H, Mege J, Rénia L: IL-16 promotes *T. whippelii* replication by inhibiting phagosome conversion and modulating macrophage activation. *PLoS One* 2010;5:e13561.
- 26 Fenollar F, Puéchal X, Raoult D: Whipple's disease. *N Engl J Med* 2007;356:55–66.
- 27 Gaddy JR, Khan ZZ, Chaser B, Scofield RH: Whipple's disease diagnosis following the use of TNF-blockade. *Rheumatology* 2012;51:946.
- 28 Marth T: New insights into Whipple's disease – a rare intestinal inflammatory disorder. *Dig Dis* 2009;27:494–501.
- 29 Dobbins WO 3rd: Whipple's Disease. Springfield, IL, Charles C. Thomas, 1987.
- 30 Louis ED, Lynch T, Kaufmann P, Fahn S, Odel J: Diagnostic guidelines in central nervous system Whipple's disease. *Ann Neurol* 1996;40:561–568.
- 31 Durand DV, Lecomte C, Cathébras P, Rousset H, Godeau P: Whipple disease. Clinical review of 52 cases. The SNFMI Research Group on Whipple Disease. *Société Nationale Française de Médecine Interne. Medicine (Baltimore)* 1997;76:170–184.
- 32 Compain C, Sacre K, Puéchal X, Klein I, Vital-Durand D, Houeto J, de Broucker T, Raoult D, Papo T: Central nervous system involvement in Whipple disease: clinical study of 18 patients and long-term follow-up. *Medicine (Baltimore)* 2013; 92:324–330.
- 33 Panegyres PK, Edis R, Beaman M, Fallon M: Primary Whipple's disease of the brain: characterization of the clinical syndrome and molecular diagnosis. *QJM* 2006;99:609–623.
- 34 Moter A, Schmiedel D, Petrich A, Wiessner A, Kikhney J, Schneider T, Moos V, Göbel UB, Reischl U: Validation of an rpoB gene PCR assay for detection of *Tropheryma whippelii*: 10 years' experience in a National Reference Laboratory. *J Clin Microbiol* 2013;51:3858–3861.
- 35 Bonhomme CJ, Renesto P, Nandi S, Lynn AM, Raoult D: Serological microarray for a paradoxical diagnostic of Whipple's disease. *Eur J Clin Microbiol Infect Dis* 2008;27:959–968.
- 36 Fenollar F, Amphoux B, Raoult D: A paradoxical *Tropheryma whippelii* western blot differentiates patients with whipple disease from asymptomatic carriers. *Clin Infect Dis* 2009;49:717–723.
- 37 Lagier J, Fenollar F, Lepidi H, Giorgi R, Million M, Raoult D: Treatment of classic Whipple's disease: from in vitro results to clinical outcome. *J Antimicrob Chemother* 2014;69:219–227.
- 38 Fenollar F, Rolain J, Alric L, Papo T, Chauveheid M, van de Beek D, Raoult D: Resistance to trimethoprim/sulfamethoxazole and *Tropheryma whippelii*. *Int J Antimicrob Agents* 2009;34:255–259.
- 39 Feurle GE, Marth T: An evaluation of antimicrobial treatment for Whipple's disease. Tetracycline versus trimethoprim-sulfamethoxazole. *Dig Dis Sci* 1994;39:1642–1648.
- 40 Moos V, Schneider T: Changing paradigms in Whipple's disease and infection with *Tropheryma whippelii*. *Eur J Clin Microbiol Infect Dis* 2011;30: 1151–1158.