

Luigi Mearini^a
Rachele Del Sordo^b
Elisabetta Costantini^a
Elisabetta Nunzi^a
Massimo Porena^a

^aUrology Department and ^bPathological
Anatomy and Histology Department,
University of Perugia, Perugia, Italy

Adrenal Oncocytic Neoplasm: A Systematic Review

Key Words

Oncocytoma · Adrenal gland · Adrenal oncocytic neoplasm

Abstract

Introduction: Oncocytic neoplasms as tumors arising in the adrenal glands are rare, usually considered as nonfunctional and benign. In the current literature, there are extremely limited reports of adrenal oncocytic neoplasms; as to date, only 147 cases have been described. The rarity of the event prompted this study which reviews and presents the incidence, histology, diagnosis and therapy of adrenal oncocytic neoplasms. **Materials and Methods:** A review by systematic literature search was done using the MEDLINE®/Cochrane libraries from 1950 to date using the medical subject headings 'oncocytoma', 'adrenal gland', 'adrenal oncocytoma', 'adrenal oncocytic neoplasm' and 'adrenal oncocytic carcinoma'. **Results:** Adrenal oncocytic neoplasm is a rare disease, usually incidentally detected because only 17% are functional adrenal masses. The typical oncocyte displays abundant granular eosinophilic cytoplasm, due to the accumulation of mitochondria. Computed tomography and magnetic resonance imaging are not able to identify or differentiate benign and malignant oncocytic neoplasms. The mainstay of therapy is adrenalectomy, recently performed by laparoscopy. The prognosis is good for benign tumors, while adrenocortical oncocytic carcinoma has a poor survival rate of only 5 years. **Conclusions:** Adrenal oncocytic neo-

plasm, a rare and mostly benign tumor, usually presents as an incidental, large adrenal mass; surgery is the mainstay of therapy, by means of laparoscopy which is now the most diffuse approach to adrenalectomy.

© 2012 S. Karger AG, Basel

Introduction

Oncocytic neoplasms or oncocytomas are in most cases benign tumors, usually arising in the kidneys or thyroid, parathyroid, salivary or pituitary glands [1, 2]; rarely, they have also been reported at other sites including the respiratory tract (as oncocytic neuroendocrine carcinoma [3]), larynx [4] and choroid plexus [5].

Oncocytic neoplasms arising in the adrenal glands are extremely rare, and are usually discovered to be nonfunctional and mostly benign tumors. Since the first description [6] confirmed by electron microscopy in 1986 [7], approximately 147 cases have been reported in the literature, most frequently described as incidental findings. Despite the fact that they have mostly been traditionally considered to be nonfunctional and benign tumors, recent data indicate that about 20% of the adrenocortical oncocytomas demonstrate some elements of malignancy [8] and 10–20% of them appear to affect hormone production in the adrenal glands.

In a decision-making process, a general imaging feature that usually differentiates a benign from a malignant adrenal mass is tumor size: a diameter <4–5 cm usually suggests a benign form. In case of oncocytic neoplasm, however, the size of the mass and imaging findings [computed tomography (CT) or magnetic resonance imaging (MRI)] cannot be used to identify such a lesion or to differentiate benign and malignant oncocytic neoplasms [9]. In such cases, the oncocytic adrenal mass should be considered in the differential diagnosis of indeterminate, incidentally detected, adrenal tumors. As adrenal oncocytic neoplasm usually presented as a large adrenal mass, surgical excision is often considered inevitable, traditionally by open adrenalectomy. Recent advances in laparoscopic techniques, even in the presence of a large adrenal mass, have made possible the application of minimally invasive procedures.

The rarity of the disease prompted this study, which reviews and discusses incidence, histology, diagnosis and current trends in the therapy of adrenal oncocytic neoplasms.

Materials and Methods

Review of the Literature: Search Strategy

A literature search was done using the MEDLINE®/Cochrane libraries from 1950 to date using the medical subject headings 'oncocytoma', 'adrenal gland', 'adrenal oncocytoma', 'adrenal oncocytic neoplasm' and 'adrenal oncocytic carcinoma'. No language restrictions were imposed. Where information was missing from published papers, we contacted authors to obtain relevant information. Original articles, review articles and editorials were included and reviewed in order to select relevant articles.

In August 2012, the search for oncocytoma, adrenal gland, adrenal oncocytoma, adrenal oncocytic neoplasm, adrenal oncocytic carcinoma produced 93 references, 19 of which were reviews.

Results

Incidence

The term 'adrenal mass' refers to neoplasms of the adrenal gland, most of which are identified during an endocrine evaluation for their tendency to overproduce endocrine hormones: adrenal pheochromocytomas (up to 11% of incidentally detected adrenal masses) and all adrenocortical adenomas are benign tumors which may nevertheless cause significant health problems by giving rise to hormonal hyperproduction.

In general, however, most of these adrenal masses are called 'incidentalomas' since they are tumors found by coincidence and in the absence of clinical symptoms: they are one of the more common unexpected findings revealed on ultrasound scan, CT or MRI.

According to the definition, an adrenal incidentaloma is a mass greater than 1 cm in diameter, serendipitously discovered by radiological examination [10]. Numerous autopsy studies have examined the frequency of incidental adrenal nodules, and have shown an overall frequency of adrenal adenomas of about 6%. A review on abdominal CT yields similar findings, with a prevalence of adrenal incidentaloma of 4%, mostly represented by adrenal adenoma (75%) and metastasis in up to 21% of cases.

Malignant adrenal tumors, which include neuroblastoma, adrenocortical carcinoma [11] with its oncocytic variant [12] and a minority of adrenal pheochromocytomas, are extremely rare, with an incidence of 1–2 per million population annually.

Adrenal incidentalomas show different distribution in the population with regard to the age and sex of the patient and the size and nature of the mass and on which side it occurs. Peak incidence is in 50- to 70-year-olds and more frequently found in females (which could be due to a higher rate of abdominal diagnostic procedures being performed in women than in men).

Adrenal oncocytic neoplasm is a more rare disease; to date, it has been described in only 147 cases. Most of them are incidentally detected [13–18], since only 17% are functional adrenal masses [19]. Their occurrence in all ages has been described, without a precise age distribution (mean age at diagnosis 47 years, range 27–72 years), and have been observed to occur more frequently in females (2.5:1) and in the left gland (3.5:1).

In most cases, adrenal oncocytic neoplasm is located in the adrenal cortex, with only 1 case having been described of an oncocytic tumor of the adrenal medulla or in heterotopic adrenal tissue [20, 21]. Adrenocortical oncocytic neoplasm, although extremely rare, should be included in the differential diagnosis of solid, nonfunctioning, adrenal tumors in pregnancy [22].

To date, there are no identified specific risk factors (environmental or genetic), and there is a minimum of knowledge available on the mechanisms that lead to oncocytosis in general and in the adrenal glands in particular. Experimental studies in rats have demonstrated that N-nitrosomorpholine, an airborne contaminant, induces renal oncocytosis and is followed by the formation of renal oncocytoma [23], suggesting that the excessive mitochondrial proliferation is a compensatory mechanism in

the presence of toxic substances. Another hypothesis is that oncocytic neoplasms are tumors of the mitochondria because these have their own DNA that codes their own characteristic proteins [24], and that the tumor arises via mutations in the mitochondrial genome [25]. A peculiar differentiation towards cells of high-energy output or a physiological response to a defect in the energy production machinery of the cell is another possible explanation [26].

Histology

The term 'oncocyte', derived from the Greek root 'onco-', which means mass or bulk and first used by Hamperl in 1950 [27], usually describes a large, highly eosinophilic, granular cell, typically associated with a Hurthle cell tumor of the thyroid gland. It is also known as an oxyphilic cell (typically found in the parathyroid glands) or an Askanazy cell (in the thyroid).

The oncocyte is 1–2 times the size of normal acinar cells which compose original tissue, and typically displays an abundant and granular eosinophilic cytoplasm with a central pyknotic nucleus. The cytoplasmatic granularity is due to the accumulation of mitochondria that may occupy up to 60% of the cytoplasm. The increased concentration of mitochondria is accompanied by a gradual compression and sometimes disappearance of other cytoplasmic membrane systems. Electron microscopy is an invaluable tool for the demonstration of mitochondria in the cytoplasm of oncocytes. The characteristic acidophilia should be distinguished from acidophilia that is secondary to the accumulation of keratin, collagen, lysosomes, neurosecretory granules and cytofilaments, smooth endoplasmic reticulum or a combination of these.

The adrenal oncocytic neoplasms have their own structural characteristics. Macroscopically, most of them are a large, rounded, encapsulated and well-circumscribed mass, with an average diameter of 8 cm (2–20 cm). The mass tends to be brown, yellow or mahogany on cut-section. Some tumors display areas of hemorrhage and necrosis. The classic central radiating scar that has been described in most renal oncocytomas is not always present in adrenocortical oncocytic neoplasms.

The microscopic appearance of oncocytic neoplasm includes cells arranged in solid, trabecular, tubular or papillary patterns. The tumor cells are highly eosinophilic and granular; rarely, the oncocyte has pleomorphic nuclei or a mitotic figure.

Upon observation by electron microscope, the tumor cells contain abundant mitochondria, typical of adrenocortical cells [28].

The immunophenotypic profile of adrenal oncocytic neoplasm [29] is difficult to evaluate because immunohistochemical studies were only performed in approximately half of the reported cases, and no single immunostaining was performed in any of them. Nevertheless, the cases were generally negative for S100 and chromogranin. Bégin [17] and Lin et al. [30] reported immunoreactivity to cytokeratins 8 and 18 (or CAM 5.2), in contrast to the findings of other authors.

Vimentin immunoreactivity was also variable, with most cases being strongly positive, while others showed only weak or absent immunoreactivity. In some cases, through immunocytochemical study, vimentin was diffusely expressed, whereas AE1/AE3 cytokeratin was detected only in some cells.

Some authors used immunopositivity with an antimitochondrial antibody to prove that such a tumor was truly oncocytic [19, 31, 32].

A variant of adrenal oncocytic neoplasm is a disease of adrenal medulla [33]: in such a case, the morphologic distinction between adrenocortical and medullary tumors can be difficult [17]. Sangoi and McKenney [34] characterized the immune profile of adrenal cortical lesions and pheochromocytomas with a panel of antibodies. From the adrenal cortical lesions analyzed, 89% were calretinin-positive, 86% alpha-inhibin-positive and melan-A-positive and 59% were synaptophysin-positive. All the adrenal cortical lesions were chromogranin-negative. Of the pheochromocytomas analyzed, 100% were positive for synaptophysin and chromogranin and all of them were negative for calretinin, inhibin and melan-A. Calretinin has been proven to be sensitive and specific in differentiating tumors of the adrenal cortex from those of the adrenal medulla. Chromogranin was proven to be the sole pheochromocytoma marker, given its high sensitivity and specificity.

In general, the immune profile of an oncocytic tumor is: diffuse positivity for vimentin, melan-A, synaptophysin (fig. 1) and alpha-inhibin [35].

According to the currently used classification, there are three histological categories: pure and benign oncocytoma, oncocytic neoplasm of uncertain malignant potential [36–38] and oncocytic carcinoma [39–42].

A tumor is defined as an adrenocortical carcinoma when three or more of the following criteria are met: (1) a high nuclear grade, (2) a mitotic rate of ≥ 6 per 50 high power fields, (3) atypical mitosis, (4) $<25\%$ clear

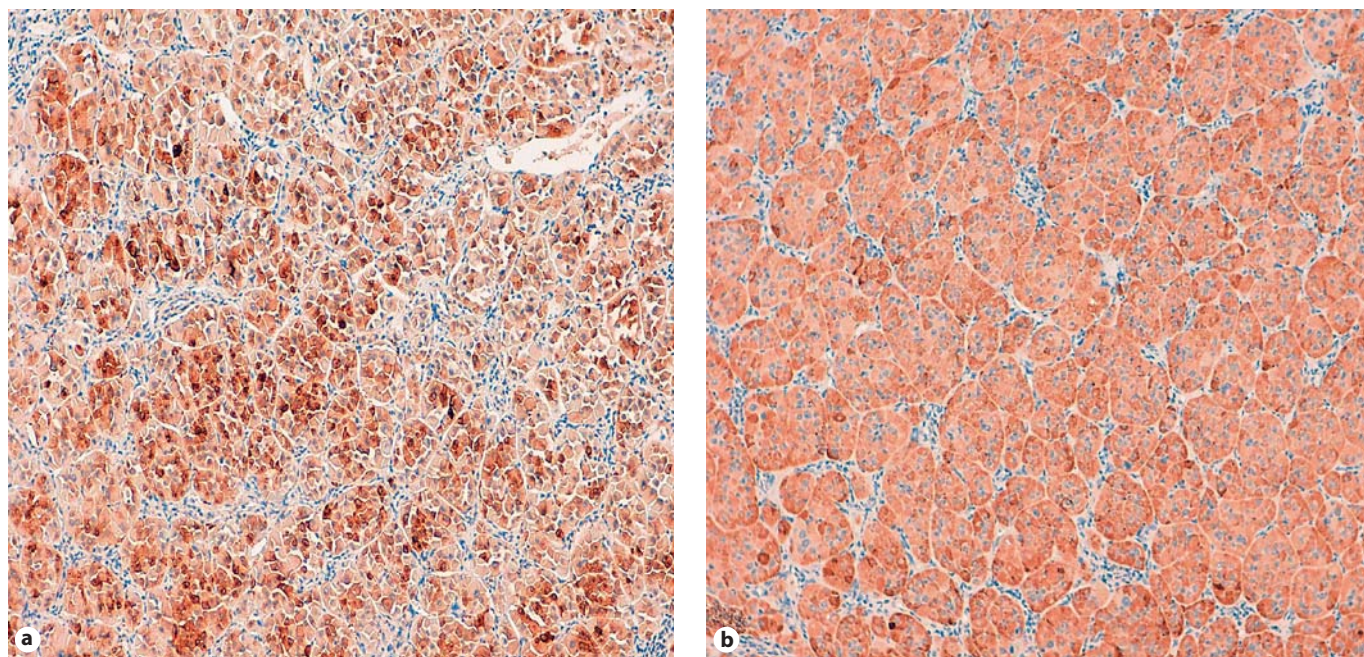


Fig. 1. Immunohistochemical studies showing positive staining for synaptophysin (a) and melan-A (b). $\times 100$. From personal experience: a 36-year-old male, presenting with a large left adrenal oncocytic neoplasm which, upon pathological examination after laparoscopic adrenalectomy, was considered benign according to the Lin-Weiss-Bisceglia criteria.

cells, (5) a diffuse architecture pattern in more than one third of the tumor, (6) confluent necrosis, (7) venous invasion, (8) sinusoidal invasion and (9) capsular invasion. The criteria, also known as Weiss criteria [43], are considered the standard tools for the diagnosis of adrenocortical malignancy. However, great care should be taken in applying these criteria to histological evaluation of the relatively rare and peculiar adrenocortical oncocytic neoplasm. Some other markers, such MIB1 or Ki-67, are of some practical value in terms of achieving a differential diagnosis between benign mass and carcinoma [44].

Bisceglia et al. [8] proposed a review of the common Weiss criteria. The morphologic parameters of the Weiss system were reviewed in the context of their possible application to the oncocytic tumor variant. Proposed major (high mitotic rate, atypical mitoses and venous invasion) and minor (large size and huge weight, necrosis, capsular invasion and sinusoidal invasion) criteria in distinguishing malignant tumors have been analyzed by the authors. Defining criteria (predominantly cells with eosinophilic and granular cytoplasm, a high nuclear grade and a diffuse architectural pattern) in common with all types of oncocytic tumors have been outlined. The presence of

1 major criterion indicating malignancy, 1–4 minor criteria indicating uncertain malignant potential (borderline) and the absence of all major and minor criteria indicative of benign mass.

Diagnosis

The two most important factors in the diagnostic work-up of adrenal mass, also valid for adrenal oncocytic neoplasm, are: the lesion's size and/or function. The size of an adrenal incidentaloma does not affect recommendations regarding biochemical testing.

The size of an adrenal mass is very important in the decision-making process. In a report involving 887 patients who had adrenal incidentalomas, a diameter greater than 4 cm was shown to have a 90% sensitivity for the detection of adrenocortical carcinoma, but a low specificity; only 24% of the lesions were malignant [45]. Decisions regarding surgery should also take into account the imaging phenotype of the mass as well as the patient's age and any coexisting conditions. Increase in size over time is another indication for surgery. In general, however, resection is recommended for all adrenal masses of >6 cm. The size is a problem in adrenal oncocytic neoplasms because most oncocytic adrenal tumors, although benign,

display a large volume [46]. A preoperative percutaneous biopsy [47], by means of CT or ultrasound scan guidance, provides an accurate diagnosis in some cases of indeterminate mass, with a sensitivity of 73.3%.

Careful biochemical analyses should be undertaken to rule out the presence of a primary functioning mass which requires surgical resection despite the size: some cases of adrenal oncocytic neoplasm have presented as functioning tumors. It is extremely rare to find a case of adrenal oncocytic neoplasm with a clinical presentation mimicking pheochromocytoma, a finding which poses a considerable preoperative diagnostic dilemma [48–51], as the pheochromocytoma itself can be confused with the oncocytic neoplasm. The distinction is possible in most cases, based on clinical, biochemical and immunohistochemical study. In rare cases, a Cushing's syndrome is caused by benign adrenocortical oncocytic neoplasm [18, 52–55] or an oncocytic subtype of malignant adrenocortical carcinoma [56].

An adrenocortical oncocytic neoplasm occurring with an aldosteronoma has been described [57, 58] as well as very rare cases of virilizing adrenocortical oncocytic neoplasm in a female child [59–61] or old woman [62], an adrenocortical oncocytic carcinoma producing testosterone [63] or presenting with pseudoprecocious puberty induced by adrenocortical oncocytoma [64] and an adrenal oncocytic neoplasm producing cortisol and testosterone [65] or cortisol and aldosterone [66]. A case of an adrenocortical oncocytic neoplasm producing interleukin (IL)-6 has been reported [67].

In the imaging of oncocytic neoplasms, as of any mass of the adrenal glands, it is important to differentiate the lesion from adrenal adenoma. The majority of malignant and benign adrenal lesions can be differentiated based on fat concentration: almost all malignant lesions are lipid-poor, whereas the majority of benign lesions (usually cortical adenomas) are lipid-rich, and present lower attenuation on CT scan. The CT criterion used for the diagnosis of benign lipid-rich adenoma was unenhanced attenuation of 10 HU or less [68], avoiding measurement of necrotic or cystic areas, which can be seen in some malignant lesions and adrenal cysts [69]. More recently, it has been noted that injected contrast material tends to wash out of benign adrenal lesions faster than malignant ones. However, the CT imaging findings are, unfortunately, in general nonspecific [70–72], and there is no characteristic imaging of adrenal oncocytic neoplasm. The central scar is variably present.

MRI with chemical shift subtraction [73] provides a high confidence level in distinguishing adrenal adeno-

mas from other disease [74, 75]. However, MRI is not able to detect adrenal oncocytic tumor [76]. Moreover, a report of fat within an oncocytic adrenocortical neoplasm demonstrated on CT and MRI has been described. Despite being uncommon, this diagnosis must at least be considered in the presence of a large adrenal mass demonstrating predominantly soft tissue with only scattered areas of fat [77].

In conclusion, CT and MRI findings cannot be used to detect an adrenal oncocytic neoplasm or to differentiate between benign and malignant oncocytic neoplasms.

No typical pattern has been described on ultrasound scan. The use of contrast-enhanced ultrasound has shown an excellent sensitivity and specificity in the differential diagnosis between benign and malignant adrenal mass [78]; however, no experiences of adrenal oncocytic neoplasm has been described.

¹⁸F-FDG whole-body positron emission tomography is utilized to differentiate benign from malignant non-functioning adrenal masses; in the literature there are only a few published reports about findings in adrenocortical oncocytoma by this method [79], and the findings are contradictory [80, 81]. Paradoxical positive results have emerged on the use of radiotracers such as meta-iodobenzylguanidine – labeled with various iodine isotopes, proven to be the most reliable tracer for human studies of adrenal medulla – in adrenal oncocytic neoplasm [82].

The diagnosis of oncocytic neoplasm can be secured preoperatively by fine-needle aspiration cytology [83]; this alone [84, 85], however, and even an open biopsy, would not be able to characterize and define the disease as adrenal oncocytic neoplasm [86].

Therapy

The approach to an adrenal mass depends upon size and function. The surgical management of oncocytic adrenal tumors has been traditionally involving open surgical approach [87, 88]. Adrenalectomy is the standard, since adrenal oncocytic neoplasm usually presented as large adrenal mass. Recent advances in endoscopic techniques have allowed the performance of an increasing number of laparoscopic adrenalectomies [89–92].

Retrospective comparative studies have consistently shown that the laparoscopic approach to an adrenal mass carries less morbidity, quicker patient recovery and shorter hospital stay in comparison with open adrenalectomy. Nevertheless, safe laparoscopic resection of large or potentially malignant adrenal tumors still remains a matter of scientific debate. Safety includes the ability to obtain a

Table 1. Key points of adrenal oncocytic neoplasm with references

	Authors	Year	Type of paper	Number of cases	Key message
Incidence	Kakimoto [6] – de Krijger [11]	1986 – to date	case report, reviews	147	Low incidence, rare disease More than 80% benign or with low malignant potential More frequent in females and in the left gland Usually with large size (mean 8 cm)
Incidentaloma	Angeli [45]	1997	epidemiology		83% incidentally detected
	Lee [13]	2006	epidemiology		
	Young [10]	2007	case report	1	17% functional adrenal mass
Functional mass	Wong [19]	2011	consecutive cases	7	(Cushing, pheochromocytoma, virilizing syndrome)
	Kiriakopoulos [48]	2011	case report	1	
	Li [51]	2000	case report	1	
	Geramizadeh [53]	2008	review	1+	
Risk factors					Unknown
Histology	Seo [28]	2002	case report	2	Abundant mitochondria at electron microscopy
Immunoprofiling	Hoang [29]	2002	consecutive case	4	Positivity for vimentin, melan-A, synaptophysin and
	Schittenhelm [35]	2009	case report	1	alpha-inhibin
	Duregon [25]	2011	consecutive case	27	Reticuline framework, mitochondrial DNA profiling
Criteria (benign/malignant)	Medeiros [43]	1992	review		Weiss criteria
	Bisceglia [8]	2004	consecutive cases	10	Lin-Weiss-Bisceglia criteria
	Lin [30]	1998	consecutive cases	7	
Imaging	Shah [70]	2004	case report	1	No definitive pattern on CT scan or MRI
	Park [72]	2006	consecutive cases	91 (1 oncocytoma)	
	Kekis [76]	2012	case report and review	1	
Surgical therapy	Eldahshan [91]	2008	case report	1	Laparoscopic adrenalectomy if feasible

complete resection without disrupting the capsule. Contra-indications are the presence of capsular or vascular invasion or the diffusion to the surrounding structures, or the presence of a lymphadenopathy.

In general, the laparoscopic approach to adrenal tumors can be safely performed in well-experienced hand, when the preoperative CT and MRI findings reveal a well-encapsulated tumor, with no evidence of invasion into surrounding tissue and no regional adenopathy. More recently, a surgical resection of adrenal oncocytic neoplasm with the assistance of the da Vinci robotic system has been described [93].

Partial adrenalectomy is proposed in some case, however it is an incomplete approach to incidentally detected adrenal mass [94].

Prognosis

Accurate classification of adrenal oncocytic neoplasm is important. The prognosis is based upon the cited criteria for the classification of oncocytic adrenocortical tumors. These criteria (Lin-Weiss-Bisceglia system) include: (1) major criteria (a mitotic rate of more than 5

mitoses per 50 high power fields, any atypical mitoses or venous invasion), (2) minor criteria [large size (>10 cm and/or >200 g), necrosis, capsular invasion or sinusoidal invasion] and (3) definitional criteria (predominantly cells with eosinophilic-granular cytoplasm, high nuclear grade and diffuse architectural pattern). The presence of any one of the major criteria indicates malignancy, the presence of one to four minor criteria is indicative of uncertain potential while the absence of all major and minor criteria indicates benign behavior.

Adrenal oncocytic neoplasms are predominately benign [29]. After surgery, adrenal oncocytic neoplasm can be assessed conservatively in the absence of mitotic activity, necrosis, or invasion. The limited literature available supports this recommendation.

A safer approach, utilized until objective criteria are devised, would be judicious regular follow-up for a minimum of 5 years. On the other side, adrenocortical carcinoma and its oncocytic variant is an aggressive cancer, and often invaded nearby tissues or metastasized [95] to distant organs at the time of diagnosis, with a poor 5-year survival rate (20–35%) [96]. The 5-year survival rate after

successful surgery is 50–60%, but unfortunately, a large percentage of patients are not surgical candidates, and will present local relapse [97]. Radiation therapy and radiofrequency ablation may be used for palliation, while chemotherapy includes mitotane [98] as well as standard cytotoxic drugs.

Discussion and Conclusion

Adrenal oncocytic neoplasm is one of the histological subtypes of incidentally detected adrenal masses. It is usually a large, benign, nonfunctional adrenal tumor, with prevalence in women and on the left side.

As it usually presents as an incidental, large adrenal mass, CT and MRI findings cannot be used to differentiate benign and malignant oncocytic neoplasms and only microscopic criteria are able to identify precise histology characterization and clinical behavior, so adrenalectomy is the mainstay of therapy and laparoscopy is now the most diffuse approach.

It is difficult to trace a guideline with a high level of evidence on adrenal oncocytic neoplasms, since most of the current literature is based upon singular experience, with very few papers reporting on extensive experience, although these are of a high scientific level. In conclusion, table 1 reports the key points with the most important studies as references.

References

- Chang A, Harawi SJ: Oncocytes, oncocytosis, and oncocytic tumors. *Pathol Annu* 1992;27:263–304.
- Tallini G: Oncocytic tumours. *Virchows Arch* 1998;1:5–12.
- Tsuta K, Kalhor N, Raso MG, Wistuba II, Moran CA: Oncocytic neuroendocrine tumors of the lung: histopathologic spectrum and immunohistochemical analysis of 15 cases. *Hum Pathol* 2011;42:578–585.
- Kozakiewicz J, Teodorowicz E, Haczyńska-Partyka A, Myrcik G, Lange D, Szwabowicz M: Adenoma oxyphilicum, an extremely rare case of tumour of the larynx end cancer lungs which are going together. *Otolaryngol Pol* 2007;61:311–314.
- Sav A, Scheithauer BW, Mazzola CA, Ketterling SR, Thompson SJ, Reilly MH: Oncocytic choroid plexus carcinoma: case report. *Clin Neuropathol* 2010;29:14–20.
- Kakimoto S, Yushita Y, Sanefuji T, Kondo A, Fujishima N, Kishikawa M, Matsumoto K: Non-hormonal adrenocortical adenoma with oncocytoma-like appearances. *Hinyokika Kiyo* 1986;32:757–763.
- Smirnova EA, Mikhailov IG: Electron microscopic characteristics of oncocytoma of the lung, small intestine and adrenal gland. *Arkiv Patol* 1986;48:79–81.
- Bisceglia M, Ludovico O, Di Mattia A, Bendor D, Sandbank J, Pasquinelli G, Lau SK, Weiss LM: Adrenocortical oncocytic tumors: report of 10 cases and review of the literature. *Int J Surg Pathol* 2004;12:231–243.
- Shah VN, Premkumar A, Walia R, Kumar S, Nahar U, Bhansali A: Large but benign adrenal mass: adrenal oncocytoma. *Indian J Endocrinol Metab* 2012;16:469–471.
- Young WF Jr: Clinical practice. The incidentally discovered adrenal mass. *N Engl J Med* 2007;356:601–610.
- de Krijger RR, Papathomas TG: Adrenocortical neoplasia: evolving concepts in tumorigenesis with an emphasis on adrenal cortical carcinoma variants. *Virchows Arch* 2012;460:9–18.
- Thway K, Olmos D, Shah C, Flora R, Shipley J, Fisher C: Oncocytic adrenal cortical carcinosarcoma with pleomorphic rhabdomyosarcomatous metastases. *Am J Surg Pathol* 2012;36:470–477.
- Lee R, Al-Ahmadie HA, Boorjian SA, Gonzalez RR, Badillo C, Badillo F, Reuter VE, Steckel J: A case of incidental adrenocortical oncocytoma. *Nat Clin Pract Urol* 2006;3:618–621.
- Vara Castrodeza A, Ablanado Ablanado P, García García J, Martínez Lara C, Díaz A, Calvo Blanco J: Adrenal oncocytoma. *Arch Esp Urol* 1999;52:525–528.
- Kitching PA, Patel V, Harach HR: Adrenocortical oncocytoma. *J Clin Pathol* 1999;52:151–153.
- Macchi C, Rebuffat P, Blandamura S, Piazza M, Macchi V, Fiore D, Nussdorfer GG: Adrenocortical oncocytoma: case report and review of the literature. *Tumori* 1998;84:403–407.
- Bégin LR: Adrenocortical oncocytoma: case report with immunocytochemical and ultrastructural study. *Virchows Arch A Pathol Anat Histopathol* 1992;421:533–537.
- Sasano H, Suzuki T, Sano T, Kameya T, Sasano N, Nagura H: Adrenocortical oncocytoma. A true nonfunctioning adrenocortical tumor. *Am J Surg Pathol* 1991;15:949–956.
- Wong DD, Spagnolo DV, Bisceglia M, Havlat M, McCallum D, Platten MA: Oncocytic adrenocortical neoplasms – a clinicopathologic study of 13 new cases emphasizing the importance of their recognition. *Hum Pathol* 2011;42:489–499.
- Corsi A, Riminucci M, Petrozza V, Collins MT, Natale ME, Cancrini A, Bianco P: Incidentally detected giant oncocytoma arising in retroperitoneal heterotopic adrenal tissue. *Arch Pathol Lab Med* 2002;126:1118–1122.
- Nguyen GK, Vriend R, Ronaghan D, Lakey WH: Heterotopic adrenocortical oncocytoma. A case report with light and electron microscopic studies. *Cancer* 1992;70:2681–2684.
- Segal S, Cytron S, Shenhav S, Gerner O: Adrenocortical oncocytoma in pregnancy. *Obstet Gynecol* 2001;98:916–918.
- Krech R, Zerban H, Bannasch P: Mitochondrial anomalies in renal oncocytes induced in rats by N-nitrosomorpholine. *Eur J Cell Biol* 1981;25:331–339.
- Sun CN, White HV, Thompson BW: Oncocytoma (mitochondrioma) of the parotid gland. *Arch Pathol* 1975;99:208–214.
- Duregon E, Volante M, Cappia S, Cuccurullo A, Bisceglia M, Wong DD, Spagnolo DV, Szpak-Ulczyk S, Bollito E, Daffara F, Berruti A, Terzolo M, Papotti M: Oncocytic adrenocortical tumors: diagnostic algorithm and mitochondrial DNA profile in 27 cases. *Am J Surg Pathol* 2011;35:1882–1893.
- Hartwick RW, Batsakis JG: Non-Warthin's tumor oncocytic lesions. *Ann Otol Rhinol Laryngol* 1990;99:674–677.
- Hamperl H: Oncocytes and the so-called Hurthle cell tumor. *Arch Pathol* 1950;49:563–570.

- 28 Seo IS, Henley JD, Min KW: Peculiar cytoplasmic inclusions in oncocytic adrenal cortical tumors: an electron microscopic observation. *Ultrastruct Pathol* 2002;26:229–235.
- 29 Hoang MP, Ayala AG, Albores-Saavedra J: Oncocytic adrenocortical carcinoma: a morphologic, immunohistochemical and ultrastructural study of four cases. *Mod Pathol* 2002;15:973–978.
- 30 Lin BT, Bonsib SM, Mierau GW, Weiss LM, Medeiros LJ: Oncocytic adrenocortical neoplasms: a report of seven cases and review of the literature. *Am J Surg Pathol* 1998;22:603–614.
- 31 Ohtake H, Kawamura H, Matsuzaki M, Yokoyama E, Kitajima M, Onizuka S, Yamakawa M: Oncocytic adrenocortical carcinoma. *Ann Diagn Pathol* 2010;14:204–208.
- 32 Lázaro Santander R, Andrés Gozalbo C, Cortés Vizcaino V, Vera Román JM: Low-grade oncocytic adrenal carcinoma. *Arch Esp Urol* 2001;54:1123–1126.
- 33 Chisté M, Poppiti RJ, Bianco FJ: Oncocytoma of the adrenal gland medulla. *Ann Diagn Pathol* 2011, E-pub ahead of print.
- 34 Sangoi RS, McKenney JK: A tissue microarray-based comparative analysis of novel and traditional immunohistochemical markers in the distinction between adrenal cortical lesions and pheochromocytoma. *Am J Surg Pathol* 2010;32:423–432.
- 35 Schittenhelm J, Ebner FH, Harter P, Bornemann A: Symptomatic intraspinal oncocytic adrenocortical adenoma. *Endocr Pathol* 2009;20:73–77.
- 36 Gołkowski F, Buziak-Bereza M, Huszno B, Baldys-Waligórska A, Stefańska A, Budzyński A, Okoń K, Chrzan R, Urbanik A: The unique case of adrenocortical malignant and functioning oncocytic tumour. *Exp Clin Endocrinol Diabetes* 2007;115:401–404.
- 37 Botsios D, Blouhos K, Vasiliadis K, Asimaki A, Tsalis K, Betsis D: Adrenocortical oncocytoma – a rare tumor of undefined malignant potential: report of a case. *Surg Today* 2007;37:612–617.
- 38 Lázaro Santander R, Andrés Gozalbo C, Cortés Vizcaino V, Vera Román JM: Low-grade oncocytic adrenal carcinoma. *Arch Esp Urol* 2001;54:1123–1126.
- 39 el-Naggar AK, Evans DB, Mackay B: Oncocytic adrenal cortical carcinoma. *Ultrastruct Pathol* 1991;15:549–556.
- 40 Argyriou P, Zisis C, Alevizopoulos N, Kefaloyannis EM, Gennatas C, Petraki CD: Adrenocortical oncocytic carcinoma with recurrent metastases: a case report and review of the literature. *World J Surg Oncol* 2008;6:134–139.
- 41 Juliano JJ, Cody RL, Suh JH: Metastatic adrenocortical oncocytoma: a case report. *Urol Oncol* 2008;26:198–201.
- 42 Song SY, Park S, Kim SR, Suh YL: Oncocytic adrenocortical carcinomas: a pathological and immunohistochemical study of four cases in comparison with conventional adrenocortical carcinomas. *Pathol Int* 2004;54:603–610.
- 43 Medeiros LJ, Weiss LM: New developments in the pathologic diagnosis of adrenal cortical neoplasms. A review. *Am J Clin Pathol* 1992;97:73–83.
- 44 Sasano H, Suzuki T, Moriya T: Recent advances in histopathology and immunohistochemistry of adrenocortical carcinoma. *Endocr Pathol* 2006;17:345–354.
- 45 Angeli A, Osella G, Ali A, Terzolo M: Adrenal incidentaloma: an overview of clinical and epidemiological data from the National Italian Study Group. *Horm Res* 1997;47:279–283.
- 46 Reyna-Villamil E, Santos-Bolívar J, Prieto-Montañó J: Adrenal oncocytoma. *Cir Esp* 2011;89:692–693.
- 47 Osman Y, El-Mekresh M, Gomha AM, Mohsen T, Taha N, Hussein N, Eraky I: Percutaneous adrenal biopsy for indeterminate adrenal lesion: complications and diagnostic accuracy. *Urol Int* 2010;84:315–318.
- 48 Kiriakopoulos A, Papaioannou D, Linos D: Adrenal cortical oncocytoma mimicking pheochromocytoma. *Hormones (Athens)* 2011;10:76–79.
- 49 Sharma N, Dogra PN, Mathur S: Functional adrenal oncocytoma: a rare neoplasm. *Indian J Pathol Microbiol* 2008;51:531–533.
- 50 Goel T, Thomas J, Garg S, Rao AC, Reddy S: Adrenal oncocytoma masquerading as a functional tumor. *Indian J Urol* 2007;23:77–78.
- 51 Li M, Wenig BM: Adrenal oncocytic pheochromocytoma. *Am J Surg Pathol* 2000;24:1552–1557.
- 52 Lee SS, Baek KH, Lee YS, Lee JM, Kang MI, Cha BY, Lee KW, Son HY, Kang SK: Subclinical Cushing's syndrome associated with an adrenocortical oncocytoma. *J Endocrinol Invest* 2008;31:675–679.
- 53 Geramizadeh B, Norouzzadeh B, Bolandparvaz S, Sefidbakht S: Functioning adrenocortical oncocytoma: a case report and review of literature. *Indian J Pathol Microbiol* 2008;51:237–239.
- 54 Xiao GQ, Pertsemlidis DS, Unger PD: Functioning adrenocortical oncocytoma: a case report and review of the literature. *Ann Diagn Pathol* 2005;9:295–297.
- 55 Kabayegit OY, Soysal D, Oruk G, Ustaoglu B, Kosan U, Solmaz S, Avci A: Adrenocortical oncocytic neoplasm presenting with Cushing's syndrome: a case report. *J Med Case Rep* 2008;2:228.
- 56 Alexander A, Paulose KP: Oncocytic variant of adrenal carcinoma presenting as Cushing's syndrome. *J Assoc Physicians India* 1998;46:235–237.
- 57 Terui K, Sakihara S, Kageyama K, Nigawara T, Takayasu S, Matsuhashi Y, Kon A, Yamamoto H, Ohyama C, Sasano H, Suda T: A case of adrenocortical oncocytoma occurring with aldosteronoma. *J Clin Endocrinol Metab* 2010;95:3597–3598.
- 58 Mete O, Asa SL: Aldosterone-producing adrenal cortical adenoma with oncocytic change and cytoplasmic eosinophilic globular inclusions. *Endocr Pathol* 2009;20:182–185.
- 59 Lim YJ, Lee SM, Shin JH, Koh HC, Lee YH: Virilizing adrenocortical oncocytoma in a child: a case report. *J Korean Med Sci* 2010;25:1077–1079.
- 60 Gumy-Pause F, Bongiovanni M, Wildhaber B, Jenkins JJ, Chardot C, Ozsahin H: Adrenocortical oncocytoma in a child. *Pediatr Blood Cancer* 2008;50:718–721.
- 61 Ciprová V, Povýsil C, Dudorkinová D, Safarik L, Zelinka T: Oncocytic adrenocortical neoplasms. *Cesk Patol* 2004;40:102–105.
- 62 Erlanson RA, Reuter VE: Oncocytic adrenal cortical adenoma. *Ultrastruct Pathol* 1991;15:539–547.
- 63 Mwandila M, Waller H, Stott V, Mercer P: A case of a testosterone-secreting oncocytic adrenocortical carcinoma. *N Z Med J* 2010;123:80–82.
- 64 Tahar GT, Nejib KN, Sadok SS, Rachid LM: Adrenocortical oncocytoma: a case report and review of literature. *J Pediatr Surg* 2008;43:E1–E3.
- 65 Logasundaram R, Parkinson C, Donaldson P, Coode PE: Co-secretion of testosterone and cortisol by a functional adrenocortical oncocytoma. *Histopathology* 2007;51:418–420.
- 66 Ali AE, Raphael SJ: Functional oncocytic adrenocortical carcinoma. *Endocr Pathol* 2007;18:187–189.
- 67 Akatsu T, Kameyama K, Araki K, Ashizawa T, Wakabayashi G, Kitajima M: Functioning adrenocortical oncocytoma: the first documented case producing interleukin-6 and review of the literature. *J Endocrinol Invest* 2008;31:68–73.
- 68 Tirkes T, Gokaslan T, McCrea J, Sandrasegaran K, Hollar MA, Akisik F, Lall C: Oncocytic neoplasms of the adrenal gland. *AJR Am J Roentgenol* 2011;196:592–596.
- 69 Boland GWL: Adrenal imaging. *Abdom Imaging* 2011;36:472–482.
- 70 Shah RK, Oto A, Ozkan OS, Ernst RD, Hernandez JA, Chaudhary HB, Koroglu M: Adrenal oncocytoma: US and CT findings. *JBR-BTR* 2004;87:180–182.
- 71 Poretti D, Mazzarol G, Bonomo G, Casadio C, Bellomi M: Adrenocortical oncocytoma: case report. *Clin Imaging* 2003;27:426–430.
- 72 Park BK, Kim B, Ko K, Jeong SY, Kwon GY: Adrenal masses falsely diagnosed as adenomas on unenhanced and delayed contrast-enhanced computed tomography: pathological correlation. *Eur Radiol* 2006;16:642–647.

- 73 Haider MA, Ghai S, Jhaveri K, Lockwood G: Chemical shift MR imaging of hyperattenuating (>10 HU) adrenal masses: does it still have a role? *Radiology* 2004;231:711–716.
- 74 Savci G, Yazici Z, Sahin N, Akgöz S, Tuncel E: Value of chemical shift subtraction MRI in characterization of adrenal masses. *AJR Am J Roentgenol* 2006;186:130–135.
- 75 Monk IP, Lahiri R, Sivaprakasam R, Malhotra S, Praseedom RK, Jah A: Adrenocortical oncocytoma: review of imaging and histopathological implications. *Int J Surg Case Rep* 2010;1:30–32.
- 76 Kekis P, Seretis C, Lagoudianakis E, Gemezetzis G, Koronakis N, Keramidaris D, Manouras I, Manouras A: Laparoscopic approach to a large adrenocortical oncocytoma: a case report and review of the literature. *Int J Surg Case Rep* 2012;3:279–282.
- 77 Rosenkrantz AB, Do RK, Hajdu CH: Imaging appearance of bulk fat within an oncocyctic adrenocortical neoplasm, a rare and potentially malignant tumour. *Br J Radiol* 2010;83:204–207.
- 78 Friedrich-Rust M, Glasemann T, Polta A, Eichler K, Holzer K, Kriener S, Herrmann E, Nierhoff J, Bon D, Bechstein WO, Vogl T, Zeuzem S, Bojunga J: Differentiation between benign and malignant adrenal mass using contrast-enhanced ultrasound. *Ultraschall Med* 2011;32:460–471.
- 79 Kim DJ, Chung JJ, Ryu YH, Hong SW, Yu JS, Kim JH: Adrenocortical oncocytoma displaying intense activity on 18F-FDG-PET: a case report and a literature review. *Ann Nucl Med* 2008;22:821–824.
- 80 Acar C, Akkas BE, Sen I, Sozen S, Kitapci MT: False positive 18F-FDG PET scan in adrenal oncocytoma. *Urol Int* 2008;80:444–447.
- 81 Minamimoto R, Yamanaka S, Kawamoto M, Endoh M, Nishito R, Yoshida K, Nakaigawa N, Yao M, Kubota Y, Inoue T: High FDG uptake on oncocytoma located in the retroperitoneum mimicking malignancy. *Clin Nucl Med* 2007;32:582–583.
- 82 Padberg BC, Rordorf T, Suter SL, Pfeiffer D, Wild D, Schröder S: 123I-Metaiodobenzylguanidine (MIBG) scintigraphy: paradoxical positivity in an oncocyctic adrenocortical carcinoma. *Pathologie* 2007;28:281–284.
- 83 Krishnamurthy S, Ordonez NG, Shelton TO, Ayala AG, Sneige N: Fine-needle aspiration cytology of a case of oncocyctic adrenocortical carcinoma. *Diagn Cytopathol* 2000;22:299–303.
- 84 Cham E, Watkin W, Goldschmidt R, Liu L: Fine needle aspiration cytology of adrenocortical oncocyctic neoplasm: a case report. *Acta Cytol* 2010;54:627–634.
- 85 Wragg T, Nguyen GK: Cytopathology of adrenal cortical oncocytoma. *Diagn Cytopathol* 2001;24:222–223.
- 86 Lee CK, Choi KH, Cha YJ, Bum JH, Lee HH, Kim MS, Park WK, Yang SC, Han WK: Large oncocyctic adrenocortical tumor with uncertain malignant potential. *Korean J Urol* 2011;52:650–652.
- 87 Farah-Klibi F, Ben Slama S, Ferchichi L, Ben Temime L, Ben Jilani S, Zermani R: Adrenal gland oncocytoma. *Tunis Med* 2011;89:309–310.
- 88 Bouasker I, Zoghalmi A, Farah Klibi F, Smaali I, El Ouair MA, Zermani R, Dziri C: Adreno-cortical oncocytoma: a case report. *Tunis Med* 2010;88:353–356.
- 89 Pazooki A, Vaziri M: Incidental adrenocortical oncocytoma. *BMJ Case Rep* DOI: 10.1136/bcr.12.2008.1405.
- 90 Tian XJ, Huang Y, Lu J, Ma LL: Laparoscopic adrenocortical oncocytoma resection. *Chin Med J* 2008;121:862–864.
- 91 Eldahshan S, Celia A, Zeccolini G, Guerini A, Breda G: Laparoscopic transperitoneal adrenalectomy for adrenocortical oncocytoma. *Arch Ital Urol Androl* 2008;80:82–84.
- 92 Farkas A, Horányi J, Gláz E, Kulka J: Oncocytic tumor of the adrenal gland. *Orv Hetil* 2005;146:1453–1458.
- 93 Young JA, Chapman WH 3rd, Kim VB, Albrecht RJ, Ng PC, Nifong LW, Chitwood WR Jr: Robotic-assisted adrenalectomy for adrenal incidentaloma: case and review of the technique. *Surg Laparosc Endosc Percutan Tech* 2002;12:126–130.
- 94 Modi P, Goel R, Kadam G: Retroperitoneoscopic partial adrenalectomy for large adrenocortical oncocytoma. *J Endourol* 2007;21:419–422.
- 95 Thway K, Olmos D, Shah C, Flora R, Shipley J, Fisher C: Oncocytic adrenal cortical carcinosarcoma with pleomorphic rhabdomyosarcomatous metastases. *Am J Surg Pathol* 2012;36:470–477.
- 96 Allolio B, Fassnacht M: Clinical review: adrenocortical carcinoma. *J Clin Endocrinol Metab* 2006;91:2027–2037.
- 97 Kurek R, Von Knobloch R, Feek U, Heidenreich A, Hofmann R: Local recurrence of an oncocyctic adrenocortical carcinoma with ovary metastasis. *J Urol* 2001;166:985.
- 98 Terzolo M, Angeli A, Fassnacht M: Adjuvant mitotane treatment for adrenocortical carcinoma. *N Engl J Med* 2007;356:2372–2380.