

E. Sánchez-de-Badajoz

J. Ramos

R. Burgos

Service of Urology, Carlos Haya Hospital  
and Department of Surgery,  
School of Medicine, Malaga, Spain

# Ureteral Triplication with Contralateral Ureter Duplication

.....  
**Key Words**

Ureter

Triplication

.....  
**Abstract**

A rare case of ureteral triplication with contralateral duplication is reported. The incidence, embryology, classification and symptomatology are commented. The most relevant literature is reviewed.  
.....

**Introduction**

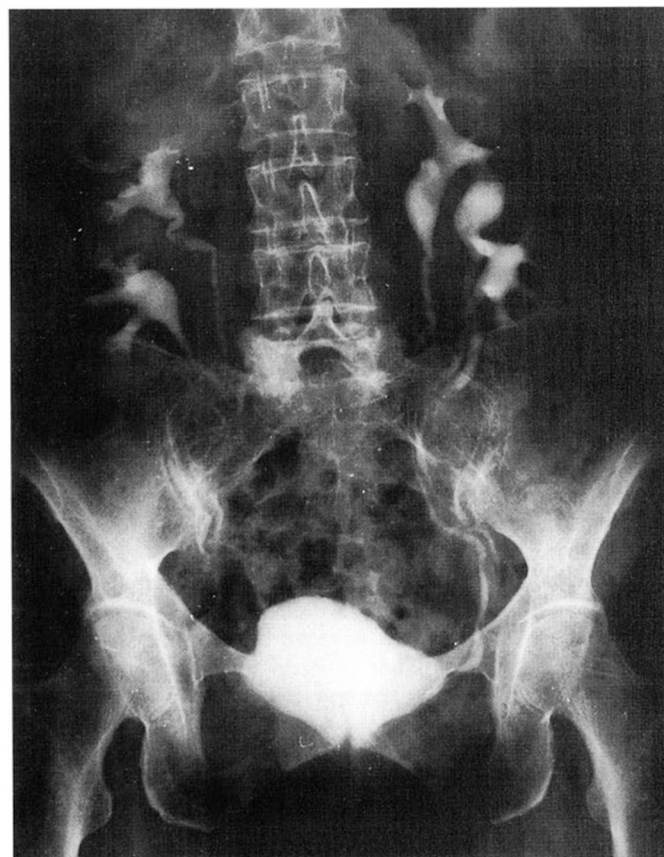
Ureteral triplication is one of the rarest anomalies of the upper urinary tract, often associated with other inborn defects, with less than 100 cases published up to date.

Ureteral embryological development starts normally between the 4th and 5th weeks as a protrusion from the distal part of the wolffian duct. The protrusion extends dorsally at first and later cranially until in the 6th week it makes contact with the metanephros. It appears that multiple ureters are secondary to the formation of more than one ureteral protrusion or by anomalous division of a single protrusion.

Smith [1] recognized four types of ureteral triplication: (1) triple ureters completely separated, (2) triple ureters, two biconfluent, (3) triple ureters all confluent, and (4) double ureter, one bifurcated.

**Case Report**

A 62-year-old female presented with severe pain in the right renal fossa that radiated to the hypogastrium, accompanied by vomiting and discomfort on micturition. Her clinical history was unremarkable. Physical examination was normal, but the urinary sediment revealed microhaematuria. Intravenous urography displayed triplication of the left renal pelvis and ureter, and duplication of the corresponding structures on the right (type 1 of the Smith classification); there was no lithiasis or dilatation of the urinary tract (fig. 1).



**Fig. 1.** Intravenous pyelogram showing ureteral triplication on the left side and duplication on the right.

Cystoscopy revealed three ureteral meatus on the left and two on the right and no other anomalies. A few days later, the patient was asymptomatic.

### Comment

Ureteral triplication is a very rare condition found slightly more often in females and is usually associated with other congenital anomalies and occasionally with polymalformation syndromes [2]. The symptoms are

usually varied and unspecific, most commonly lumbar pain, discomfort on micturition and fever. Very often the diagnosis is fortuitous, made during a urological or another type of exploration. This perhaps explains the wide range of age of 1–74 years at presentation in the literature [3, 4]. Occasionally, as in the present case, intravenous urography is sufficient for a correct diagnosis, but an ectopic ureter or renal segmental dysplasias can make diagnosis difficult and cystography, cystoscopy, a retrograde pyelogram or computerized tomography may be required.

---

### References

- 1 Colomb J, Ehrlich R: Bilateral ureteral triplication with crossed ectopic fused kidneys associated with the Vacterl syndrome. *J Urol* 1988; 141:1398–1399.
- 2 Sánchez de Badajoz E: Triplicación ureteral y duplicación de vejiga. *Arch Esp Urol* 1982;135: 139–142.
- 3 Verdú F, Moncada I, Díez Cordero J, Herranz F, Pardo E: Triplicidad ureteral. *Actas Urol Esp* 1990;14:452–454.
- 4 Prantl M, Tewes G: Ureter triplex mit kontralateralem Ureter fissus. *Z Kinderchir* 1988;43: 350–352.