

Chronic Lymphatic Leukemia Diagnosed through Histological Evaluation of Resected Prostatic Tissue

Anne Marie Worning, Jens Dragsted

Department of Pathology and Urological Department, Gentofte Hospital, Hellerup, Denmark

Key Words. Leukemic infiltration · Prostatic tissue

Abstract. Chronic lymphatic leukemia was diagnosed through routine histological evaluation of resected prostatic tissue. Two cases are presented.

Chronic lymphatic leukemia (CLL), primarily diagnosed by histological evaluation of prostatic tissue, has only been sporadically described [1]. However, leukemic infiltration of the prostate gland is often found in patients with verified leukemia [1–6]. In autopsy material from leukemic patients, up to 50% have leukemic infiltration in the prostate.

In the following two cases of aleukemic CLL are described. The diagnosis in both cases is primarily found by histological evaluation of resected prostatic tissue.

Case Histories

Case 1

6 months prior to admission, a 67-year-old male patient had laminectomy of L III performed on account of prolapsed intervertebral disc. Postoperatively the patient developed urinary retention due to bladder denervation and was initially treated with a catheter. After urodynamic investigation transurethral resection was performed and 6 g of macroscopically normal tissue was removed. The postoperative period was without complications and the patient was discharged with complete bladder control and no residue.

Hemoglobin, sedimentation rate and leucocyte count were all normal. The histological evaluation showed mainly stromal hyperplasia and a massive infiltration of lymphocytes which gave rise to the suspicion of underlying CLL. The diagnosis of CLL was confirmed by bone marrow investigation.

Case 2

A 66-year-old male presented with obstructive urinary symptoms due to prostatic enlargement. A transurethral resection was performed and 32 g of macroscopically normal tissue was removed. The postoperative period was without complications. The patient was discharged with complete bladder control. Hemoglobin, sedimentation rate and leucocyte count were all normal. Histological evaluation showed glandular hyperplasia with diffuse infiltration of mature lymphocytes. This picture indicates possible CLL, which was verified by bone marrow investigation.

Discussion

The literature reveals only a few cases in which the diagnosis of leukemia is primarily found after prostatectomy. In the described cases there was no suspicion of a leukemic condition at the time of prostatic resection. The diagnosis was made by the histological evaluation of resected prostatic tissue and verified by bone marrow investigation. The described cases are thus aleukemic.

Patients with verified leukemia can experience acute urinary retention due to growth of leukemic infiltrations [2]. However, more often the obstructive symptoms in these patients are caused by benign hyperplasia and the described leukemic infiltrations are a secondary feature and not considered the cause of obstruction. In the

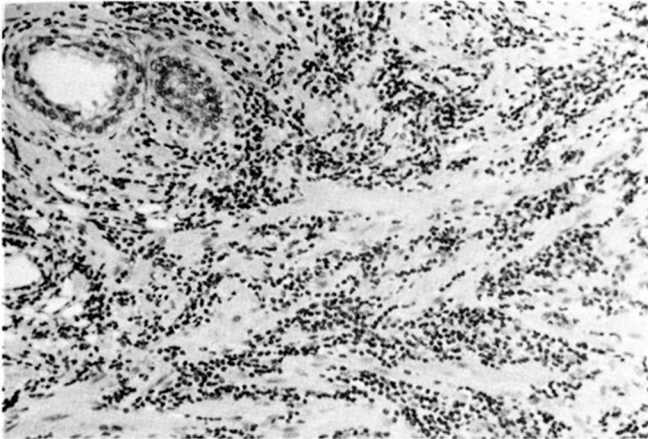


Fig. 1. Prostatic tissue with diffuse infiltration of lymphocytes. $\times 240$.

described cases the prostate was of normal appearance and preoperatively there was no excess bleeding.

CLL is a disease of old age with a peak incidence around 60 years of age and a male to female ratio of about 2:1. Thus patients with CLL and coexisting urinary obstructive symptoms will be encountered at most urological departments. It remains clear that this type of patient is best treated by transurethral or transvesical prostatectomy by the normal procedure, as the postoperative result is similar to patients with benign hyperplasia [6].

How extensive leukemic infiltration has to be to cause or precipitate the symptoms is unknown [7]. With other more rare and more aggressive types of leukemia one can experience profuse hemorrhage which, in the case of monocytic leukemia, can be fatal. This group of patients must, therefore, be considered more carefully before urological surgery [4].

In view of the satisfactory surgical results for patients with CLL and obstructive urinary symptoms, there seems

little need for other treatment alternatives. However, a patient with acute myelomonocytic leukemia was successfully relieved of his prostatic symptoms by low-dose radiotherapy. Subsequent postmortem pathology did not demonstrate leukemic infiltration or benign hyperplasia [2].

The two presented cases are interesting because CLL was not previously diagnosed but discovered through routine histological evaluation of the resected prostatic tissue.

References

- 1 Waddington, R.T.: Leukaemic infiltration of the prostate in a patient with chronic lymphatic leukaemia – a case report. *Br. J. Urol.* 45: 184–186 (1973).
- 2 Mitch, W.E.; Serpick, A.A.: Leukemic infiltration of the prostate: a reversible form of urinary obstruction. *Cancer* 26: 1361–1365 (1970).
- 3 Dajani, Y.F.; Burke, M.: Leukemic infiltration of the prostate: a case study and clinicopathological review. *Cancer* 38: 2442–2446 (1976).
- 4 Girgis, A.S.; Bergman, H.: Prostatectomy in leukemic patients. *J. Urol.* 110: 333–335 (1973).
- 5 Blank, B.; Hodges, C.V.: Leukemic infiltration of the prostate: a case report. *J. Urol.* 123: 789–790 (1980).
- 6 Butlet, M.R.; O'Flynn, J.D.: Prostatic disease in the leukemic patient with particular reference to leukemic infiltration in the prostate – a retrospective clinical study. *Br. J. Urol.* 45: 179–183 (1973).
- 7 Lewi, H.J.E.; White, A.; Cassidy, M.; McCallum, H.M.; Spilg, W.G.S.; Scott, R.; Hutchison, A.G.: Lymphocytic infiltration of the prostate. *Br. J. Urol.* 56: 301–303 (1984).

Received: October 30, 1984

Accepted: January 9, 1985

Anne Marie Worning, MD,
Department of Pathology,
Gentofte Hospital,
DK-2900 Hellerup (Denmark)