

Trachyonychia and Twenty-Nail Dystrophy: A Comprehensive Review and Discussion of Diagnostic Accuracy

Audrey A. Jacobsen^a Antonella Tosti^b

^aUniversity of Miami Miller School of Medicine, and ^bDepartment of Dermatology and Cutaneous Surgery, University of Miami Miller School of Medicine, Miami, Fla., USA

Key Words

Trachyonychia · Twenty-nail dystrophy · Sandpaper nails

Abstract

Background/Aims: The term trachyonychia, also known as twenty-nail dystrophy, is used to describe thin, brittle nails with excessive longitudinal ridging. The term twenty-nail dystrophy has been incorrectly applied to other conditions that can affect all twenty nails. Therefore, we have conducted a comprehensive review of the clinical features of trachyonychia and have included a discussion regarding the diagnostic accuracy of this condition in the literature. **Methods:** In November and December 2015, we conducted a thorough literature search using the following search terms: 'trachyonychia', 'twenty nail dystrophy', and 'sandpaper nails'. Articles that reported the epidemiology, disease associations, clinical presentation, histopathology, and treatment options for trachyonychia were included. Particular attention was given to case reports to identify misdiagnosed cases of twenty-nail dystrophy. **Results:** Our preliminary search yielded 184 results with 72 unique articles ultimately selected for review. Excluded articles included 27 articles in languages other than English, 18 commentaries or reviews, and 67 irrelevant articles. Twelve additional articles described

nail abnormalities clinically different from trachyonychia. **Conclusion:** Many other conditions can cause widespread nail dystrophy. The specific characteristics of trachyonychia need to be considered to make the diagnosis of twenty-nail dystrophy.

© 2016 S. Karger AG, Basel

Introduction

Trachyonychia is also known as twenty-nail dystrophy and describes rough, sandpapered nails that are brittle and thin. Alkiewicz [1] first used the term trachyonychia in 1950, but the condition was later identified as twenty-nail dystrophy by Hazelrigg et al. [2] in 1977. However, the term twenty-nail dystrophy is misleading as in trachyonychia any number of nails can be affected and on the other hand widespread nail dystrophy is often incorrectly diagnosed as twenty-nail dystrophy even when the clinical signs of trachyonychia are not evident. It is for this reason that we have conducted a comprehensive review of the clinical features of trachyonychia in addition to a discussion regarding diagnostic accuracy of this condition.

Table 1. Cases with nail changes that do not correspond morphologically to trachyonychia

Article	First author	Year	Comments
Coexistence of psoriasis and alopecia areata with trachyonychia in a pediatric patient with Turner syndrome	Dogruk-Kacar [51]	2014	Thickened nails
Elkonyxis in association with washboard nails and twenty-nail dystrophy	Lee [53]	2014	Horizontal ridging
Hereditary punctate palmoplantar keratoderma (Brauer-Buschke-Fischer syndrome)	Gupta [49]	2004	Onychoschizia and subungual hyperkeratosis
Ichthyosis follicularis with congenital atrichia, nail dystrophy, and palmoplantar keratoderma. Variant of ichthyosis follicularis, alopecia, and photophobia syndrome or a new entity?	Rai [52]	2005	Nail thickening and onycholysis
Rapp-Hodgkin syndrome	Kim [50]	2004	Thinning, longitudinal ridging, but distal onycholysis and pterygium
Syndrome in question. Hay-Wells syndrome	Tonolli [48]	2014	Micronychia (fingernails) and subungual hyperkeratosis (toenails)
Systemic amyloidosis presenting with glans penis involvement	Fernandez-Flores [5]	2014	Transverse proximal leukonychia and onychorrhexis
Topical 5-fluorouracil treatment for psoriatic trachyonychia	Schissel [35]	1998	Patient demonstrates typical psoriatic nails not trachyonychia
Trachyonychia as the presenting sign of myeloma-associated amyloidosis	Shim [58]	2016	Onychorrhexis and onycholysis
Trachyonychia, cutis laxa, and easy bruising of the skin. Amyloidosis	Que [23]	2014	Onychorrhexis and partial destruction of the nail plate
Twenty-nail dystrophy (trachyonychia) caused by lichen planus in a patient with gold allergy	Yokozeki [54]	2005	Onychorrhexis typical of lichen planus
Twenty-nail dystrophy treated with topical psolaren UVA	Halkier-Sorensen [41]	1990	Patient demonstrates typical psoriatic nails not trachyonychia

Methods

We conducted a thorough search of PubMed, Cochrane Central Register of Controlled Trials (CENTRAL), clinicaltrials.gov, and Embase. The search was performed in November and December 2015 using the following search terms: 'trachyonychia', 'twenty nail dystrophy', and 'sandpaper nails'. Inclusion criteria required articles to report or investigate the epidemiology, disease associations, clinical presentation, histopathology, and treatment options for trachyonychia. Clinical trials, case series, and case reports were included. Reviews were excluded but accessed as a reference for the topic. Articles published in a language other than English were excluded. Titles and abstracts were reviewed for relevance; full-text review was conducted in the event of inconclusive titles and abstracts. References of selected articles were also screened for completeness. Case reports suggesting novel disease associations were reviewed in full text, with particular attention to clinical photographs to verify if the nail abnormalities were consistent with a diagnosis of trachyonychia.

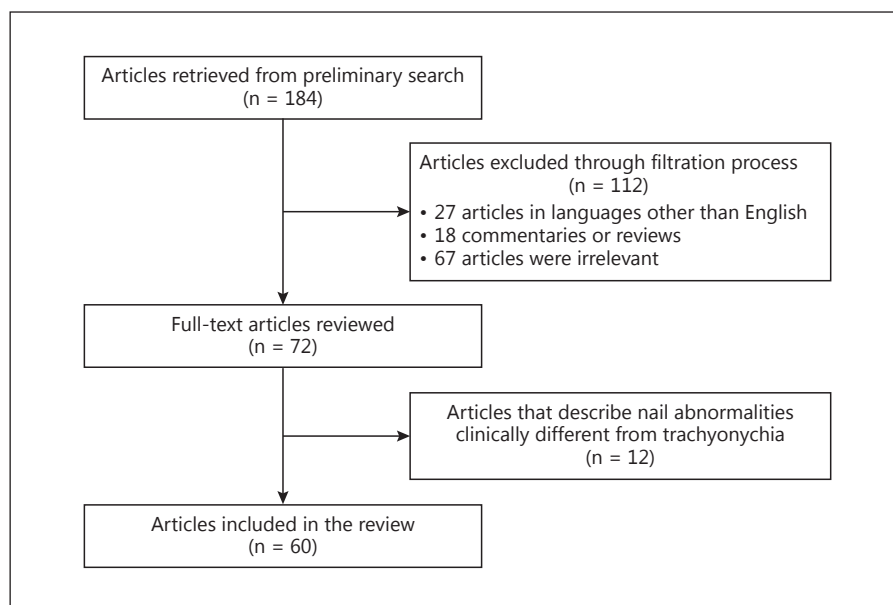
Results

The preliminary search yielded 184 results. A total of 72 unique articles were initially identified for inclusion in our review. Of the remaining 112 articles, 27 were in languages other than English, 18 were commentaries or reviews, and 67 were deemed irrelevant. Of the 72 articles identified for inclusion, 12 articles were considered to report nail abnormalities that were different from trachyonychia (table 1). Figure 1 depicts the article selection process in detail.

Epidemiology

Trachyonychia follows an insidious disease course and is most common in the pediatric population [2]. In children, all twenty nails are usually affected and trachyo-

Fig. 1. Article selection process. A total of 184 articles were identified using the following search terms: ‘trachyonychia’, ‘twenty-nail dystrophy’, and ‘sandpaper nails’. Of the 72 articles identified for inclusion, we identified 12 articles with a wrong diagnosis of trachyonychia.



nychia is more commonly idiopathic. The most common associated disease is alopecia areata where trachyonychia is estimated to affect 3.65% of patients [3]. The prevalence of idiopathic trachyonychia is not known [4].

A number of other cutaneous and systemic diseases have been associated with trachyonychia including the following: amyloidosis [5], atopic dermatitis [6], treatment with chemotherapeutic agents [7, 8], hematologic abnormalities (i.e. idiopathic thrombocytopenia) [9], ichthyosis vulgaris [10, 11], immune dysregulation polyendocrinopathy enteropathy X-linked syndrome (IPEX) [12], immunoglobulin A deficiency [13], incontinentia pigmenti (Bloch-Sulzberger syndrome) [14], pemphigus vulgaris [15], primary biliary cirrhosis [16], reflex sympathetic dystrophy [17], and sarcoidosis [18, 19]. However, for some of these cases, the clinical pictures show nail abnormalities that are different from trachyonychia (table 1). Vitiligo has also been associated with trachyonychia [20–22], but this probably reflects the fact that trachyonychia is commonly associated with alopecia areata.

We believe that it is important for clinicians to make the diagnosis of trachyonychia carefully, especially when it is thought to be concomitant with one of the above-listed disease associations. For example, although trachyonychia has been associated with amyloidosis, the pictures illustrating the case reports with this association show lichen planus-like changes with severe onychorhexis but not trachyonychia [5, 23].

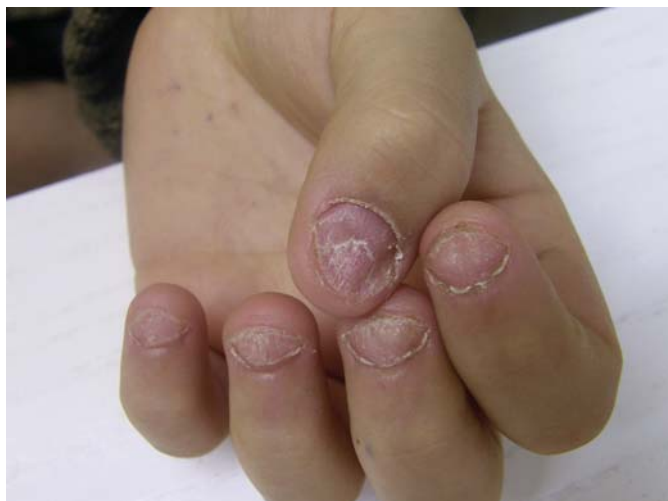Table 2. Clinical features of trachyonychia

Opaque variety	More severe variety; nails are brittle, thin, and rough with excessive longitudinal ridging due to fine superficial striations found in a parallel pattern
Shiny variety	Nails retain their luster, presenting with superficial ridging and multiple small geometric pits
Both varieties	Superficial scaling of the nail plate and hyperkeratosis of the cuticles; koilonychia, onychoschizia

Lichen planus and psoriasis can also cause trachyonychia [24], and in a retrospective study of 15 children with nail lichen planus, 2 exhibited trachyonychia [25].

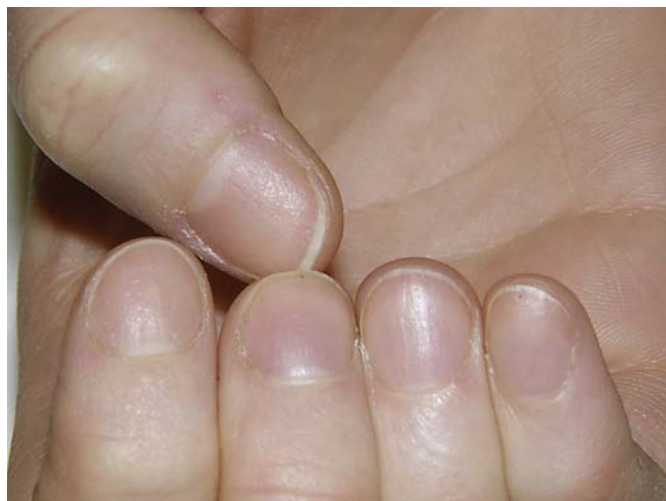Clinical Presentation and Histopathology

To aid the clinician in making an accurate diagnosis of trachyonychia, we will describe the clinical presentation in detail. First, we want to emphasize again that any number of nails can be affected. The degree of severity can also vary from nail to nail [4]. Two clinical varieties, opaque and shiny, have been described by Baran et al. [26], where the opaque form represents a more severe condition. Table 2 describes these two varieties. In both forms, fingernails are affected more often than toenails and koilonychia is common.



Color version available online

Fig. 2. Trachyonychia: nails are thin and rough due to excessive longitudinal ridging. Severity varies in different nails. Also, note the mild koilonychia, onychoschizia in the thumb, and ragged hyperkeratotic cuticles.



Color version available online

Fig. 3. Trachyonychia: shiny variety. Note the multiple pits arranged to form longitudinal ridges.

Table 3. Differential diagnosis of trachyonychia

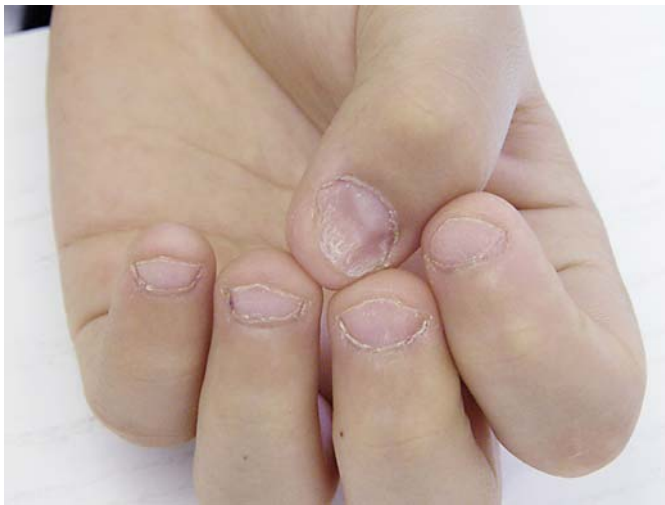Condition	Distinguishing features from trachyonychia
Alopecia areata	Often difficult to make a distinction, as the geometric, superficial pitting is similar to that in the shiny trachyonychia variety; in a study of 272 pediatric patients with alopecia areata, one-third exhibited pitting, but only 12% were considered to have trachyonychia [55]
Brittle nails	Nails have some longitudinal ridging and superficial splitting but do not exhibit the typical roughness and excessive ridging as seen in trachyonychia
Lichen planus of the nails	Nails exhibit longitudinal fissures and pterygium, which are not seen in trachyonychia [56]
Psoriasis	Nails exhibit pitting, oil spots, and nail bed discoloration, onycholysis, subungual hyperkeratosis, and splinter hemorrhages [57]
Senile nails	Mild longitudinal ridging that does not usually involve the entire nail plate as in trachyonychia

In the more severe or opaque form, the nails have a ‘sandpaper-like’ appearance. These nails present excessive longitudinal ridging due to fine parallel oriented superficial striations. They look thin, rough, and fragile with frequent onychoschizia. The cuticle is hyperkeratotic and

irregular. However, they do not show longitudinal fissures (onychorrhexis), distal splitting, or crumbling (fig. 2). In mild or shiny trachyonychia, the nails retain their luster as they present with multiple small geometric pits arranged to form longitudinal ridges. These reflect light and the nails are not as thin and fragile as in opaque trachyonychia (fig. 3). A differential diagnosis of trachyonychia is presented in table 3.

The extent of inflammation in the nail matrix is thought to contribute to the wide range of severity observed in trachyonychia. Tosti et al. [27] have hypothesized that when inflammation is severe and persistent, diffuse damage causes an opaque variety. In contrast, mild and intermittent inflammation results in multifocal damage, with nails that retain their luster as a result [4]. This hypothesis is supported by the variable location of histopathologic changes observed in trachyonychia, which are more prominent in the proximal nail matrix and ventral proximal nail fold; this nonuniform inflammatory activity results in a spectrum of disease severity [28].

Trachyonychia is a clinical diagnosis and there is no indication for a nail biopsy in these patients. Trachyonychia never causes permanent nail damage or pterygium, including cases of trachyonychia caused by lichen planus, and for this reason, there is no necessity for a nail matrix punch or longitudinal nail biopsy, which is invasive and can cause scarring. Pathological studies of trachyonychia showed that the most common features are



Color version available online

Fig. 4. Trachyonychia: spontaneous improvement. Same patient as in figure 2 after 2 years. Nails are still thin but not rough.

spongiosis and exocytosis of inflammatory cells into the nail epithelia [3, 27, 29, 30]. Histopathology can also show the features of nail matrix lichen planus or nail matrix psoriasis. Further, trachyonychia due to nail lichen planus has been reported to occur in patients with alopecia areata [3, 31], suggesting that these two diseases can occur simultaneously [28].

Treatment

Trachyonychia is a chronic condition. However, it is important to keep in mind that it is neither scarring nor painful, so treatment is often prescribed only for cosmetic reasons and patients may often improve without any treatment. In a case series, 50% of patients ($n = 12$) experienced resolution or considerable improvement in 6 years regardless of treatment [32] (fig. 4). In patients with idiopathic trachyonychia as well as in those with childhood onset with symptoms lasting more than 6 years, spontaneous improvement is less common [32].

For patients who desire cosmetic improvement and patients with very severe varieties who have difficulty with daily manual functions [33], there are many treatment modalities reported in the literature but no standard evidence-based approaches. Conservative approaches include mild emollients and camouflage with nail polish. An emollient may improve the nail surface texture in opaque trachyonychia, while nail polish can help improve appearance in shiny trachyonychia [4].

Topical options include corticosteroids, tazarotene gel [34], and 5% 5-fluorouracil [35]. However, use of topical tazarotene gel and 5-fluorouracil has only been reported in the literature in one case each. A more recent study of 36 patients with 432 affected nails has found significant improvement in 98.6% of nails after 6 months of treatment with calcipotriol/betamethasone dipropionate ointment [36].

Procedure-based options reported in the literature include nail plate dressings (ultra-thin adhesive bandage applied once a week with lactic acid, silicon dioxide, aluminum acetylacetonate, copolymer of vinyl acetate with acrylic acid, and azelaic acid) [37], intralesional injection of triamcinolone into the proximal nail fold [38–40], and topical psoralen UVA [41]. The once weekly nail plate dressings were found to improve symptoms after 3 months in a pediatric patient [37]. Intralesional triamcinolone improved symptoms in 17 of 25 reported cases [38–40]. This option, while appearing efficacious, is uncomfortable and may not be an appropriate selection for some pediatric patients.

Systemic treatments include biotin 2.5 mg/day [42], cyclosporine 2–3.5 mg/kg/day [43, 44], retinoids [33], systemic corticosteroids [45, 46], and tofacitinib citrate [47]. In cases of trachyonychia due to psoriasis, acitretin is an effective option [33]. As treatment for trachyonychia is primarily for cosmetic reasons, the decision to treat systemically should be made carefully in regard to risk factors and patient preference.

Conclusion

As we presented above, the diagnosis of twenty-nail dystrophy should be carefully considered, as there are other conditions that can cause widespread nail dystrophy such as inflammatory and systemic diseases, ectodermal disorders, and infection. We found that trachyonychia and twenty-nail dystrophy have been misdiagnosed in the literature in several cases [5, 35, 41, 48–52] (table 1). The diagnosis is often incorrectly based on the presence of dystrophic nail changes on all twenty nails, despite the fact that the nails do not show specific signs of trachyonychia.

We also want to emphasize that the diagnosis of trachyonychia is based on a specific morphology and the presence of fissures and splitting is not consistent with this diagnosis. Additionally, it is important to avoid the statement that trachyonychia is characterized by dystrophy of all twenty nails [51] which, as we demonstrate in this review, is not accurate.

In conclusion, trachyonychia is a chronic condition that can be idiopathic or associated with a variety of cutaneous and systemic conditions. The diagnosis should be made carefully, with consideration of the key clinical features including brittle, thin nails with excessive longitudinal ridging in severe forms or superficial ridging with geometric pitting and retention of nail luster in less severe forms.

Disclosure Statement

A.A.J. has no disclosures to report. A.T. is an advisor for Meiji, Valeant Pharmaceuticals, Viamet Pharmaceuticals, Pharmaderm, Polichem, and a speaker for Pharmaderm.

References

- Alkiewicz J: Trachyonychia. *Ann Dermatol Venereol* 1950;10:136–140.
- Hazelrigg DE, Duncan WC, Jarratt M: Twenty-nail dystrophy of childhood. *Arch Dermatol* 1977;113:73–75.
- Tosti A, Fanti PA, Morelli R, Bardazzi F: Trachyonychia associated with alopecia areata: a clinical and pathologic study. *J Am Acad Dermatol* 1991;25:266–270.
- Tosti A, Piraccini BM, Iorizzo M: Trachyonychia and related disorders: evaluation and treatment plans. *Dermatol Ther* 2002;15:121–125.
- Fernandez-Flores A, Castanon-Gonzalez JA, Guerrero-Ramos B, Castro-Gaytan A, Saeb-Lima M: Systemic amyloidosis presenting with glans penis involvement. *J Cutan Pathol* 2014;41:791–796.
- Braun-Falco O, Dorn M, Neubert U, Plewig G: Trachyonychia: 20-nail dystrophy (in German). *Hautarzt* 1981;32:17–22.
- Lau YM, Lam YK, Leung KH, Lin SY: Trachyonychia in a patient with chronic myeloid leukaemia after imatinib mesylate. *Hong Kong Med J* 2014;20:464.e2.
- Chen W, Yu YS, Liu YH, Sheen JM, Hsiao CC: Nail changes associated with chemotherapy in children. *J Eur Acad Dermatol Venereol* 2007;21:186–190.
- Germain-Lee EL, Zinkham WH: Twenty-nail dystrophy associated with hematologic abnormalities. *Acta Paediatr Scand* 1991;80:977–980.
- Taniguchi S, Kutsuna H, Tani Y, Kawahira K, Hamada T: Twenty-nail dystrophy (trachyonychia) caused by lichen planus in a patient with alopecia universalis and ichthyosis vulgaris. *J Am Acad Dermatol* 1995;33:903–905.
- James WD, Odom RB, Horn RT: Twenty-nail dystrophy and ichthyosis vulgaris. *Arch Dermatol* 1981;117:316.
- Nieves DS, Phipps RP, Pollock SJ, et al: Dermatologic and immunologic findings in the immune dysregulation, polyendocrinopathy, enteropathy, X-linked syndrome. *Arch Dermatol* 2004;140:466–472.
- Leong AB, Gange RW, O'Connor RD: Twenty-nail dystrophy (trachyonychia) associated with selective IgA deficiency. *J Pediatr* 1982;100:418–420.
- Scardamaglia L, Howard A, Sinclair R: Twenty-nail dystrophy in a girl with incontinentia pigmenti. *Australas J Dermatol* 2003;44:71–73.
- Cahali JB, Kakuda EY, Santi CG, Maruta CW: Nail manifestations in pemphigus vulgaris. *Rev Hosp Clin Fac Med Sao Paulo* 2002;57:229–234.
- Sowden JM, Cartwright PH, Green JR, Leonard JN: Isolated lichen planus of the nails associated with primary biliary cirrhosis. *Br J Dermatol* 1989;121:659–662.
- Pucevich B, Spencer L, English JC 3rd: Unilateral trachyonychia in a patient with reflex sympathetic dystrophy. *J Am Acad Dermatol* 2008;58:320–322.
- Aranegui B, Garcia-Cruz A, de la Torre C, Gonzalez-Valladares MG: Trachyonychia and sarcoidosis. *J Am Acad Dermatol* 2010;63:159–160.
- Blanco FP, Scher RK: Trachyonychia: case report and review of the literature. *J Drugs Dermatol* 2006;5:469–472.
- Khandpur S, Bansal A, Sharma VK, Bhatti SS, Singh MK: Twenty nail dystrophy in vitiligo. *J Dermatol* 2007;34:189–192.
- Rajashakar TS, Singh G, Rajkumar V: Segmental vitiligo and twenty-nail dystrophy: an unusual association. *Indian J Dermatol Venereol Leprol* 2008;74:661–662.
- Peloro TM, Pride HB: Twenty-nail dystrophy and vitiligo: a rare association. *J Am Acad Dermatol* 1999;40:488–490.
- Que SK, Sloan B, Dadras SS: Trachyonychia, cutis laxa, and easy bruising of the skin. *Amyloidosis. JAMA Dermatol* 2014;150:1357–1358.
- Peluso AM, Tosti A, Piraccini BM, Cameli N: Lichen planus limited to the nails in childhood: case report and literature review. *Pediatr Dermatol* 1993;10:36–39.
- Tosti A, Piraccini BM, Cambiaghi S, Jorizzo M: Nail lichen planus in children: clinical features, response to treatment, and long-term follow-up. *Arch Dermatol* 2001;137:1027–1032.
- Baran R, Dupre A, Christol B, Bonafe JL, Sayag J, Ferrere J: Vertical striated sand-papered twenty-nail dystrophy (in French). *Ann Dermatol Venereol* 1978;105:387–392.
- Tosti A, Bardazzi F, Piraccini BM, Fanti PA: Idiopathic trachyonychia (twenty-nail dystrophy): a pathological study of 23 patients. *Br J Dermatol* 1994;131:866–872.
- Gordon KA, Vega JM, Tosti A: Trachyonychia: a comprehensive review. *Indian J Dermatol Venereol Leprol* 2011;77:640–645.
- Grover C, Khandpur S, Reddy BS, Chaturvedi KU: Longitudinal nail biopsy: utility in 20-nail dystrophy. *Dermatol Surg* 2003;29:1125–1129.
- Jerasutus S, Suvanprakorn P, Kitchawengkul O: Twenty-nail dystrophy. A clinical manifestation of spongiotic inflammation of the nail matrix. *Arch Dermatol* 1990;126:1068–1070.
- Kanwar AJ, Ghosh S, Thami GP, Kaur S: Twenty-nail dystrophy due to lichen planus in a patient with alopecia areata. *Clin Experiment Dermatol* 1993;18:293–294.
- Sakata S, Howard A, Tosti A, Sinclair R: Follow-up of 12 patients with trachyonychia. *Australas J Dermatol* 2006;47:166–168.
- Tosti A, Bellavista S, Iorizzo M, Vincenzi C: Occupational trachyonychia due to psoriasis: report of a case successfully treated with oral acitretin. *Contact Dermatitis* 2006;54:123–124.
- Soda R, Diluvio L, Bianchi L, Chimenti S: Treatment of trachyonychia with tazarotene. *Clin Exp Dermatol* 2005;30:301–302.
- Schissel DJ, Elston DM: Topical 5-fluorouracil treatment for psoriatic trachyonychia. *Cutis* 1998;62:27–28.
- Park JM, Cho HH, Kim WJ, et al: Efficacy and safety of calcipotriol/betamethasone dipropionate ointment for the treatment of trachyonychia: an open-label study. *Ann Dermatol* 2015;27:371–375.
- Arias-Santiago S, Fernandez-Pugnaire MA, Husein El-Ahmed H, Giron-Prieto MS, Naranjo Sintes R: A 9 year-old child with trachyonychia: a good response with nail plate dressings (in Spanish). *An Pediatr (Barc)* 2009;71:476–477.
- Khandpur S, Reddy BS: An association of twenty-nail dystrophy with vitiligo. *J Dermatol* 2001;28:38–42.
- Khoo BP, Giam YC: A pilot study on the role of intralesional triamcinolone acetonide in the treatment of pitted nails in children. *Singapore Med J* 2000;41:66–68.

- 40 Grover C, Bansal S, Nanda S, Reddy BS: Efficacy of triamcinolone acetonide in various acquired nail dystrophies. *J Dermatol* 2005;32:963–968.
- 41 Halkier-Sorensen L, Cramers M, Kragballe K: Twenty-nail dystrophy treated with topical PUVA. *Acta Derm Venereol* 1990;70:510–511.
- 42 Möhrenschrager M, Schmidt T, Ring J, Abeck D: Recalcitrant trachyonychia of childhood: response to daily oral biotin supplementation: report of two cases. *J Dermatol Treat* 2000;11:113–115.
- 43 Lee YB, Cheon MS, Eun YS, Cho BK, Park YG, Park HJ: Cyclosporin administration improves clinical manifestations and quality of life in patients with 20-nail dystrophy: case series and survey study. *J Dermatol* 2012;39:1064–1065.
- 44 Pierard GE, Pierard-Franchimont C: Dynamics of psoriatic trachyonychia during low-dose cyclosporin A treatment: a pilot study on onychochronobiology using optical profilometry. *Dermatology* 1996;192:116–119.
- 45 Mittal R, Khaitan BK, Sirka CS: Trachyonychia treated with oral mini pulse therapy. *Indian J Dermatol Venereol Leprol* 2001;67:202–203.
- 46 Evans AV, Roest MA, Fletcher CL, Lister R, Hay RJ: Isolated lichen planus of the toe nails treated with oral prednisolone. *Clin Exp Dermatol* 2001;26:412–414.
- 47 Dhayalan A, King BA: Tofacitinib citrate for the treatment of nail dystrophy associated with alopecia universalis. *JAMA Dermatol* 2015;1–2.
- 48 Tonolli VM, Stolf HO, Tonello CS, Pires RB, Abbade LP: Syndrome in question. Hay-Wells syndrome. *An Bras Dermatol* 2014;89:363–364.
- 49 Gupta R, Mehta S, Pandhi D, Singal A: Hereditary punctate palmoplantar keratoderma (PPK) (Brauer-Buschke-Fischer syndrome). *J Dermatol* 2004;31:398–402.
- 50 Kim G, Shin H: Rapp-Hodgkin syndrome. *Dermatol Online J* 2004;10:23.
- 51 Dogruk Kacar S, Ozuguz P, Polat S: Coexistence of psoriasis, and alopecia areata with trachyonychia in a pediatric patient with Turner Syndrome. *Arch Argent Pediatr* 2014;112:e209–e212.
- 52 Rai VM, Sheno SD: Ichthyosis follicularis with congenital atrichia, nail dystrophy and palmoplantar keratoderma. Variant of IFAP syndrome or a new entity? *Dermatol Online J* 2005;11:36.
- 53 Lee YB, Cheon MS, Eun YS, Park HJ, Cho BK: Elkonyxis in association with washboard nail and 20-nail dystrophy. *Int J Dermatol* 2014;53:e11–e13.
- 54 Yokozeki H, Niiyama S, Nishioka K: Twenty-nail dystrophy (trachyonychia) caused by lichen planus in a patient with gold allergy. *Br J Dermatol* 2005;152:1087–1089.
- 55 Tosti A, Morelli R, Bardazzi F, Peluso AM: Prevalence of nail abnormalities in children with alopecia areata. *Pediatr Dermatol* 1994;11:112–115.
- 56 Tosti A, Ghetti E, Piraccini BM, Fanti PA: Lichen planus of the nails and fingertips. *Eur J Dermatology* 1998;8:447–448.
- 57 Reich K: Approach to managing patients with nail psoriasis. *J Eur Acad Dermatol Venereol* 2009;23(suppl 1):15–21.
- 58 Shim JH, Oh SH, Jun JY, Kim JH, Park JH, Lee DY: Trachyonychia as the presenting sign of myeloma-associated amyloidosis. *Int J Dermatol* 2016, Epub ahead of print.