

Acute Liver Failure due to Trazodone and Diazepam

Sofia Carvalhana^a Ana Oliveira^b Pedro Ferreira^b Margarida Resende^b
 Rui Perdigoto^c Eduardo Barroso^c

^aGastroenterology and Hepatology Department, Hospital de Santa Maria, Centro Hospitalar de Lisboa Norte, and

^bIntensive Care Unit and ^cTransplantation Unit, Hospital Curry Cabral, Centro Hospitalar de Lisboa Central, Lisbon, Portugal

Keywords

Antidepressive agents · Diazepam · Liver failure, acute/chemically induced · Trazodone

Abstract

Most antidepressant agents have the potential to cause liver injury, even at therapeutic doses. Nevertheless, drug-induced liver injury (DILI) from antidepressant agents is a rare event. There is no way to prevent idiopathic DILI, but the severity of the reaction may be minimized with prompt recognition and early withdrawal of the agent. We describe a rare case of a 63-year-old man presenting with acute liver failure after 3 months of trazodone and diazepam administration at normal therapeutic doses, requiring liver transplantation. This report should increase physicians' awareness of this complication and call attention to the regular monitoring of liver tests in patients taking trazodone, in order to prevent life-threatening complications.

© 2016 Sociedade Portuguesa de Gastroenterologia
 Published by S. Karger AG, Basel

Insuficiência Hepática Aguda Induzida pela Trazodona e Diazepam

Palavras Chave

Antidepressivos; Diazepam; Insuficiência hepática aguda/induzida quimicamente; Trazodona

Resumo

A maioria dos antidepressivos tem o potencial de causar lesão hepática, mesmo em doses terapêuticas. Contudo, a hepatite tóxica por antidepressivos é um evento raro. Não existe forma de prevenir a hepatite tóxica, mas a sua gravidade pode ser minimizada com o diagnóstico precoce e a retirada antecipada do fármaco. Apresentamos um caso raro de um homem de 63 anos com insuficiência hepática aguda após 3 meses de terapêutica com trazodona e diazepam em doses terapêuticas, com necessidade de transplante hepático. Com este caso pretende-se alertar os clínicos para a possibilidade desta entidade e da necessidade de monitorização regular das provas hepáticas em doentes sob tratamento com trazodona, de forma a prevenir morbilidade e mortalidade.

© 2016 Sociedade Portuguesa de Gastroenterologia
 Publicado por S. Karger AG, Basel

Introduction

Trazodone is a second-generation, nontricyclic antidepressant that has been linked to rare cases of hepatic injury. The onset of injury is usually several months after continuous ingestion and the presentation pattern is commonly one of hepatocellular serum enzyme elevation, although cases with a shorter latency and with a mixed or cholestatic form have also been described [1]. There is no way to prevent idiopathic drug-induced liver injury (DILI), but the severity of the reaction may be minimized with prompt recognition and early withdrawal of the agent. We describe a rare case of acute liver failure (ALF) after 3 months of trazodone and diazepam administration at normal therapeutic doses, requiring liver transplantation.

Clinical Case

A 57-year-old man with no previous medical history was started on diazepam (5 mg/day) and trazodone (200 mg/day) for depression. Three months later, he developed increased jaundice and was admitted. Laboratory test results included marked elevations in serum aminotransferase levels (ALT 4,638 U/L, AST 2,745 U/L), with increases in GGT (603 U/L), alkaline phosphatase (122 U/L), bilirubin levels (12.7 mg/dL), and international normalized ratio (1.84). His liver enzymes were known to be normal in the past. All medications were stopped. Over the next week, he developed encephalopathy, his international normalized ratio (2.37) and bilirubin (25.2 mg/dL) increased, and his factor V fell (from 51 to 29%). He was transferred to a liver transplant center and was listed for urgent liver transplantation. Test results for hepatitis A, B, and C were negative, as were serologic tests for acute cytomegalovirus, herpes simplex, and Epstein-Barr virus infection. Iron and copper studies were normal and autoantibodies were negative. An abdominal ultrasound ruled out biliary obstruction and occlusion of the liver vessels. A liver biopsy showed confluent necrosis involving most of the liver parenchyma, intrahepatic cholestasis, modest inflammation, and evidence of feathery degeneration and ballooning of hepatocytes in parenchyma, but no fat or fibrosis, compatible with toxic ALF (Fig. 1). In order to evaluate the causality between liver manifestation and drug treatment, the Council for International Organizations of Medical Sciences/Roussel Uclaf Causality Assessment Method (CIOMS/RUCAM) scale has been used. The CIOMS/RUCAM scale indicated a “probable” relationship for trazodone and a “possible” relationship for diazepam in causing hepatotoxicity. While the patient was waiting for liver transplantation, encephalopathy worsened requiring mechanical ventilation. He underwent liver transplantation 2 weeks after medication stoppage and he fully recovered.

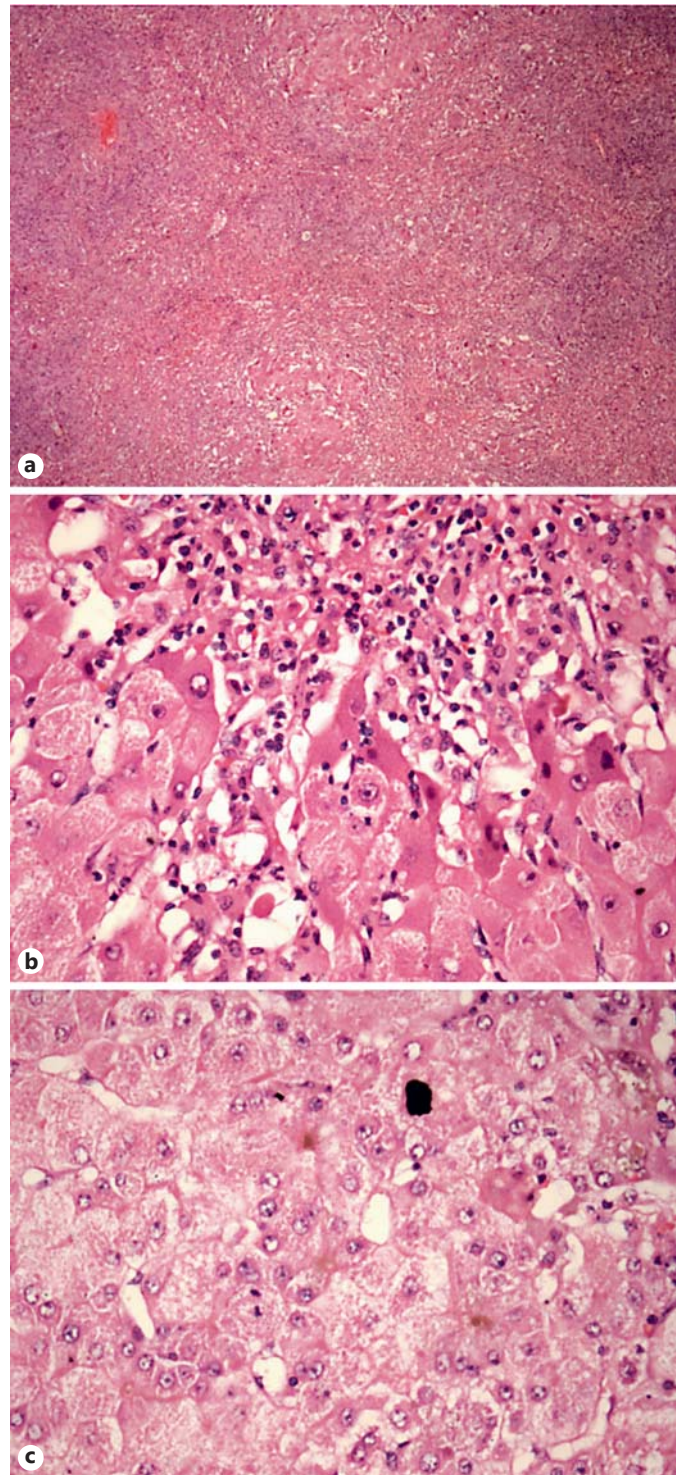


Fig. 1. Photomicrographs of liver biopsy in hematoxylin and eosin staining showing confluent necrosis involving most of the liver parenchyma (**a**, magnification $\times 40$), modest inflammation and evidence of feathery degeneration and ballooning of hepatocytes in parenchyma (**b**, $\times 400$), and intrahepatic cholestasis (**c**, $\times 400$).

Discussion

Trazodone- and diazepam-induced ALF diagnosis was supported by (1) the development of hepatocellular liver injury 3 months after the introduction of trazodone and diazepam, (2) hepatotoxicity as a known adverse side effect of each of the drugs, (3) liver biopsy findings, especially confluent necrosis with inflammatory activity, which is the most common pattern seen in idiosyncratic adverse drug reactions complicated with ALF [2], and (4) exclusion of other etiologies of liver injury. Furthermore, when we assessed the causality by the CIOMS/RUCAM scale for trazodone, the score was in the category of “possible” cause of liver injury.

DILI is a well-recognized problem that accounts for up to 10% of all adverse drug reactions. Two main mechanisms of DILI have been proposed: predictable injury (intrinsic hepatotoxins) and unpredictable injury (idiosyncratic reactions). In our case, an idiosyncratic reaction is likely to be the case. A literature review revealed that both drugs have been known to be implicated in DILI. Trazodone may cause alteration of liver enzyme levels at normal doses, but elevations are usually modest and usually do not require dose modification or discontinuation. Rare instances of ALF and death from trazodone have been described. The onset of liver toxicity may occur a few days or months after drug ingestion and even after the drug has been stopped. The pattern of liver injury is usually hepatocellular, but mixed or cholestatic forms have also been described. Contrarily, increases in liver enzymes during therapy with diazepam are rare and significant hepatotoxicity is uncommon. Only a few cases have been reported and none developed ALF [3]. The onset of injury has ranged from 1 to 6 months, and the pattern of serum enzyme elevations has typically been cholestatic or mixed [3]. The mechanism by which trazodone causes liver damage is unknown. Liver injury from benzodiazepines is probably due to a rarely produced intermediate metabolite.

Downloaded from <http://karger.com/pjg/article-pdf/24/1/40/3437556/000450878.pdf> by guest on 29 November 2023

This case is of special interest for its rarity. To our knowledge, only two other ALF cases associated with trazodone have been reported. Hull et al. [4] reported a 72-year-old woman who developed ALT elevations (107 U/L) 10 weeks after starting trazodone, trifluoperazine, and lithium, developing jaundice at 18 weeks and dying 2 months later. Postmortem liver biopsy revealed acute hepatic necrosis with cholestasis and portal inflammation [4]. The second case occurred in a 48-year-old woman who developed fulminant liver failure after 4 months of trazodone and venlafaxine therapy, requiring liver transplantation [5].

This report should increase physicians' awareness of this complication and call attention to the regular monitoring of liver tests in patients taking trazodone, especially if taken in concomitant therapy such as with other antidepressants or antipsychotics, in order to prevent life-threatening complications.

Acknowledgements

All authors contributed equally. They thank Dr. Ana Carvalho for the liver biopsy pictures.

Statement of Ethics

This study did not require informed consent nor review/approval by the appropriate ethics committee.

Disclosure Statement

The authors have no conflicts of interest to declare.

References

- 1 Fernandes NF, Martin RR, Schenker S: Trazodone-induced hepatotoxicity: a case report with comments on drug-induced hepatotoxicity. *Am J Gastroenterol* 2000;95:532–535.
- 2 Ramachandran R, Kakar S: Histological patterns in drug-induced liver disease. *J Clin Pathol* 2009;62:481–492.
- 3 Larrey D, Ripault MP: Benzodiazepines. Hepatotoxicity of psychotropic drugs and drugs of abuse; in Kaplowitz N, DeLeve LD (eds): *Drug-Induced Liver Disease*, ed 3. Amsterdam, Elsevier, 2013, p 455.
- 4 Hull M, Jones R, Bendall M: Fatal hepatic necrosis associated with trazodone and neuroleptic drugs. *BMJ* 1994;309:378.
- 5 Detry O, Delwaide J, De Roover A, Hans MF, Delbouille MH, Monard J, Honoré P: Fulminant hepatic failure induced by venlafaxine and trazodone therapy: a case report. *Transplant Proc* 2009;41:3435–3436.