

R. Ramirez-Camacho
M. Pinilla
J.R. Garcia-Berrocal

Servicio de Otorrinolaringología, Clínica
Puerta de Hierro, Universidad Autónoma
de Madrid, España

Osteoma of the Promontory: A Case Report

Key Words

Osteoma
Promontory
Middle ear

Abstract

Osteomas of the middle ear are rare lesions. We report the case of a 20-year-old male with osteoma originating from the promontory coincident with tympanic membrane perforation. Histopathological diagnosis was performed by means of a superficial curettage during surgery, to avoid a cochlear fenestration. Postoperative closure of the air-bone gap after myringoplasty confirmed the presumed asymptomatic nature of these lesions.

Introduction

Exostosis of the external auditory canal is a common disorder related to local irritation (i.e. cold baths, prolonged use of stethoscopes, etc.). Its removal is necessary only when it totally, or almost totally, occludes the canal or when endaural surgery needs to be performed in the tympanic cavity. In contrast, the extracanalicular osteoma is uncommon, occurring predominantly in the mastoid process, the squama and the internal auditory canal; other locations are infrequent [1]. Among these, the osteoma of the middle ear is especially rare, with only 9 documented cases to date [2].

This report deals with a case of osteoma on the promontory in a patient who presented tympanic membrane perforation that was corrected by myringoplasty.

Case Report

The patient was a 20-year-old male with a history of occasional suppuration and moderate hearing loss in the right ear, accompanied by tinnitus, with no vestibular symptoms. Physical examination revealed right tympanic membrane perforation surrounding an excrescence of the promontory, like a guinea pig cochlea, which was whitish and of bony consistency to the touch. The audiogram revealed moderate conductive hearing loss. Computed tomography (CT) disclosed the presence of a bony mass covering the promontory

at the level of the basal turn of the cochlea identified as an osteoma. No further anomalies were detected in the temporal bone or the other ear (fig. 1).

A myringoplasty by the retroauricular approach was performed to close the tympanic membrane perforation. Examination of the ear disclosed lower central perforation, through which it was possible to view an excrescence of the promontory complicating the underlay myringoplasty. For this reason, it was decided to employ an overlay technique. The mobility of the ossicular chain was normal. The histologic diagnosis of the osteoma was confirmed by curettage (fig. 2).

The patient presented no postoperative complications and the air-bone gap disappeared. At a follow-up examination 2 years later, the closure of the air-bone gap persisted. A control CT scan gave no evidence of growth of the osteoma.

Discussion

Although the etiology of the osteoma remains unknown, several factors (injury, infection and inheritance) are considered to be potential causes, even though in most cases, there is no evidence of any of them [1].

The origin of the osteoma in our patient, as well as that reported by Yamasoba et al. [3] and the second patient of Silver et al. [2], may have been an inflammatory reaction of the periosteum [4]. However, another case described in the literature [5] presented no history of otitis media. The fact that familial cases have been reported [6] and the

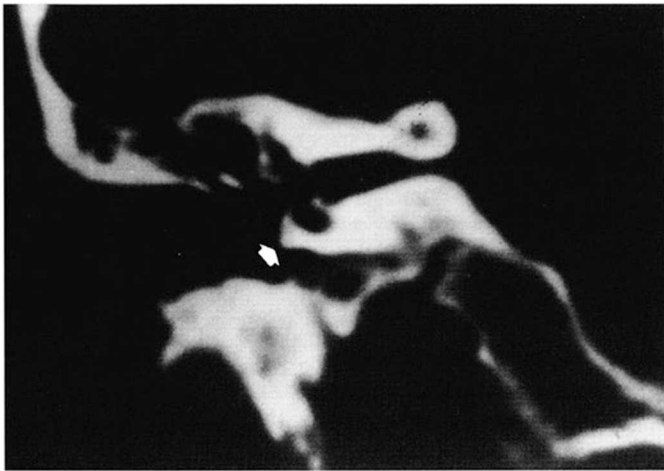


Fig. 1. Coronal CT image showing osteoma emerging on the promontory.

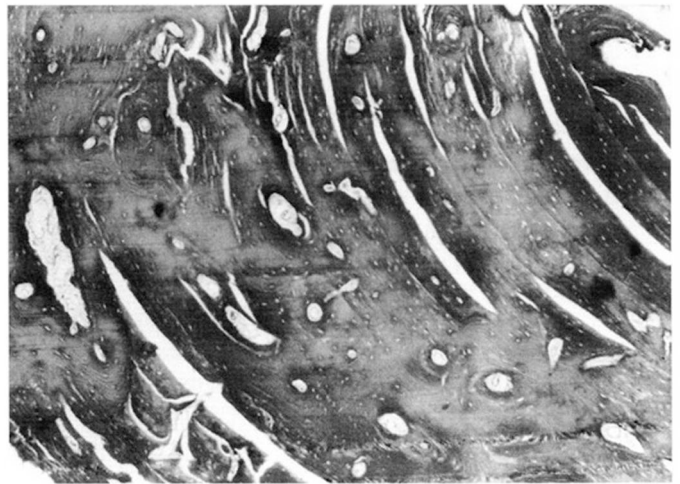


Fig. 2. Osseous osteomatous reaction ('osteoma'), showing thick trabeculae cemented by concentric lines of mature bone, with very limited intratrabecular stromal space which becomes collapsed and compressed by the osteomatous growth.

increased frequency of onset in those regions that, not being covered by mucosa, are not susceptible to infections (temporal squama, the internal auditory canal, the petrous apex and the styloid process), but are susceptible to injury, seems to indicate that there must be more than one cause for the development of osteomas.

To date, only 9 cases have been reported in the tympanic cavity. Thomas [6] describes the case of 2 brothers with localization in the pyramidal eminence, coinciding with the location of that reported by Yamasoba et al. [3]; other sites are the fallopian tube, the footplate [7], the promontory [2, 5, 8], the lateral semicircular canal [9] and the incus [10]. The osteoma of our patient was situated in the bone over the basal turn of the cochlea and had no contact with the ossicles. Thus, its presence did not affect the

auditory function as demonstrated by the closing of the air-bone gap in spite of most of the tumor remaining intact. The decision to leave the osteoma was based on the experience reported by Cremers [8], when excision was followed by perforation of the cochlea. If one accepted that the osteoma in the presented case may have been caused by an irritative effect, via the perforation of the tympanic membrane, on the periosteum of the promontory, it could be expected that further growth would be prevented once the perforation was closed. Moreover, the possibility that techniques employed in its excision might accelerate its growth, has rendered its total removal inadvisable. Periodical follow-up with CT imaging is planned.

References

- Denia A, Pérea F, Canalis RR, Graham D: Extracanalicular osteomas of the temporal bone. *Arch Otolaryngol Head Neck Surg* 1979; 105:706-709.
- Silver FM, Orobello PW, Mangal A, Pensak ML: Asymptomatic osteomas of the middle ear. *Am J Otol* 1993;14:189-190.
- Yamasoba T, Harada T, Okuno T, Nomura Y: Osteoma of the middle ear. Report of a case. *Arch Otolaryngol Head Neck Surg* 1990;116: 1214-1216.
- Friedberg S: Osteoma of the mastoid process. *Arch Otolaryngol Head Neck Surg* 1938;28: 20-26.
- Glasscock ME, McKenna KX, Levine SC: Osteoma of the middle ear: A case report. *Otolaryngol Head Neck Surg* 1987;97:64-65.
- Thomas R: Familiar osteoma of the middle ear. *J Laryngol Otol* 1964;70:805-807.
- Ombredane M: Ostéome exceptionnel de l'oreille moyenne. *Ann Otolaryngol* 1966;83: 433-436.
- Cremers CW: Osteoma of the middle ear. *J Laryngol Otol* 1985;99:383-386.
- Ito S, Tanaka H, Hirano M: Clinical Records: Osteoma of the middle ear. *J Laryngol Otol* 1990;104:803-806.
- Milroy CM, Phelps PD, Michaels L, Grant H: Osteoma of the incus. *J Otolaryngol* 1989;18: 226-228.