

Masami Yoshida
Tadashi Tezuka

Department of Dermatology,
School of Medicine Kinki University,
Osaka, Japan

Conjunctivitis Caused by Human Parvovirus B 19 Infection

Key Words

Erythema infectiosum
Human parvovirus B 19
Conjunctivitis

Abstract

A 26-year-old woman with erythema infectiosum is reported. She had small faint erythemas on her extremities and congestion of palpebral and bulbar conjunctiva of both eyes. Human parvovirus B 19 (B 19) DNA was detected in the specimen of the conjunctiva by the polymerase chain reaction. This result suggests that conjunctivitis in erythema infectiosum may cause the B 19 infection.

Introduction

Erythema infectiosum is well known as a benign and self-limited disease. Human parvovirus B 19 (B 19) was discovered as the etiologic agent of the illness by Anderson et al. [1] in 1983. Typical clinical features of erythema infectiosum in children show malar erythema on the face, causing the so-called 'slapped cheek' appearance, and reticulated or lacy erythemas on the trunk and extremities [2]. In adults, however, atypical skin rash and arthralgia commonly occur [3, 4].

It has been reported that sore eyes or conjunctivitis occurs before or after the onset of skin rash caused by erythema infectiosum [2, 4, 5]. However, only little attention has been paid to this symptom. We report on a 26-year-old patient with erythema infectiosum who developed palpebral and bulbar conjunctivitis of both eyes, and of the detection of B 19 DNA from the conjunctiva by the polymerase chain reaction (PCR).

Case Report

A 26-year-old woman, who is a nurse, visited our hospital on May 8, 1992. She consulted us about small faint erythemas on her extremities. She had no past history of erythema infectiosum. On April 27, she had a sore throat. Two days later, she felt shoulder joint pain and lumbago, and her body temperature rose to 39°C. One day before her first visit, she developed small faint erythemas on her extremities and

conjunctival congestion in both her eyes. Physical examination revealed that small faint macular erythemas were seen on her extremities, but not on her face. Congestion of both the palpebral and bulbar conjunctiva was also observed. However, no ocular symptoms other than the conjunctival congestion were seen by the ophthalmologist. The patient's body temperature was 37.5°C. The clinical course of the patient was followed up without receiving any medication. On May 15, the skin rash and fever disappeared. However, the degree of conjunctival congestion was stronger than on May 8. No skin rash was found on the face during the course of the illness. On May 29, the conjunctival congestion had almost disappeared.

Detection of B 19 DNA was performed by PCR [6]. Specimens were collected from the palpebral conjunctiva of both eyes by rubbing with a sterile cotton swab which was then washed into PBS. The leukocyte-rich fraction was separated from heparinized peripheral blood. Then each specimen was centrifuged and the deposits were treated with Gene Releaser[®] (Bioventures) according to the manufacturer's instructions. The two primer sets and their location in the B 19 sequence are as follows [7]:

5'-GTA CGC CCA TCC CCG GGA CCA CTT CAG G-3'
(2060–2087)
5'-CAG GTA AAC CCC TTA CAC CGT CCC ACA C-3'
(2203–2230)

Thermal cycling was at 94°C for 1 min and 64°C for 2 min, where the complement DNA was composed [7]. After 35 cycles of PCR, the reaction products were electrophoresed in an agarose gel and stained by ethidium bromide. The PCR products of B 19 DNA were detected in each specimen of peripheral blood, in the conjunctiva on May 8, conjunctiva on May 15, but not in the specimen of conjunctiva on May 29 (fig. 1).

Received:
October 18, 1993
Accepted:
December 29, 1993

Dr. M. Yoshida
Department of Dermatology
School of Medicine Kinki University
Ohnohigashi 377-2
Osakasayama, Osaka, 589 (Japan)

© 1994 S. Karger AG, Basel
0030-3755/94/2083-0161
\$ 5.00/0

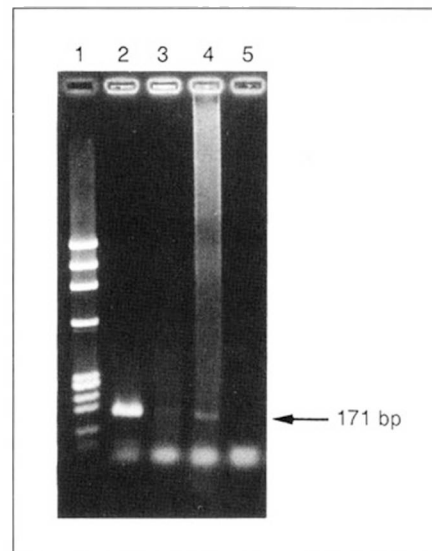
Serum for the measurement of virus antibody was collected from the patient on May 8, 1992. The test was performed by enzyme-linked immunosorbent assay (IBL). The titers of the specific IgG and IgM antibodies against B19 were 1.42(+) and 3.40(+), respectively. This result suggests primary B19 infection.

Discussion

It has been reported that B19 is the causative agent of hydrops fetalis, often resulting in fetal death in pregnant women [8, 9], aplastic crisis in patients with chronic hemolytic anemia [10] and severe chronic anemia in immunodeficient patients [11, 12]. Also, erythema infectiosum is documented as a disease caused by B19 infection [1]. The characteristic clinical features of erythema infectiosum are well known as showing 'slapped cheek' appearance and lacy erythemas on the extremities [2]. However, only little attention has been paid to sore eyes or conjunctivitis occurring with erythema infectiosum. Anderson [4] reported that sore eyes or conjunctivitis appeared in 4–27% of B19-infected patients. Moreover, Plummer et al. [5] reported that conjunctivitis occurs before or after the onset of the skin rash caused by erythema infectiosum.

Although our patient showed atypical clinical features of erythema infectiosum, B19 DNA was detected in peripheral blood and conjunctiva, and specific IgM antibody against B19 was positive, which certainly indicates primary B19 infection. In this case, conjunctivitis developed simultaneously with the skin rash on the extremities, but no eruption occurred on the face throughout the course of the illness. The degree of conjunctival congestion was the strongest on May 15, and almost disappeared on May 29. B19 DNA was

Fig. 1. Detection of human parvovirus B19 DNA in peripheral blood and conjunctiva. 1 = Molecular marker; 2 = peripheral blood, May 8; 3 = conjunctiva, May 8; 4 = conjunctiva, May 15; 5 = conjunctiva, May 29.



detected in the specimen of conjunctiva on May 8 and May 15, but not on May 29, suggesting that the inflammation on the conjunctiva caused by B19 infection is transient.

Our patient is a nurse. In hospital, a number of immunosuppressive patients or pregnant women, who have a high risk of developing severe clinical symptoms caused by B19 [8–12], are often admitted. Our result suggests that conjunctivitis in erythema infectiosum may become the infectious source of the B19 infection. Therefore, more attention should be paid to conjunctivitis and such associated things as tears in medical staff with erythema infectiosum, even when the skin rash is not found on the face, as one of the infectious sources of B19 infection to hospitalized patients.

References

- Anderson MJ, Jones SE, Fisher-Hoch SP, Lewis E, Hall SM, Bartlett CLR, Cohen BJ, Mortimer PP, Pereira MS: Human parvovirus, the cause of erythema infectiosum (fifth disease)? *Lancet* 1983;ii:1378.
- Anderson MJ, Lewis E, Kidd IM, Hall SM, Cohen BJ: An outbreak of erythema infectiosum associated with human parvovirus infection. *J Hyg (Camb)* 1984;93:85–93.
- Woolf AD, Campion GV, Chishick A, Wise S, Cohen BJ, Klouda PT, Caul O, Dieppe PA: Clinical manifestations of human parvovirus B19 in adult. *Arch Intern Med* 1989;149:1153–1156.
- Anderson LJ: Role of parvovirus B19 in human disease. *Pediatr Infect Dis J* 1987;6:711–718.
- Plummer FA, Hammond GW, Forward K, Sekla L, Linda M, Thompson RN, Jones SE, Kidd IM, Anderson MJ: An erythema infectiosum-like illness caused by human parvovirus infection. *N Engl J Med* 1985;313:74–79.
- Saiki RK, Gelfand DH, Stoffel S, Scharf SJ, Higuchi RG, Horn GT, Mullis KB, Erlich HA: Primer-directed enzymatic amplification of DNA with a thermostable DNA polymerase. *Science* 1988;239:487–491.
- Sevall JS: Detection of parvovirus B19 by dot-blot and polymerase chain reaction. *Mol Cell Probes* 1990;4:237–246.
- Brown T, Anand A, Ritchie LD, Clewley JP, Reid TMS: Intrauterine parvovirus infection associated with hydrops fetalis. *Lancet* 1984;ii:1033–1034.
- Knott PD, Welply GAC, Anderson MJ: Serologically proved intrauterine infection with parvovirus. *Br Med J* 1984;289:1660.
- Serjeant GR, Topley JM, Mason K, Sergeant BE, Pattison JR, Jones SE, Mohamed R: Outbreak of aplastic crises in sickle cell anaemia associated with parvovirus-like agent. *Lancet* 1981;ii:595–597.
- Kurtzman GJ, Cohen B, Meyer P, Amunullah A, Young NS: Persistent B19 parvovirus infection as a cause of severe chronic anaemia in children with acute lymphocytic leukemia. *Lancet* 1988;ii:1159–1162.
- Kurtzman GJ, Ozawa K, Cohen B, Hanson G, Young NS: Chronic bone marrow failure due to persistent B19 parvovirus infection. *N Engl J Med* 1987;317:287–294.