

# Ophthalmologica

International Journal of Ophthalmology  
Journal International d'Ophtalmologie  
Internationale Zeitschrift für Augenheilkunde

---

Organ of the Netherlands Ophthalmological Society

Founded 1899 as 'Zeitschrift für Augenheilkunde' by H. Kuhnt and J. von Michel

Continued by J. Meller (1923–1938), C. Behr (1925–1938), A. Brückner (1938–1959), H.J.M. Weve (1938–1962),  
H.M. Dekking (1954–1966), J. ten Doesschate (1967–1971), J. François (1959–1979), E.B. Streiff (1954–1979)

**Honorary Editors:**

J. François, Ghent  
E.B. Streiff, Lausanne

**Coordinating Editor:**

W. Straub, Marburg a.d. Lahn

**Editors:**

F.C. Gailloud, Lausanne  
H. Neubauer, Köln  
M.J. Roper-Hall, Birmingham  
H. Sautter, Savognin  
N.M.J. Schweitzer, Groningen  
R. Witmer, Zürich

**Co-Editors:**

D.R. Barry, Birmingham  
F.C. Blodi, Iowa City  
F. Fankhauser, Bern  
W.A. Houtman, Groningen  
J. Lang, Zürich  
C. Ossoinig, Iowa City  
E. Prijot, Liège  
H. Saraux, Paris  
A. Steele, London  
E. van der Zypen, Bern  
G. van Lith, Rotterdam

---

All rights reserved.

No part of this publication may be translated into other languages, reproduced or utilized in any form or by any means, electronic or mechanical, including photocopying, recording, microcopying, or by any information storage and retrieval system, without permission in writing from the publisher.

S. Karger AG, P.O. Box, CH-4009 Basel (Switzerland)  
Buchdruckerei Friedrich Reinhardt AG, Basel

Drug Dosage

The authors and the publisher have exerted every effort to ensure that drug selection and dosage set forth in this text are in accord with current recommendations and practice at the time of publication. However, in view of ongoing research, changes in government regulations, and the constant flow of information relating to drug therapy and drug reactions, the reader is urged to check the package insert for each drug for any change in indications and dosage and for added warnings and precautions. This is particularly important when the recommended agent is a new and/or infrequently employed drug.

# Index Vol. 182, 1981

## No. 1

### Original Papers · Travaux originaux · Originalarbeiten

Zur Rekonstruktion verletzter Tränenwege im Canaliculus-Bereich (Reconstruction after Injuries of the Lacrimal Canaliculus) Oggel, K. . . . .	1
Bloody Tears from an Orbital Varix (with 1 color plate) Bonavolontà, G.; Sammartino, A. . . . .	5
Bilateral Central Retinal Vein Occlusion in a Patient with Scleroderma Saari, K.M.; Rudenberg, H.A.; Laitinen, O. . . . .	7
Anterior Ischemic Optic Neuropathy. VI. In Juvenile Diabetics Hayreh, S.S.; Zahoruk, R.M. . . . .	13
Posterior Ischemic Optic Neuropathy Hayreh, S.S. . . . .	29
Eosinophilic Granuloma of the Soft Tissue in the Orbit Amemiya, T. . . . .	42
Häufigkeit der HLA-Antigene bei griechischen Patienten mit Offenwinkel-Glaukom (Frequency of HLA Antigens in Greek Patients with Open-Angle Glaucoma) Gabriel, L.; Renieri, N.; Stavropoulos, C. . . . .	49
<b>Clinicopathologic Case Report</b>	
Iridic Metastasis of a Uterine Carcinoma Planten, J.T. . . . .	55
Book Review · Livre nouveau · Buchbesprechung . . . . .	59
Announcement · Communication · Ankündigung . . . . .	60

## No. 2

### Strabismus and Tumors of the Uvea

Introduction . . . . .	64
Congenital Nystagmus: Clinical Types and Their Surgical Treatment Spielmann, A. . . . .	65
Kinetic Electro-Oculography: Aims – Disadvantages and Limitations Quéré, M.A.; Pêchereau, A.; Lavenant, F. . . . .	73
The Muscle Elongation Test in Functional Squints. History – Basis and Clinical Features Quéré, M.A.; Pêchereau, A.; Clergeau, G. . . . .	81
The Muscle Elongation Test in Functional Esotropias. Statistical Survey of 211 Cases Quéré, M.A.; Pêchereau, A.; Lavenant, F. . . . .	90

Quantitative Study of Superior Oblique Paralysis Using a Synoptometer Péchereau, A.; Quéré, M.A. . . . .	96
Surgical Results in Functional Squints. Analysis and Pathogenetic Meaning Quéré, M.A.; Péchereau, A. . . . .	104
Cavernous Hemangioma of the Choroid. Clinical Review of 10 Cases Bonnet, M. . . . .	113
Ocular Findings in a Case of Incontinentia Pigmenti (Bloch-Sulzberger Syndrome) Berbich, A.; Dhermy, P.; Majbar, M. . . . .	119
Corneal Decompensation in Chandler's Syndrome. Clinical, Histopathologic and Ultrastructural Study Offret, H.; Saraux, H. . . . .	130
Non-Surgical Treatment of Tumours of the Choroid Haye, C. . . . .	136

### No. 3

#### Original Papers · Travaux originaux · Originalarbeiten

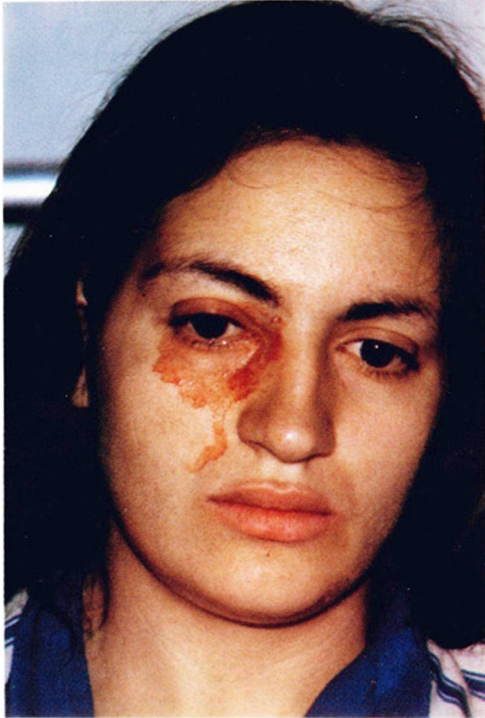Intraocular Pressure Elevation – Cause or Effect in Chronic Glaucoma? Krakau, C.E.T. . . . .	141
Acute Ocular Hypotony. A Rare Complication of Temporal Arteritis Radda, T.M.; Bardach, H.; Riss, B. . . . .	148
Nail Pigmentation following Timolol Maleate Therapy Feiler-Ofry, V.; Godel, V.; Lazar, M. . . . .	153
Exfoliative Cytology in the Diagnosis of Conjunctival Tumours Lopez Cardozo, P.; Oosterhuis, J.A.; Wolff-Rouendaal, D. de . . . . .	157
Orbital Phycomycosis Gutierrez Diaz, A.; Palacio Hernanz, A. del; Larregla, S.; Sanz Lopez, A. . . . .	165
Densitometric Analysis of Macular Fluorescein Angiography Cardillo Piccolino, F.; Zingirian, M.; Parodi, G.C. . . . .	171
Richtungswechselnder Spontannystagmus mit synchronem Wechsel der Pupillen- und Lidspaltenweite. Okulo-pupillomotorisches Syndrom bei Erblindung im Rahmen einer Dysgenese mesodermalis iris et corneae Rieger (Direction-Changing Spontaneous Nystagmus with Simultaneous Change in Pupil Diameter and Eyelid Interspace. Oculopupillomotor Syndrome in Blindness Due to Dys- genesis mesodermalis iridis et corneae Rieger) Piper, H.F.; Kömpf, D.; Neundörfer, B. . . . .	175
Book Reviews · Livres nouveaux · Buchbesprechungen . . . . .	190
Announcement · Communication · Ankündigung . . . . .	192

### No. 4

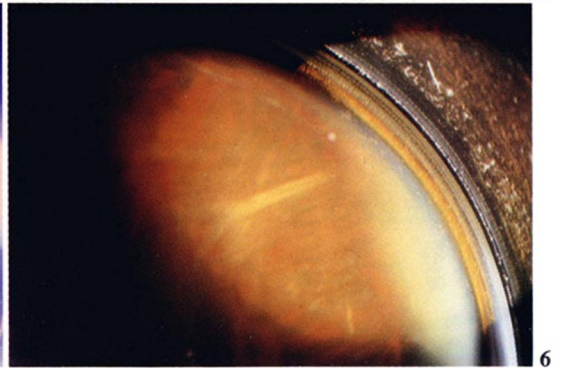
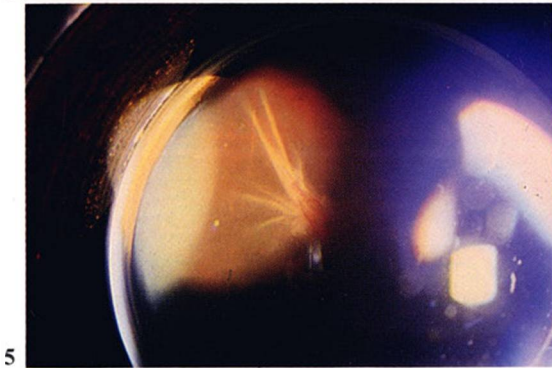
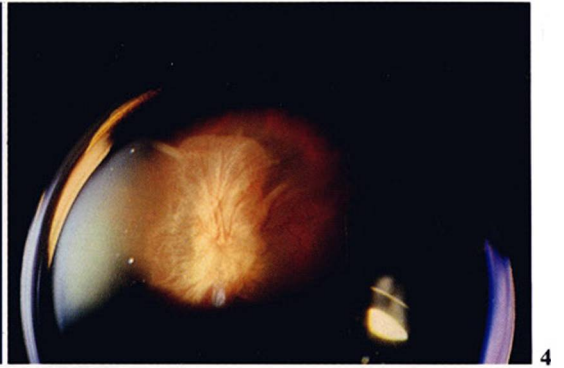
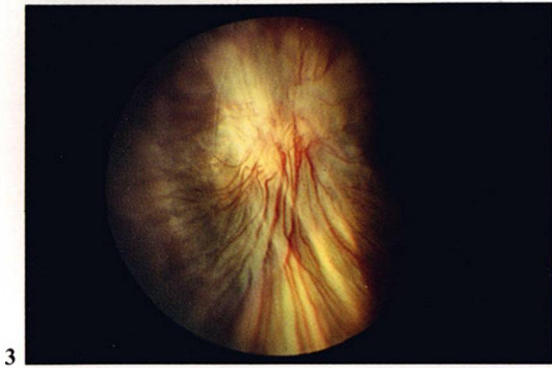
#### Original Papers · Travaux originaux · Originalarbeiten

Ocular and Orbital Complications after Sclerosing Injections in a Case of a Frontal Cutaneous Angioma Chamot, L.; Zografos, L.; Micheli, J.L. . . . .	193
---	-----

<b>Bilateral Acute Vascular Retinal Necrosis (with 1 color plate)</b>	
Severin, M.; Neubauer, H. . . . .	199
<b>Central Serous Chorioretinopathy: Some Considerations on the Pathogenesis</b>	
Piccolino, F.C. . . . .	204
<b>The Latent Period of the Pupil Light Reflex in Lesions of the Optic Nerve</b>	
Alexandridis, E.; Argyropoulos, Tr.; Krastel, H. . . . .	211
<b>Quantitative Evaluation of the Electroretinogram</b>	
Lith, G. van . . . . .	218
<b>A Portable ERG System with an Automatic Driven LED Ganzfeld Stimulation Contact Lens</b>	
Kooijman, A.; Damhof, A. . . . .	224
<b>Tagungsbericht . . . . .</b>	229
<b>Book Reviews · Livres nouveaux · Buchbesprechungen . . . . .</b>	231
<b>Announcements · Communications · Ankündigungen . . . . .</b>	234
<b>Author Index . . . . .</b>	235
<b>Subject Index . . . . .</b>	236



**Fig. 3.** Bloody transudate occurring a few minutes after nasal and jugular compression.



**Fig. 3.** Patient D.H. Findings on September 11th 1980. RE: proliferative plate in front of the papilla.

**Fig. 4.** Findings in September 1980. RE: central proliferative plate, choroid exposed in the intermediate region.

**Fig. 5.** Findings on September 11th 1980. LE: individual strands reaching from the proliferative central plate to the periphery.

**Fig. 6.** Findings on September 11th 1980. LE: attempt at showing the periphery of the fundus with border of necrotic retina, central to the exposed choroid.

Downloaded from <http://karger.com/oph/article-pdf/182/4/1334/1246/000309124.pdf> by guest on 09 October 2024