

# Systemic BRAF/MEK Inhibitors as a Potential Treatment Option in Metastatic Conjunctival Melanoma

Joel M. Mor · Ludwig M. Heindl

Department of Ophthalmology, University of Cologne, Cologne, Germany

## Keywords

Conjunctival melanoma · BRAF inhibitor · MEK inhibitor · Primary acquired melanosis · Metastatic disease

## Abstract

**Aim:** In this review, we outline similarities between conjunctival and skin melanoma as well as the effectiveness of combined BRAF/MEK inhibition in melanoma, and discuss the applicability of these agents in conjunctival melanoma.

**Methods:** The study provides a PubMed literature review.

**Results:** Conjunctival melanoma and skin melanoma are genetically and phenotypically related. Both tumors typically harbor BRAF mutations in more than 50% of cases. New targeted therapies in metastatic skin melanoma include selective inhibition of BRAF and MEK. Combined BRAF/MEK inhibition has revolutionized the treatment of metastatic skin melanoma, significantly improving patients' prognoses. While these new substances have been investigated extensively in the treatment of skin melanoma, comparable studies in conjunctival melanoma do not exist owing to the rarity of the malignancy. **Conclusions:** The application of combined BRAF/MEK inhibition in metastatic or unresectable conjunctival melanoma shows great potential for improving patients' prognoses. Future studies are needed to investigate the assumed benefit.

© 2016 S. Karger AG, Basel

## Introduction

Conjunctival melanoma (CM) is a very rare, yet often life-threatening, malignant tumor of the eye. At approximately 0.15–0.78 cases per million per year, depending on the population observed, it is the third most common primary malignant ocular tumor (the other 2 being uveal melanoma [UM] and conjunctival squamous cell carcinoma) [1–3]. The 10-year mortality observed ranges between 27 and 30% [4–7]. Local recurrence within 5 and 10 years after primary therapy was estimated to occur in up to 26 and 51% of cases, respectively, and locoregional lymph node metastasis as well as distant metastasis can be observed in up to 41 and 26% of cases, respectively [6, 8–11]. In about 71% of cases, CM develops from a progenitor lesion called “primary acquired melanosis (PAM) with atypia.” However, CM can also develop de novo (up to 19%) or, in rare instances, from benign nevi (up to 7%) [5, 6, 10]. Lately, the term “PAM” has been the subject of debate owing to the lack of histopathological distinction between benign melanin overproduction and melanocytic proliferation. More precise terms that have been suggested in lieu of “PAM with atypia” are “conjunctival melanocytic intraepithelial neoplasia” and “intraepithelial melanocytic proliferation” [12, 13].

In contrast to UM, CM seems to be phenotypically and genetically related to malignant melanoma of the skin,

and recent studies have been able to highlight what seem to be comparable traits of the 2 sibling malignancies [11]. For one thing, over the past years, there has been a documented increase in the incidence of malignant melanoma of the skin as well as of the conjunctiva. In particular, the incidence of tumors in locations that are exposed to UV light has increased in both entities, and many authors presume this to be an indicator of phenotypical similarity. In the case of CM, they are predominantly epibulbar tumors developing from PAM, as well as tumors in patients >65 years of age [2, 3, 14–17].

Similar to the melanoma of the skin, CM has been shown to harbor activating mutations of BRAF (rapidly accelerated fibrosarcoma), an oncogenic serine/threonine kinase in the mitogen-activated protein kinase (MAPK) pathway [18]. In skin melanoma, BRAF mutations have been described to occur in 32–60% of cases [17, 19–22]. Similarly, in CM, mutated BRAF can be observed in 29–50% of cases [11, 16, 23]. In contrast, activating mutations of BRAF in UM are virtually nonexistent [2, 24–26].

Furthermore, several overlapping clinical features between CM and skin melanoma can be found. In case of metastasis, both types of tumor usually spread to the regional lymph nodes first, while UM primarily metastasizes hematogenously to the liver [5, 8–10, 27–33]. Both CM and skin melanoma are highly positive for S100 on immunohistochemical staining. In UM, however, S100 expression has been shown to be significantly lower than in CM. Furthermore, serum levels of S100 can also serve as a prognostic marker in skin melanoma [27–36]. Other pigment markers that have been assessed with regard to their labeling of skin melanoma, CM, or UM are tyrosinase, p75<sup>NTR</sup> (p75 neurotrophin receptor), HMB (human melanoma black)-45, HMB-50, melan-A, and microphthalmia-associated transcription factor [34, 36]. While p75<sup>NTR</sup> has been found to exclusively label skin melanoma cells, the remaining pigment markers were shown to label skin melanoma cells as well as CM and UM [34, 36].

The comparability of premalignant lesions in CM and skin melanoma is still subject to discussion, and no clear relationship between PAM with atypia and lentigo maligna has been established yet. While, to some degree, both types of lesion present similar clinical and pathological traits, no solid evidence of phenotypical kinship has been provided to date [37, 38].

Clinical management of CM proves difficult, with high rates of local recurrence and lymphogenic metastasis. Since CM is a rare malignancy, therapy regimes are generally based on experience obtained from relatively few

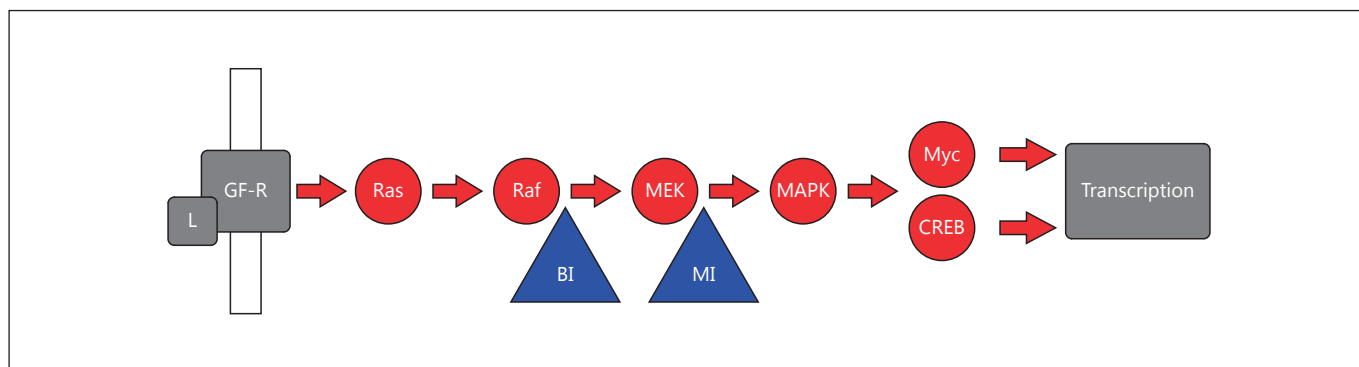
case series throughout recent years. Nevertheless, considering the fact that to a certain extent CM appears to be clinically related to skin melanoma, a few parallels could be cautiously drawn and treatment options that are well established in the clinical management of skin melanoma could logically be adopted for the treatment of CM.

Therapy usually comprises wide surgical excision with cryotherapy applied to the margins followed by adjuvant therapy. The latter includes application of cryotherapy, radiotherapy, or topical chemotherapeutic agents. Radiotherapeutic options encompass brachytherapy, applying either ruthenium-106 or strontium-90 plaques, and proton beam radiation [39–42]. Alternatively, mitomycin C or interferon alfa-2b can be considered for topical administration [43–45]. Additionally, anti-VEGF (vascular endothelial growth factor) targeted therapies such as bevacizumab eye drops have recently been proposed as a novel possibility to prevent metastasis [46].

Unfortunately, in case of metastatic disease, there are no established systemic treatment options available. However, with recent advances in the treatment of skin melanoma, a handful of novel agents targeting specific pathways involved in the generation of prooncogenic stimuli have emerged that might be suited to effectively enhancing disease control in metastatic CM as well. Among these, the use of BRAF inhibitors in combination with MEK (MAPK/ERK kinase) inhibitors is one of the most promising approaches [47, 48]. Through inhibition of the Ras-Raf-MEK/ERK-MAPK (ras, rat sarcoma; ERK, extracellular signal-regulated kinase) pathway, these new substances have been proven to prolong disease-free survival with skin melanoma. Here, we are giving an overview on combined BRAF/MEK inhibition as a potential new treatment option in the management of CM.

### **BRAF Mutations in CM**

The MAPK (Ras-Raf-MEK/ERK) signaling pathway (Fig. 1) is typically hyperactivated in over 80% of malignant melanomas [49]. The BRAF gene encodes B-raf, a serine/threonine kinase that is part of the MAPK pathway, and activating mutations in BRAF have been shown to have a prooncogenic effect that drives cell proliferation as well as tumor progression in melanoma [50]. In up to 50% of CM, activating BRAF mutations can be found [11, 16, 23]. Another notable mutation that is common in CM is hyperactivated NRAS (in up to 18%) [18]. BRAF and NRAS mutations are considered to be mutually exclusive [51].



**Fig. 1.** The MAPK pathway. Following activation of growth factor receptors by their ligands, signal transduction through the Ras-Raf-MEK-MAPK pathway occurs. With the help of Myc and CREB, signals are passed on to the nucleus and lead to transcription of genes that are relevant in proliferation and tumorigenesis. BRAF inhibition tackles signal transduction from Raf to MEK,

whereas further downstream, MEK inhibition stops signal transduction from MEK to MAPK, thus counteracting resistance mechanisms that bypass Raf inhibition. L, ligand of growth factor receptor; GF-R, growth factor receptor; BI, BRAF inhibitor; MI, MEK inhibitor; CREB, cAMP response element-binding protein.

Several specific activating mutations have been identified in exons 11 and 15 of the BRAF gene. Out of the 29–50% of CM that have been described to present a mutation in BRAF [11, 16, 23], 74–82% carry BRAF V600E and 18–20% carry BRAF V600K, with up to 6% carrying other mutations [16, 21].

There is controversy as to whether or not an activating BRAF mutation results in a distinct clinicopathological phenotype in CM, and recent studies have produced conflicting results. Evidence suggests that mutated BRAF is associated with younger age at diagnosis, a sun-exposed location (caruncle or epibulbar conjunctiva), intermittent but not chronic sun damage, development from benign nevi instead of PAM with atypia, T1 stage, and male gender [16, 21, 52–54]. This is in accordance with skin melanoma, where BRAF-mutated tumors have been associated with a distinct, more aggressive phenotype, intermittent sun exposure, and lower age at diagnosis [17, 55, 56].

However, in contrast to skin melanoma, where BRAF mutations are associated with earlier locoregional lymph node metastasis and brain metastasis, no such clinical association could be shown for CM. In a recent study from Denmark, no significant influence of mutated BRAF on mortality, disease-free survival, local recurrence, or distant metastasis was observed for CM [16].

Similar to skin melanoma, BRAF mutations can often already be detected in benign nevi as well as in metastatic CM [11, 16, 49, 57], thus leaving room to speculate that BRAF mutations alone do not generate a distinct clini-

copathological phenotype. Instead, the combination of BRAF mutations with other mutations might drive tumorigenesis towards a more aggressive phenotype that is more prone to metastasis [21].

### BRAF/MEK Inhibitors as a New Treatment Option

At the point of metastatic disease in CM, treatment options become very limited. There are no established systemic chemotherapy protocols available to apply when distant metastases are present. However, since CM and skin melanoma generally present with the aforementioned similarities, treatment regimes that have yielded successful results in skin melanoma might also be applied to CM.

Over the past years, therapy for skin melanoma has been revolutionized by recent advances in the field of targeted therapies. These include selective inhibition of the MAPK pathway by inhibition of either BRAF or the inhibition of MEK, another protein kinase positioned further downstream from BRAF, or combination of the two. Both of these classes of drugs have already been approved by the US Food and Drug Administration (FDA). Available substances include the BRAF inhibitors dabrafenib and vemurafenib as well as the MEK inhibitors trametinib and cobimetinib. However, all of these agents are still subject to further investigation and can only be tried in cases where the MAPK pathway is hyperactivated – which, in skin melanoma as well as in CM, is mostly due to activating mutations of BRAF or NRAS [22, 57, 58].

Vemurafenib is a selective inhibitor of BRAF with proven potential to improve overall prognosis in the treatment of BRAF-mutated metastatic melanoma of the skin. Several phase II and phase III trials have been conducted to investigate the presumed benefit. The trials included patients with unresectable stage III or IV melanoma positive for either BRAF V600E or BRAF V600K. In the available studies, vemurafenib single-agent therapy was either tried without a control group in a study including 132 patients [22] or compared to dacarbazine treatment in a trial including 675 patients [59]. Later, it was also tested against combined vemurafenib plus cobimetinib treatment in a trial including 495 patients [48, 60] and against combined dabrafenib plus trametinib treatment in a trial including 704 patients [58]. The overall response rates to systemic vemurafenib treatment ranged from 45 to 53% [22, 48, 59, 60]. In comparison, the response rate to conventional dacarbazine treatment was only 5% in the study comparing the 2 agents [59]. However, in some cases, vemurafenib had to be applied for up to 6 months until a response manifested. In that study [59], median progression-free survival was 5.3 months for the vemurafenib group compared to 1.6 months for the dacarbazine group, and the 6-month survival rate observed was 84% for the vemurafenib group compared to 64% for the dacarbazine group. Due to the BRAF inhibitor's superiority in that study, a crossover was recommended by the safety and monitoring board. Interestingly, an objective response could be shown for BRAF V600E as well as for V600K subpopulations.

Overall, the median response duration for vemurafenib ranged from 6.2 to 7.5 months [22, 48, 58, 60], and median progression-free survival ranged between 5.3 and 7.3 months [22, 48, 58–60]. Median overall survival was shown to range from 15.9 to 17.4 months, depending on the study [22, 48, 58, 60].

Similar results were obtained for dabrafenib, another selective BRAF inhibitor, showing a benefit of systemic dabrafenib treatment for BRAF-mutated, unresectable stage III or stage IV melanoma of the skin. In a series of stage II and stage III trials, the superiority of dabrafenib treatment over conventional dacarbazine treatment could be demonstrated. In the available studies, dabrafenib was tried either against dacarbazine in a trial including 250 patients [61] or against a combination of dacarbazine plus trametinib in 2 trials including 247 [62] and 423 [63] patients, respectively.

When tested against dacarbazine [61], the objective response rate was 50% in the dabrafenib group versus 6% in the dacarbazine group. Median progression-free sur-

vival was found to be 5.1 months in the dabrafenib group compared to 2.7 months in the dacarbazine group. The estimated median response duration was 5.5 months in the dabrafenib group and was not met in the dacarbazine group.

Overall, the studies at hand showed response rates to dabrafenib between 51 and 54% [62, 63], with a median response duration of 5.6–10.2 months [62, 63] and median progression-free survival of 5.1–8.8 months [61, 63], depending on the study. The median overall survival of patients treated with dabrafenib in these studies was not reached, and the 6-month survival rates were up to 85% [61–63]. As was shown before for vemurafenib, these data demonstrate the superiority of dabrafenib over conventional dacarbazine treatment.

Unfortunately, a common drawback of single-agent MAPK inhibition is the development of resistances, usually occurring within 6–8 months. The driving force behind this is a reactivation of the MAPK pathway that has been shown to occur in different ways. For example, overexpression of the CRAF isoform as well as activating NRAS mutations have been proposed as possible mechanisms for reactivating MAPK signaling and thus limiting the serviceability of BRAF inhibitors [64, 65]. Furthermore, enhanced signaling of the protein kinase COT (cancer Osaka thyroid; also referred to as *tpl-2*, MAP3K8) has been shown to activate ERK independently of Raf, which is positioned further upstream of the signaling cascade. In an *in vitro* study using skin melanoma cells, inhibition of BRAF resulted in elevated levels of COT protein and subsequent ERK phosphorylation, thereby possibly driving MAPK pathway activation [66].

In order to overcome the early development of resistances, combination therapy with BRAF inhibitors plus MEK inhibitors has been proposed. With regard to the combination of vemurafenib plus cobimetinib versus vemurafenib alone [48, 60], as well as of dabrafenib plus trametinib versus dabrafenib alone [62, 63] or vemurafenib alone [58], clear advantages of combination therapy over single-agent BRAF inhibition were demonstrated in the aforementioned trials. For the group treated with vemurafenib plus cobimetinib [48, 60], an objective response rate of 68%, a median response duration of 9.9 months, median progression-free survival of 7.2 months, and median survival of 22.3 months were found.

The groups treated with dabrafenib plus trametinib [58, 62, 63] showed response rates of 64–76% [58, 62, 63], a median response duration of 9.2–13.8 months [58, 62, 63], and median progression-free survival of 9.3–11.4 months [58, 62, 63]; median survival was not reached [58,



62, 63]. A 6-month survival rate of 93% was observed in 1 study [63]. To date, no studies comparing the combination of vemurafenib plus cobimetinib with the combination of dabrafenib plus trametinib have been conducted. When compared to the statistical data acquired for BRAF inhibitor monotherapy, these studies show the superiority of combined BRAF/MEK inhibition therapy over single-agent BRAF inhibitor therapy.

In the case of metastatic or unresectable CM, no standard therapy strategies exist. However, taking into account the described similarities between CM and skin melanoma, and the benefit that combined BRAF/MEK inhibition has brought in the treatment of malignant melanoma of the skin, BRAF/MEK inhibition should logically be the best treatment option in these cases, aiming for the most durable response.

However, clinical experience is still scarce, and only 2 cases where vemurafenib was administered as treatment for CM were described, yielding mixed results. In one case, the patient had metastatic CM, and while tumor regression with relief of symptoms was achieved after 1 month, restaging after the second month revealed partial tumor progression. In the other case, vemurafenib was used to treat nonmetastatic CM in order to avoid exenteration. Here, the disease could be controlled over 16 months until the decrease in tumor size allowed for surgical resection [67, 68].

Additionally, Cao et al. [18] examined the prevalence of activating mutations in the MAPK and AKT (protein kinase B) pathways in benign conjunctival melanocytic lesions, premalignant conjunctival melanocytic lesions, and CM in a total of 129 patients. The study showed that the BRAF V600E mutation could be detected in 19% of the nevi and in 26% of the CM but not in the PAM. In contrast, nuclear and cytoplasmic phosphorylated (p)-ERK as well as nuclear and cytoplasmic p-AKT could be detected immunohistochemically in every group. In order to determine the therapeutic potential of either BRAF, MEK, or AKT inhibition in the treatment of CM, Cao et al. [18] then studied the effects of vemurafenib, dabrafenib, a MEK inhibitor (MEK162), and an AKT inhibitor (MK2206) on 3 CM cell lines. Of these cell lines, 2 displayed a BRAF mutation (CRMM1 and CM2005.1) and 1 had a BRAF wild type (CRMM2). Instead, CRMM2 cells harbored an NRAS mutation. Vemurafenib as well as dabrafenib were able to effectively decrease p-ERK in those cell lines positive for mutated BRAF, while a paradoxical increase was observed in the BRAF wild-type cell line. In the BRAF-mutated cell lines, p-AKT was only slightly decreased by BRAF inhibitors and MEK inhibi-

tors, whereas in the BRAF wild-type cell line, BRAF inhibition led to an upregulation of p-AKT, and MEK inhibition resulted in downregulation of p-AKT. AKT inhibition was able to reduce p-AKT levels in all 3 cell lines.

Treatment with BRAF inhibitors resulted in growth inhibition of the BRAF mutants CRMM1 and CM2005.1, albeit to a different extent, while proliferation of the NRAS-mutated CRMM2 remained unaffected. MEK inhibition as well as AKT inhibition led to growth inhibition in all cell lines in a dose-dependent manner, with AKT inhibitors requiring relatively high doses to effectively inhibit growth. When investigated further, it was shown that in CM2005.1 cells, apoptosis was promoted strongly by BRAF inhibitors, modestly by MEK inhibitors, and only weakly by AKT inhibitors. In the other cell lines, neither drug affected apoptosis induction significantly. Finally, when cells were treated with combined MEK162 plus MK2206, it was revealed that at low doses, the combination treatment led to cell cycle arrest. In light of these results, the general applicability of BRAF/MEK inhibition to metastatic or unresectable CM seems feasible. However, the supposed advantage over alternative treatment option needs to be investigated clinically in further studies.

Other new drugs that have been FDA approved for use in metastatic or unresectable melanoma comprise ipilimumab, a monoclonal antibody directed against T-lymphocyte-associated antigen 4 (CTLA-4) [69], as well as pembrolizumab and nivolumab, 2 monoclonal antibodies directed against the programmed cell death 1 (PD-1) receptor [70, 71].

CTLA-4 and PD-1/PD-1 ligand are present on T lymphocytes and are often dysregulated in the microenvironment of malignant tumors. Notable examples are melanomas and non-small cell lung carcinomas [72, 73]. These proteins function as negative regulators of T-lymphocyte function at different immunological checkpoints. Activation of these receptors in the context of upregulated ligand expression in the tumor microenvironment helps drive the immune escape mechanism of melanoma cells by downregulation of the immune response against the neoplastic lesion [69–74].

The immunotherapeutic agents ipilimumab, nivolumab, and pembrolizumab, also referred to as “checkpoint inhibitors,” work by inhibiting their respective target receptor, thus limiting the cancer cell-induced downregulation of T-cell response. This leads to an increased activation of the immune system, the aim being to eliminate the malignant lesions. All of these checkpoint inhibitors have been shown to significantly prolong progression-free survival compared to conventional chemotherapy in meta-

static melanoma [69–71, 74–76]. However, in the case of ipilimumab, response rates are relatively low. In one trial including 945 patients, nivolumab treatment was tested against nivolumab plus ipilimumab and ipilimumab alone [77]. The study showed objective response rates of 43.7% in the nivolumab group versus 57.6% in the combination group and 19% in the ipilimumab group. Interestingly, the response rates were 57.5% in the PD-1 ligand-positive subgroup of the nivolumab group versus 41.3% in the PD-1 ligand-negative subgroup.

In another trial including 279 patients who received either pembrolizumab every 2 weeks or every 3 weeks or ipilimumab treatment, the objective response rates to pembrolizumab every 2 and every 3 weeks were 33.7 and 32.9%, respectively [71]. For ipilimumab, an objective response rate of 11.9% was found. Here, a subgroup analysis examining the impact of PD-1 ligand expression was not conducted.

In order to determine the applicability of checkpoint inhibitors to metastatic CM, clinical studies have to be conducted trying these drugs against conventional chemotherapy and, possibly, BRAF/MEK inhibition in patients with CM. Furthermore, biological markers predicting a successful response have to be found. So far, the expression of PD-1 ligand in melanoma cells has been suggested as an indicator predicting response to PD-1-directed therapy [78]. However, this does not necessarily have to apply to CM and needs to be supported by clinical evidence.

Finally, mTOR (mammalian target of rapamycin) inhibition has been proposed as a new treatment option in CM, due to the fact that tumors commonly harbor mutations of the mTOR pathway [79].

### Adverse Effects

Systemic BRAF inhibitor therapy has a list of well-documented side effects. These encompass arthralgia, rash, photosensitivity reactions and pruritus, hyperkeratosis, fatigue, alopecia, nausea, vomiting, diarrhea, pyrexia, elevation of liver enzymes, facial nerve paralysis, retinal vein occlusions, QT interval prolongation, and elevation of creatinine kinase enzyme (the last, however, being more common in MEK inhibitor treatment). Another side effect of BRAF inhibitors that requires special mentioning is the development of keratoacanthomas and squamous cell carcinomas of the skin in up to 26% of patients. These develop most likely because of paradoxical upregulation of the MAPK pathway in BRAF wild-type cells harboring Ras mutations upstream of B-raf. Gener-

ally, these secondary tumors can be dealt with by simple excision [22, 48, 62, 63, 80, 81].

Common adverse effects of MEK inhibitors include elevation of creatinine kinase, nausea, vomiting, diarrhea, constipation, rash, fatigue, edema, acneiform dermatitis, alopecia, hypertension, and a decreased ejection fraction [58, 62, 63, 82].

While under BRAF/MEK inhibitor combination therapy, adverse events occurred more frequently than under single-agent therapy across most trials [48, 58, 60, 62, 63], the rate of grade III or IV events has still been shown to be low for monotherapy as well as for combination therapy. Markedly, higher rates of gastrointestinal side effects, photosensitivity, chorioretinopathy, and retinal detachment have been demonstrated in the combination groups [48, 58, 62, 63]. Nonetheless, combination therapy was repeatedly proven to be superior in regard to the development of secondary skin tumors. Under combined BRAF/MEK inhibition, development of keratoacanthoma or squamous cell carcinoma of the skin was significantly lower than under BRAF inhibitor monotherapy in every study. Thus, combination therapy shows another distinct advantage over monotherapy in regard to adverse effects [48, 58, 62, 63].

### Future Perspectives

With recent advances in targeted therapies, there has been a leap forward in the treatment of skin melanoma, supported by evidence gained from various clinical trials. However, there is a lack of extensive studies on CM, owing to the fact that CM is a very rare malignancy. Since there seems to be a genetic and phenotypical relation between the 2 entities, therapies that have proven advantageous for skin melanoma must be further investigated concerning their applicability to CM. So far, the evidence suggests that BRAF inhibitors in combination with MEK inhibitors could become the treatment option of choice for unresectable or metastatic CM. Nevertheless, many more questions arise: what is the optimal dosis? What is the optimal route of application? Which agent should be used? Where to go next after progression? Alternative options that are on the horizon include PD-1 inhibition as well as CTLA-4 inhibition. Furthermore, scanning for BRAF mutations in order to determine a tumor's genetic profile seems like the logical next step to be included in the histopathological workup of CM. In the future, experimental and clinical studies will have to provide answers to these questions.

## Statement of Ethics

The authors declare no ethical conflicts.

## Disclosure Statement

The authors declare no conflict of interest.

## References

- 1 Hu DN, Yu G, McCormick SA, Finger PT: Population-based incidence of conjunctival melanoma in various races and ethnic groups and comparison with other melanomas. *Am J Ophthalmol* 2008;145:418–423.
- 2 Triay E, Bergman L, Nilsson B, All-Ericsson C, Seregard S: Time trends in the incidence of conjunctival melanoma in Sweden. *Br J Ophthalmol* 2009;93:1524–1528.
- 3 Isager P, Østerlind A, Engholm G, Heegaard S, Lindegaard J, Overgaard J, Storm HH: Uveal and conjunctival malignant melanoma in Denmark, 1943–97: incidence and validation study. *Ophthalmic Epidemiol* 2005;12:223–232.
- 4 Norregaard JC, Gerner N, Jensen OA, Prause JU: Malignant melanoma of the conjunctiva: occurrence and survival following surgery and radiotherapy in a Danish population. *Graefes Arch Clin Exp Ophthalmol* 1996;234:569–572.
- 5 Seregard S, Kock E: Conjunctival malignant melanoma in Sweden 1969–91. *Acta Ophthalmol (Copenh)* 1992;70:289–296.
- 6 Missotten GS, Keijser S, De Keizer RJ, De Wolff-Rouendaal D: Conjunctival melanoma in the Netherlands: a nationwide study. *Invest Ophthalmol Vis Sci* 2005;46:75–82.
- 7 Werschnik C, Lommatzsch PK: Long-term follow-up of patients with conjunctival melanoma. *Am J Clin Oncol* 2002;25:248–255.
- 8 Esmaeli B, Wang X, Youssef A, Gershenwald JE: Patterns of regional and distant metastasis in patients with conjunctival melanoma: experience at a cancer center over four decades. *Ophthalmology* 2001;108:2101–2105.
- 9 Shields CL, Shields JA, Gündüz K, Cater J, Mercado GV, Gross N, Lally B: Conjunctival melanoma: risk factors for recurrence, exenteration, metastasis, and death in 150 consecutive patients. *Arch Ophthalmol* 2000;118:1497–1507.
- 10 Shields CL, Markowitz JS, Belinsky I, Schwartzstein H, George NS, Lally SE, Mashayekhi A, Shields JA: Conjunctival melanoma: outcomes based on tumor origin in 382 consecutive cases. *Ophthalmology* 2011;118:389–395.
- 11 Griewank KG, Westkemper H, Murali R, Mach M, Schilling B, Wiesner T, Schimming T, Livingstone E, Sucker A, Grabellus F, Metz C, Süßkind D, Hillen U, Speicher MR, Woodman SE, Steuhl KP, Schadendorf D: Conjunctival melanomas harbor *BRAF* and *NRAS* mutations and copy number changes similar to cutaneous and mucosal melanomas. *Clin Cancer Res* 2013;19:3143–3152.
- 12 Damato B, Coupland SE: Conjunctival melanoma and melanosis: a reappraisal of terminology, classification and staging. *Clin Exp Ophthalmol* 2008;36:786–795.
- 13 Jakobiec FA: Conjunctival primary acquired melanosis: is it time for a new terminology? *Am J Ophthalmol* 2016;162:3–19.e1.
- 14 Yu GP, Hu DN, McCormick S, Finger PT: Conjunctival melanoma: is it increasing in the United States? *Am J Ophthalmol* 2003;135:800–806.
- 15 Leiter U, Garbe C: Epidemiology of melanoma and nonmelanoma skin cancer – the role of sunlight. *Adv Exp Med Biol* 2008;624:89–103.
- 16 Larsen AC, Dahl C, Dahmcke CM, Lade-Keller J, Siersma VD, Toft PB, Coupland SE, Prause JU, Guldberg P, Heegaard S: *BRAF* mutations in conjunctival melanoma: investigation of incidence, clinicopathological features, prognosis and paired premalignant lesions. *Acta Ophthalmol* 2016;94:463–470.
- 17 Maldonado JL, Fridlyand J, Patel H, Jain AN, Busam K, Kageshita T, Ono T, Albertson DG, Pinkel D, Bastian BC: Determinants of *BRAF* mutations in primary melanomas. *J Natl Cancer Inst* 2003;95:1878–1890.
- 18 Cao J, Heijkants RC, Jochemsen AG, Dogrusöz M, de Lange MJ, van der Velden PA, van der Burg SH, Jager MJ, Verdijk RM: Targeting of the MAPK and AKT pathways in conjunctival melanoma shows potential synergy. *Oncotarget* 2016, Epub ahead of print.
- 19 Hacker E, Hayward NK, Dumenil T, James MR, Whiteman DC: The association between *MC1R* genotype and *BRAF* mutation status in cutaneous melanoma: findings from an Australian population. *J Invest Dermatol* 2010;130:241–248.
- 20 Goydos JS, Mann B, Kim HJ, Gabriel EM, Alsinia J, Germino FJ, Shih W, Gorski DH: Detection of *B-RAF* and *N-RAS* mutations in human melanoma. *J Am Coll Surg* 2005;200:362–370.
- 21 Long GV, Menzies AM, Nagrial AM, Haydu LE, Hamilton AL, Mann GJ, Hughes TM, Thompson JF, Scolyer RA, Kefford RF: Prognostic and clinicopathologic associations of oncogenic *BRAF* in metastatic melanoma. *J Clin Oncol* 2011;29:1239–1246.
- 22 Sosman JA, Kim KB, Schuchter L, Gonzalez R, Pavlick AC, Weber JS, McArthur GA, Hutson TE, Moschos SJ, Flaherty KT, Hersey P, Kefford R, Lawrence D, Puzanov I, Lewis KD, Amaravadi RK, Chmielowski B, Lawrence HJ, Shyr Y, Ye F, Li J, Nolop KB, Lee RJ, Joe AK, Ribas A: Survival in *BRAF* V600-mutant advanced melanoma treated with vemurafenib. *N Engl J Med* 2012;366:707–714.
- 23 Lake SL, Jmor F, Dopierala J, Taktak AF, Coupland SE, Damato BE: Multiplex ligation-dependent probe amplification of conjunctival melanoma reveals common *BRAF* V600E gene mutation and gene copy number changes. *Invest Ophthalmol Vis Sci* 2011;52:5598–5604.
- 24 Cohen Y, Goldenberg-Cohen N, Parrella P, Chowers I, Merbs SL, Pe'er J, Sidransky D: Lack of *BRAF* mutation in primary uveal melanoma. *Invest Ophthalmol Vis Sci* 2003;44:2876–2878.
- 25 Edmunds SC, Cree IA, Dí Nicolantonio F, Hungerford JL, Hurren JS, Kelsell DP: Absence of *BRAF* gene mutations in uveal melanomas in contrast to cutaneous melanomas. *Br J Cancer* 2003;88:1403–1405.
- 26 Spendlove HE, Damato BE, Humphreys J, Barker KT, Hiscott PS, Houlston RS: *BRAF* mutations are detectable in conjunctival but not uveal melanomas. *Melanoma Res* 2004;14:449–452.
- 27 Heindl LM, Hofmann TN, Knorr HL, Rummelt C, Schrödl F, Schlötzer-Schrehardt U, Holbach LM, Naumann GO, Kruse FE, Cursiefen C: Intraocular lymphangiogenesis in malignant melanomas of the ciliary body with extraocular extension. *Invest Ophthalmol Vis Sci* 2009;50:1988–1995.
- 28 Bedrosian I, Faries MB, Guerry D 4th, Elenitsas R, Schuchter L, Mick R, Spitz FR, Bucky LP, Alavi A, Elder DE, Fraker DL, Czerniecki BJ: Incidence of sentinel node metastasis in patients with thin primary melanoma (< or = 1 mm) with vertical growth phase. *Ann Surg Oncol* 2000;7:262–267.
- 29 Refaian N, Schlereth SL, Koch KR, Notara M, Hos D, Mescher M, Iden S, Bosch JJ, Jager MJ, Cursiefen C, Heindl LM: Comparing the hem- and lymphangiogenic profile of conjunctival and uveal melanoma cell lines. *Invest Ophthalmol Vis Sci* 2015;56:5691–5697.
- 30 Heindl LM, Hofmann TN, Adler W, Knorr HL, Holbach LM, Naumann GO, Kruse FE, Cursiefen C: Intraocular tumor-associated lymphangiogenesis a novel prognostic factor for ciliary body melanomas with extraocular extension? *Ophthalmology* 2010;117:334–342.
- 31 Heindl LM, Hofmann-Rummelt C, Adler W, Bosch JJ, Holbach LM, Naumann GO, Kruse FE, Cursiefen C: Prognostic significance of tumor-associated lymphangiogenesis in malignant melanomas of the conjunctiva. *Ophthalmology* 2011;118:2351–2360.



- 32 Heindl LM, Hofmann-Rummelt C, Adler W, Bosch JJ, Holbach LM, Naumann GO, Kruse FE, Cursiefen C: Tumor-associated lymphangiogenesis in the development of conjunctival melanoma. *Invest Ophthalmol Vis Sci* 2011; 52:7074–7083.
- 33 Schlereth SL, Iden S, Mescher M, Ksander BR, Bosch JJ, Cursiefen C, Heindl LM: A novel model of metastatic conjunctival melanoma in immune-competent mice. *Invest Ophthalmol Vis Sci* 2015;56:5965–5973.
- 34 Iwamoto S, Burrows RC, Grossniklaus HE, Orcutt J, Kalina RE, Boehm M, Bothwell MA, Schmidt R: Immunophenotype of conjunctival melanomas: comparison with uveal and cutaneous melanomas. *Arch Ophthalmol* 2002;120:1625–1629.
- 35 Díaz-Lagares A, Alegre E, Arroyo A, González-Cao M, Zudaire ME, Viteri S, Martín-Algarra S, González A: Evaluation of multiple serum markers in advanced melanoma. *Tumour Biol* 2011;32:1155–1161.
- 36 Iwamoto S, Burrows RC, Kalina RE, George D, Boehm M, Bothwell MA, Schmidt R: Immunophenotypic differences between uveal and cutaneous melanomas. *Arch Ophthalmol* 2002;120:466–470.
- 37 Stadelmeyer E, Heitzer E, Resel M, Cerroni L, Wolf P, Dandachi N: The *BRAF* V600K mutation is more frequent than the *BRAF* V600E mutation in melanoma in situ of lentigo maligna type. *J Invest Dermatol* 2014;134:548–550.
- 38 Bratton EM, Knutsen-Larson S, Durairaj VD, Gregory DG, Mellette JR: Combination topical therapy for conjunctival primary acquired melanosis with atypia and periocular lentigo maligna. *Cornea* 2015;34:90–93.
- 39 Finger PT: Cryotherapy of conjunctival melanoma. *Ophthalmology* 1993;100:1429.
- 40 Damato B, Coupland SE: An audit of conjunctival melanoma treatment in Liverpool. *Eye (Lond)* 2009;23:801–809.
- 41 Westekemper H, Meller D, Darawsha R, Scholz SL, Flühs D, Steuhl KP, Héroult J, Thariat J, Sauerwein W: Operative therapy and irradiation of conjunctival melanoma (in German). *Ophthalmologie* 2015;112:899–900, 902–906.
- 42 Heindl LM, Koch KR, Schlaak M, Mauch C, Cursiefen C: Adjuvant therapy and interdisciplinary follow-up care of conjunctival melanoma (in German). *Ophthalmologie* 2015; 112:907–911.
- 43 Shields JA, Shields CL, De Potter P: Surgical management of conjunctival tumors. The 1994 Lynn B McMahan Lecture. *Arch Ophthalmol* 1997;115:808–815.
- 44 Russell HC, Chadha V, Lockington D, Kemp EG: Topical mitomycin C chemotherapy in the management of ocular surface neoplasia: a 10-year review of treatment outcomes and complications. *Br J Ophthalmol* 2010;94: 1316–1321.
- 45 Herold TR, Hintschich C: Interferon  $\alpha$  for the treatment of melanocytic conjunctival lesions. *Graefes Arch Clin Exp Ophthalmol* 2009;248:111–115.
- 46 Hos D, Schlereth SL, Bock F, Heindl LM, Cursiefen C: Antilymphangiogenic therapy to promote transplant survival and to reduce cancer metastasis: what can we learn from the eye? *Semin Cell Dev Biol* 2015;38:117–130.
- 47 Krause L, Mladenova A, Bechrakis NE, Kreusel KM, Plath T, Moser L, Foerster M: Treatment modalities for conjunctival melanoma (in German). *Klin Monbl Augenheilkd* 2009; 226:1012–1016.
- 48 Larkin J, Ascierto PA, Dréno B, Atkinson V, Liskay G, Maio M, Mandalà M, Demidov L, Stroyakovskiy D, Thomas L, de la Cruz-Merino L, Dutriaux C, Garbe C, Sovak MA, Chang I, Choong N, Hack SP, McArthur GA, Ribas A: Combined vemurafenib and cobimetinib in *BRAF*-mutated melanoma. *N Engl J Med* 2014;371:1867–1876.
- 49 Cohen C, Zavala-Pompa A, Sequeira JH, Shoji M, Sexton DG, Cotsonis G, Cerimele F, Govindarajan B, Macaron N, Arbiser JL: Mitogen-activated protein kinase activation is an early event in melanoma progression. *Clin Cancer Res* 2002;8:3728–3733.
- 50 Wellbrock C, Arozarena I: The complexity of the ERK/MAP-kinase pathway and the treatment of melanoma skin cancer. *Front Cell Dev Biol* 2016;4:33.
- 51 Hacker E, Olsen CM, Kvaskoff M, Pandeya N, Yeo A, Green AC, Williamson RM, Triscott J, Wood D, Mortimore R, Hayward NK, Whitehead DC: Histologic and phenotypic factors and *MC1R* status associated with *BRAF*<sup>V600E</sup>, *BRAF*<sup>V600K</sup>, and *NRAS* mutations in a community-based sample of 414 cutaneous melanomas. *J Invest Dermatol* 2016;136:829–837.
- 52 Larsen AC: Conjunctival malignant melanoma in Denmark: epidemiology, treatment and prognosis with special emphasis on tumorigenesis and genetic profile. *Acta Ophthalmol* 2016;94(thesis 1):1–27.
- 53 Larsen AC, Dahmcke CM, Dahl C, Siersma VD, Toft PB, Coupland SE, Prause JU, Guldberg P, Heegaard S: A retrospective review of conjunctival melanoma presentation, treatment, and outcome and an investigation of features associated with *BRAF* mutations. *JAMA Ophthalmol* 2015;133:1295–1303.
- 54 Gear H, Williams H, Kemp EG, Roberts F: *BRAF* mutations in conjunctival melanoma. *Invest Ophthalmol Vis Sci* 2004;45:2484–2488.
- 55 Macerola E, Loggini B, Giannini R, Garavello G, Giordano M, Proietti A, Niccoli C, Basolo F, Fontanini G: Coexistence of *TERT* promoter and *BRAF* mutations in cutaneous melanoma is associated with more clinicopathological features of aggressiveness. *Virchows Arch* 2015;467:177–184.
- 56 Edlundh-Rose E, Eghyázi S, Omholt K, Månsson-Brahme E, Platz A, Hansson J, Lundeberg J: *NRAS* and *BRAF* mutations in melanoma tumours in relation to clinical characteristics: a study based on mutation screening by pyrosequencing. *Melanoma Res* 2006;16:471–478.
- 57 Pollock PM, Harper UL, Hansen KS, Yudit LM, Stark M, Robbins CM, Moses TY, Hostet-
- ter G, Wagner U, Kakareka J, Salem G, Pohida T, Heenan P, Duray P, Kallioniemi O, Hayward NK, Trent JM, Meltzer PS: High frequency of *BRAF* mutations in nevi. *Nat Genet* 2003;33:19–20.
- 58 Robert C, Karaszewska B, Schachter J, Rutkowski P, Mackiewicz A, Stroiakovski D, Lichinitser M, Dummer R, Grange F, Mortier L, Chiarion-Sileni V, Drucis K, Krajsova I, Hauschild A, Lorigan P, Wolter P, Long GV, Flaherty K, Nathan P, Ribas A, Martin AM, Sun P, Crist W, Legos J, Rubin SD, Little SM, Schadendorf D: Improved overall survival in melanoma with combined dabrafenib and trametinib. *N Engl J Med* 2015;372:30–39.
- 59 Chapman PB, Hauschild A, Robert C, Haanen JB, Ascierto P, Larkin J, Dummer R, Garbe C, Testori A, Maio M, Hogg D, Lorigan P, Lebbe C, Jouary T, Schadendorf D, Ribas A, O'Day SJ, Sosman JA, Kirkwood JM, Eggermont AM, Dreno B, Nolop K, Li J, Nelson B, Hou J, Lee RJ, Flaherty KT, McArthur GA: Improved survival with vemurafenib in melanoma with *BRAF* V600E mutation. *N Engl J Med* 2011; 364:2507–2516.
- 60 Ascierto PA, McArthur GA, Dréno B, Atkinson V, Liskay G, Di Giacomo AM, Mandalà M, Demidov L, Stroyakovskiy D, Thomas L, de la Cruz-Merino L, Dutriaux C, Garbe C, Yan Y, Wongchenko M, Chang I, Hsu JJ, Koralek DO, Rooney I, Ribas A, Larkin J: Cobimetinib combined with vemurafenib in advanced *BRAF*<sup>V600</sup>-mutant melanoma (coBRIM): updated efficacy results from a randomised, double-blind, phase 3 trial. *Lancet Oncol* 2016;17:1248–1260.
- 61 Hauschild A, Grob JJ, Demidov LV, Jouary T, Gutzmer R, Millward M, Rutkowski P, Blank CU, Miller WH Jr, Kaempgen E, Martín-Algarra S, Karaszewska B, Mauch C, Chiarion-Sileni V, Martin AM, Swann S, Haney P, Mirakhur B, Guckert ME, Goodman V, Chapman PB: Dabrafenib in *BRAF*-mutated metastatic melanoma: a multicentre, open-label, phase 3 randomised controlled trial. *Lancet* 2012;380:358–365.
- 62 Flaherty KT, Infante JR, Daud A, Gonzalez R, Kefford RF, Sosman J, Hamid O, Schuchter L, Cebon J, Ibrahim N, Kudchadkar R, Burris HA 3rd, Falchook G, Algazi A, Lewis K, Long GV, Puzanov I, Lebowitz P, Singh A, Little S, Sun P, Allred A, Ouellet D, Kim KB, Patel K, Weber J: Combined *BRAF* and *MEK* inhibition in melanoma with *BRAF* V600 mutations. *N Engl J Med* 2012;367:1694–1703.
- 63 Long GV, Stroyakovskiy D, Gogas H, Levchenko E, de Braud F, Larkin J, Garbe C, Jouary T, Hauschild A, Grob JJ, Chiarion-Sileni V, Lebbe C, Mandalà M, Millward M, Arance A, Bondarenko I, Haanen JB, Hansson J, Uital J, Ferraresi V, Kovalenko N, Mohr P, Probsthai V, Schadendorf D, Nathan P, Robert C, Ribas A, DeMarini DJ, Irani JG, Casey M, Ouellet D, Martin AM, Le N, Patel K, Flaherty K: Combined *BRAF* and *MEK* inhibition versus *BRAF* inhibition alone in melanoma. *N Engl J Med* 2014;371:1877–1888.



- 64 Nazarian R, Shi H, Wang Q, Kong X, Koya RC, Lee H, Chen Z, Lee MK, Attar N, Sazegar H, Chodon T, Nelson SF, McArthur G, Sosman JA, Ribas A, Lo RS: Melanomas acquire resistance to B-RAF(V600E) inhibition by RTK or N-RAS upregulation. *Nature* 2010; 468:973–977.
- 65 Montagut C, Sharma SV, Shioda T, McDermott U, Ulman M, Ulkus LE, Dias-Santagata D, Stubbs H, Lee DY, Singh A, Drew L, Habet DA, Settleman J: Elevated CRAF as a potential mechanism of acquired resistance to BRAF inhibition in melanoma. *Cancer Res* 2008;68: 4853–4861.
- 66 Johannessen CM, Boehm JS, Kim SY, Thomas SR, Wardwell L, Johnson LA, Emery CM, Stransky N, Cogdill AP, Barretina J, Caponigro G, Hieronymus H, Murray RR, Salehi-Ashtiani K, Hill DE, Vidal M, Zhao JJ, Yang X, Alkan O, Kim S, Harris JL, Wilson CJ, Myer VE, Finan PM, Root DE, Roberts TM, Golub T, Flaherty KT, Dummer R, Weber BL, Sellers WR, Schlegel R, Wargo JA, Hahn WC, Garraway LA: COT drives resistance to RAF inhibition through MAP kinase pathway reactivation. *Nature* 2010;468:968–972.
- 67 Weber JL, Smalley KS, Sondak VK, Gibney GT: Conjunctival melanomas harbor BRAF and NRAS mutations – letter. *Clin Cancer Res* 2013;19:6329–6330.
- 68 Pahlitzsch M, Bertelmann E, Mai C: Conjunctival melanoma and BRAF inhibitor therapy. *J Clin Exp Ophthalmol* 2014;5:322.
- 69 Hodi FS, O’Day SJ, McDermott DF, Weber RW, Sosman JA, Haanen JB, Gonzalez R, Robert C, Schadendorf D, Hassel JC, Akerley W, van den Eertwegh AJ, Lutzky J, Lorigan P, Vaubel JM, Linette GP, Hogg D, Ottensmeier CH, Lebbé C, Peschel C, Quirt I, Clark JI, Wolchok JD, Weber JS, Tian J, Yellin MJ, Nichol GM, Hoos A, Urba WJ: Improved survival with ipilimumab in patients with metastatic melanoma. *N Engl J Med* 2010;363:711–723.
- 70 Robert C, Long GV, Brady B, Dutriaux C, Maio M, Mortier L, Hassel JC, Rutkowski P, McNeil C, Kalinka-Warzocha E, Savage KJ, Hernberg MM, Lebbé C, Charles J, Mihalcioiu C, Chiarion-Sileni V, Mauch C, Cognetti F, Arance A, Schmidt H, Schadendorf D, Gogas H, Lundgren-Eriksson L, Horak C, Sharkey B, Waxman IM, Atkinson V, Ascierto PA: Nivolumab in previously untreated melanoma without BRAF mutation. *N Engl J Med* 2015;372:320–330.
- 71 Robert C, Schachter J, Long GV, Arance A, Grob JJ, Mortier L, Daud A, Carlino MS, McNeil C, Lotem M, Larkin J, Lorigan P, Neyns B, Blank CU, Hamid O, Mateus C, Shapira-Frommer R, Kosh M, Zhou H, Ibrahim N, Ebbinghaus S, Ribas A; KEYNOTE-006 Investigators: Pembrolizumab versus ipilimumab in advanced melanoma. *N Engl J Med* 2015;372:2521–2532.
- 72 Chevolet I, Speeckaert R, Schreuer M, Neyns B, Krysko O, Bachert C, Hennart B, Allorge D, van Geel N, Van Gele M, Brochez L: Characterization of the in vivo immune network of IDO, tryptophan metabolism, PD-L1, and CTLA-4 in circulating immune cells in melanoma. *Oncoimmunology* 2015;4:e982382.
- 73 Lou Y, Diao L, Cuentas ER, Denning WL, Chen L, Fan YH, Byers LA, Wang J, Papadimitrakopoulou VA, Behrens C, Rodriguez JC, Hwu P, Wistuba II, Heymach JV, Gibbons DL: Epithelial-mesenchymal transition is associated with a distinct tumor microenvironment including elevation of inflammatory signals and multiple immune checkpoints in lung adenocarcinoma. *Clin Cancer Res* 2016; 22:3630–3642.
- 74 Buchbinder EI, Desai A: CTLA-4 and PD-1 pathways: similarities, differences, and implications of their inhibition. *Am J Clin Oncol* 2016;39:98–106.
- 75 Robert C, Thomas L, Bondarenko I, O’Day S, Weber J, Garbe C, Lebbe C, Baurain JF, Testori A, Grob JJ, Davidson N, Richards J, Maio M, Hauschild A, Miller WH Jr, Gascon P, Lotem M, Harmankaya K, Ibrahim R, Francis S, Chen TT, Humphrey R, Hoos A, Wolchok JD: Ipilimumab plus dacarbazine for previously untreated metastatic melanoma. *N Engl J Med* 2011;364:2517–2526.
- 76 Lin Z, Chen X, Li Z, Luo Y, Fang Z, Xu B, Han M: PD-1 antibody monotherapy for malignant melanoma: a systematic review and meta-analysis. *PLoS One* 2016;11:e0160485.
- 77 Larkin J, Chiarion-Sileni V, Gonzalez R, Grob JJ, Cowey CL, Lao CD, Schadendorf D, Dummer R, Smylie M, Rutkowski P, Ferrucci PF, Hill A, Wagstaff J, Carlino MS, Haanen JB, Maio M, Marquez-Rodas I, McArthur GA, Ascierto PA, Long GV, Callahan MK, Postow MA, Grossmann K, Sznol M, Dreno B, Bastholt L, Yang A, Rollin LM, Horak C, Hodi FS, Wolchok JD: Combined nivolumab and ipilimumab or monotherapy in untreated melanoma. *N Engl J Med* 2015;373:23–34.
- 78 Mahoney KM, Atkins MB: Prognostic and predictive markers for the new immunotherapies. *Oncology (Williston Park)* 2014; 28(suppl 3):39–48.
- 79 Pópulo H, Soares P, Rocha AS, Silva P, Lopes JM: Evaluation of the mTOR pathway in ocular (uvea and conjunctiva) melanoma. *Melanoma Res* 2010;20:107–117.
- 80 Flaherty KT, Robert C, Hersey P, Nathan P, Garbe C, Milhem M, Demidov LV, Hassel JC, Rutkowski P, Mohr P, Dummer R, Trefzer U, Larkin JM, Utikal J, Dreno B, Nyakas M, Middleton MR, Becker JC, Casey M, Sherman LJ, Wu FS, Ouellet D, Martin AM, Patel K, Schadendorf D; METRIC Study Group: Improved survival with MEK inhibition in BRAF-mutated melanoma. *N Engl J Med* 2012;367:107–114.
- 81 Su F, Viros A, Milagre C, Trunzer K, Bollag G, Spleiss O, Reis-Filho JS, Kong X, Koya RC, Flaherty KT, Chapman PB, Kim MJ, Hayward R, Martin M, Yang H, Wang Q, Hilton H, Hang JS, Noe J, Lambros M, Geyer F, Dhomen N, Niculescu-Duvaz I, Zambon A, Niculescu-Duvaz D, Preece N, Robert L, Otte NJ, Mok S, Kee D, Ma Y, Zhang C, Habets G, Burton EA, Wong B, Nguyen H, Kockx M, Andries L, Lestini B, Nolop KB, Lee RJ, Joe AK, Troy JL, Gonzalez R, Hutson TE, Puza-nov I, Chmielowski B, Springer CJ, McArthur GA, Sosman JA, Lo RS, Ribas A, Marais R: RAS mutations in cutaneous squamous-cell carcinomas in patients treated with BRAF inhibitors. *N Engl J Med* 2012;366:207–215.
- 82 Hoefflich KP, Merchant M, Orr C, Chan J, Den Otter D, Berry L, Kasman I, Koeppen H, Rice K, Yang NY, Engst S, Johnston S, Friedman LS, Belvin M: Intermittent administration of MEK inhibitor GDC-0973 plus PI3K inhibitor GDC-0941 triggers robust apoptosis and tumor growth inhibition. *Cancer Res* 2012;72: 210–219.