

Original Paper

## Eosinophilic Cystitis Presented as a Manifestation of Hypereosinophilic Syndrome: A Case Report and Review of the Literature

Katsuaki Kojima<sup>a</sup> Jun Maeda<sup>a</sup> Shuji Mikami<sup>c</sup> Hiroyuki Yamagishi<sup>a</sup>  
Hiroki Ide<sup>b</sup> Seiya Hattori<sup>b</sup> Takao Takahashi<sup>a</sup> Midori Awazu<sup>a</sup>

Departments of <sup>a</sup>Pediatrics and <sup>b</sup>Urology, School of Medicine, Keio University, and  
<sup>c</sup>Division of Diagnostic Pathology, Keio University Hospital, Tokyo, Japan

### Key Words

Eosinophilic cystitis · Hypereosinophilic syndrome · Urethral stricture

### Abstract

**Background:** Hypereosinophilic syndrome (HES) is a group of disorders marked by the sustained overproduction of eosinophils, in which eosinophilic infiltration and inflammatory substance release cause damage to multiple organs. Eosinophilic cystitis (EC) is an inflammatory disorder caused by eosinophilic infiltration of the bladder wall. Although EC is often associated with eosinophilia, it has been rarely reported as a manifestation of HES. We report a case of EC as a primary manifestation of HES. The patient was a 27-year-old male with a history of complete intracardiac repair of tetralogy of Fallot who presented with an acute onset of dysuria accompanied by eosinophilia ( $7.5 \times 10^3/\mu\text{l}$ , 60% of white blood cells). Ultrasonography and MRI of the bladder showed a bladder mass, a biopsy of which revealed eosinophilic infiltration and degranulation. **Methods:** We performed a literature search in PubMed from 2001 to 2012 to find patients with EC who may have had HES. **Results:** There were 4 patients with HES who had EC including the present case. Of 14 patients reported as EC in whom the eosinophil count was described, 5 had eosinophils of  $\geq 1,500/\mu\text{l}$ . None of the 5 patients had secondary causes for eosinophilia. Of the 9 patients with definite or probable HES, 7 patients (78%) were male and 5 patients (56%) showed a concomitant eosinophilic gastrointestinal disorder. **Conclusion:** HES may not be uncommon as the cause of EC. Thorough evaluation and close monitoring are warranted in EC patients with elevated eosinophils.

Copyright © 2013 S. Karger AG, Basel

Midori Awazu, MD  
Department of Pediatrics, School of Medicine  
Keio University, 35 Shinanomachi  
Shinjuku-ku, Tokyo 160-8582 (Japan)  
E-Mail [awazu@z3.keio.jp](mailto:awazu@z3.keio.jp)

## Introduction

Hypereosinophilic syndrome (HES) is a condition characterized by eosinophilia and multiple organ damage. The definition of HES was originally introduced in 1975 [1]: persistent eosinophilia of  $\geq 1,500/\mu\text{l}$  for longer than 6 months, lack of evidence for parasitic, allergic or other known causes of eosinophilia, and presumptive signs and symptoms of organ involvement, including hepatosplenomegaly, heart murmur, congestive heart failure, diffuse or focal nervous system abnormalities, pulmonary fibrosis, fever, weight loss, and anemia. Recently, the following new criteria have been proposed: blood eosinophilia of  $\geq 1,500/\mu\text{l}$  present on at least two occasions with no other apparent etiologies for the degree of eosinophilia such as those listed above as well as viral infections, hypoadrenalism, and neoplasms [2].

Eosinophilic cystitis (EC) is an inflammatory disorder caused by eosinophilic infiltration of the bladder wall. Many etiologies have been proposed, such as allergy, asthma, transitional cell carcinoma of the bladder, recurrent urinary tract infection, benign prostatic hyperplasia, and intravesical instillation of mitomycin C or tranilast. Most patients have a benign course with spontaneous resolution.

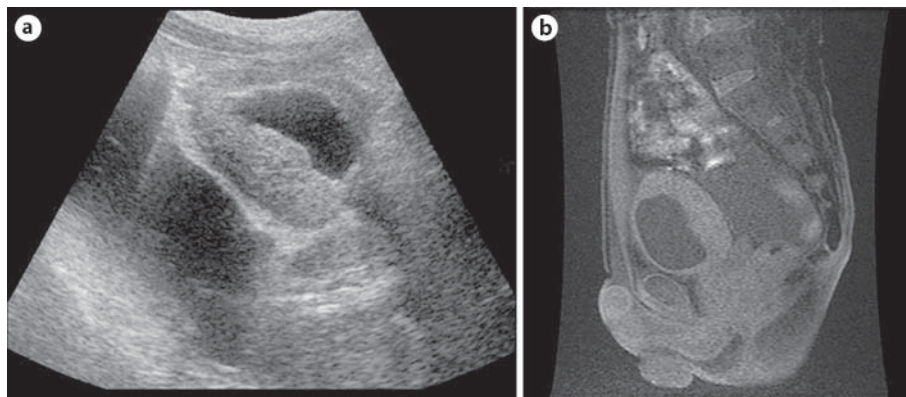
We report a patient with EC as a manifestation of HES. This is the first case of HES which presented only as EC. We also searched the literature published from 2001 to 2012 and reviewed the clinical characteristics of patients with EC who had or may have had HES.

## Materials and Methods

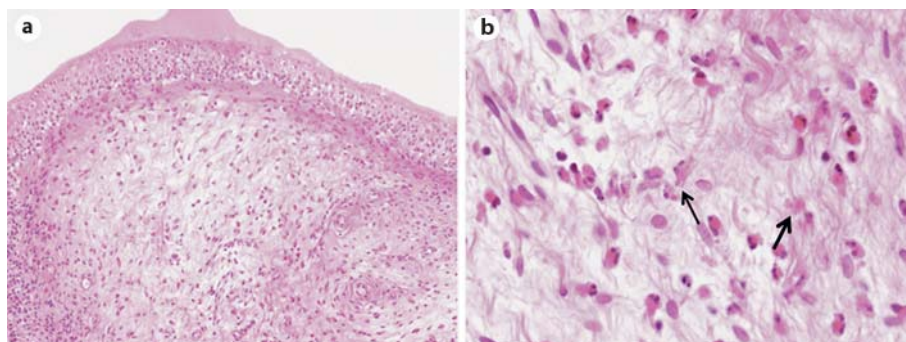
We searched PubMed using the search terms ‘eosinophilic cystitis’ and ‘hypereosinophilic syndrome, and cystitis or bladder’. We included case reports of EC without an apparent cause and reported peripheral eosinophil counts. Cases of HES that had cystitis were also included.

## Case Report

A 27-year-old man with a history of complete intracardiac repair of tetralogy of Fallot presented with a sudden onset of dysuria and suprapubic tenderness followed by gross hematuria. He was taking hydrochlorothiazide, spironolactone, ubidecarenone, and digoxin for congestive heart failure. He reported a history of chronic sinusitis but denied any history of food or drug allergy. On physical examination, temperature was  $37.1^{\circ}\text{C}$ , blood pressure 121/61 mm Hg, heart rate 85 beats/min, height 170.6 cm, and weight 48.2 kg. Ears, nose, and throat were unremarkable. He had distention of the jugular veins. The lungs were clear. Cardiac examination revealed a loud second heart sound and grade V systolic heart murmur over the left middle sternal border. The abdomen was soft without palpable masses. Suprapubic tenderness was present. Laboratory studies showed hemoglobin of 13.5 g/dl, white blood cell count of  $12.6 \times 10^3/\mu\text{l}$  with 60% eosinophils ( $7.5 \times 10^3/\mu\text{l}$ ), and platelet count of  $8.3 \times 10^4/\mu\text{l}$ . Myeloid precursors were not detected in the peripheral blood. The peripheral blood lymphocyte subpopulation showed 72% CD3+ cells, 51% CD4+ cells (51% CD3+CD4+ cells), 20% CD8+ cells, 3% CD19+ cells, and 24% CD3–CD16+/56+ cells. Serum urea nitrogen was 15.2 mg/dl, creatinine 1.1 mg/dl, albumin 3.9 g/dl, aspartate aminotransferase 22 U/l, alanine aminotransferase 12 U/l, lactate dehydrogenase 249 U/l, and IgE 40 IU/ml. The urine showed 2+ protein and 3+ blood. Urinary sediment revealed 51–100 red blood cells and 6–10 white blood cells per high-power field without casts. The culture of the urine was negative including that for acid-fast bacterium. Microscopic examination with Giemsa stain revealed



**Fig. 1.** Imaging study of the bladder. **a** Ultrasonography of the abdomen: axial sonogram at the level of the lower urinary bladder shows marked, nearly circumferential irregular thickening of the bladder wall. **b** MRI of the abdomen: sagittal T1-weighted MR image shows diffuse thickening of the bladder (maximum of 2 cm at the posterior wall).



**Fig. 2.** Hematoxylin and eosin staining of the bladder biopsy. Severe eosinophilic infiltration was observed (**a**,  $\times 100$ ), and there was degranulation of eosinophils (arrows in **b**,  $\times 400$ ).

eosinophils in the urine. Chest X-ray showed no pulmonary infiltrate. The cardiothoracic ratio was 77%, which was his baseline level. Echocardiography revealed normal cardiac wall thickness. Stool examination was negative for parasites or ova. Radioallergosorbent tests for tick, house dust, and pollen were negative. Ultrasonography of the abdomen revealed marked, nearly circumferential thickening of the bladder wall (fig. 1a). Rounding of the liver edge, enlargement of the left lobe, and dilation of liver vein, probably due to the congestive heart failure, were noted. Neither splenomegaly nor lymphadenopathy was detected. MRI of the bladder showed diffuse thickening of the bladder with a posterior wall thickness of 2 cm (fig. 1b). Cystoscopy revealed diffusely edematous and hyperemic mucosa without any focal mass. Urethral stricture was also noted, and urethral dilatation was performed. Urine flowmetry demonstrated a maximum flow rate of 5.2 ml/s with a postvoid residual of 167 ml. Bladder biopsy showed eosinophilic infiltration of the mucosa and submucosa, and degranulation was observed (fig. 2a, b). Based on the clinical and pathological findings, this patient was diagnosed as having EC. Drug-induced lymphocyte stimulation tests for hydrochlorothiazide, spironolactone, ubidecarenone, and digoxin were negative. Upper gastrointestinal endoscopy revealed chronic gastritis with no eosinophilic infiltration. After admission, eosin-

**Table 1.** Characteristics of 9 patients with definite or probable HES

Patient No.	Age years	Sex	Diagnosis	Treatment	Re-currence	Past medical history	First author [Ref.]
1	37	male	HES, eosinophilic cystitis, colitis, enteritis	PSL	no	none	Amin [3]
2	8	male	HES, eosinophilic cystitis, gastritis, enteritis, pulmonary nodules	PSL, cyclosporine	yes	none	Hosoki [6]
3	2	female	HES, eosinophilic cystitis, ascites, granulomatous peritonitis	PSL, imatinib	yes	none	Nofal [15]
4	27	male	HES, eosinophilic cystitis, urethral stricture	PSL, antiallergics	yes	tetralogy of Fallot	Kojima (present study)
5	81	male	eosinophilic cystitis, colitis, ascites	steroids, antibiotics	no	none	Kim [8]
6	40	male	eosinophilic cystitis, colitis, hepatic nodules	steroids, antibiotics	no	none	Kim [8]
7	25	male	eosinophilic cystitis	PSL	yes	none	Matsuura [10]
8	8	female	eosinophilic cystitis	PSL	no	none	Tamai [13]
9	11	male	eosinophilic cystitis	no	no	bilateral kidney hypoplasia	Verhagen [14]

PSL = Prednisolone.

ophils gradually increased to 79.5% ( $19.2 \times 10^3/\mu\text{l}$ ). Treatment with oral prednisolone 30 mg/day along with distigmine bromide and tamsulosin hydrochloride for his dysuria was started. His symptoms resolved promptly, and his eosinophil count decreased to  $2.46 \times 10^3/\mu\text{l}$ . Prednisolone was tapered and discontinued after 9 months. Subsequently, symptoms and eosinophilia recurred, and prednisolone 6 mg/day was restarted along with fexofenadine hydrochloride. The patient is currently without symptoms on these medications.

## Results

We found 4 patients who had HES and EC including the present patient and 14 EC patients who had no etiology and an eosinophil count as described in the report [3–15]. Of the 14 patients reported as EC, 5 had an eosinophil count of  $\geq 1,500/\mu\text{l}$  on at least one occasion without apparent cause of eosinophilia, which suggests that these patients had HES (table 1).

Of the 9 patients with definite or probable HES, 7 (78%) were male and 5 (56%) showed concomitant eosinophilic gastrointestinal disorder. None of the patients had systemic symptoms such as fever, arthralgia, or skin rash. Eight patients (89%) received steroid therapy and 4 (44%) showed recurrent symptoms after initial treatment.

## Discussion

We report a patient who showed marked eosinophilia along with EC, fulfilling the diagnostic criteria of HES. There are two case reports of HES which presented with concomitant EC and eosinophilic enterocolitis [3, 6]. Another patient had cystitis and granulomatous peritonitis [15]. Ours is the first report describing HES which presented as EC without other organ involvement.

The pathophysiology of HES is not well understood. Several mechanisms have been proposed as the cause of dysregulated overproduction of eosinophils, i.e. clonal eosinophilic

proliferation due to a primary defect in hematopoietic stem cells, overproduction of eosinophilopoietic cytokines such as IL-5, and functional abnormalities of the eosinophilopoietic cytokines. However, how and why these overproduced eosinophils infiltrate the target organ and cause symptoms is unknown.

Eosinophilic degranulation, found in our patient, is considered as evidence of organ damage. While eosinophilia is one of the classic criteria of HES, it does not directly represent the degree of organ involvement. For example, patients with marked eosinophilia may have no evidence of organ involvement and follow a benign course. On the other hand, patients with chronic eosinophilic pneumonia who require continuous treatment may have marginally elevated eosinophil counts [2]. Eosinophilic degranulation, in contrast to eosinophilia, represents definite organ involvement and indicates the need for immediate treatment. A number of agents including IL-5, interferon- $\gamma$ , and secretory IgA have been shown to cause degranulation and release of the granule cationic proteins from activated eosinophils [16, 17]. Once secreted, these cationic proteins exert multiple proinflammatory and cytotoxic activities, which has been shown both *in vitro* and *in vivo* [16]. Although eosinophilic degranulation is widely believed to be evidence of eosinophilic activation, there has been no report demonstrating eosinophilic degranulation in EC. Further pathophysiologic study of EC with regard to the role of eosinophilic degranulation may be warranted especially in those who may have HES as an underlying disorder.

Urethral stricture was noted in our patient. There are two case reports of EC associated with urethral stricture [18, 19]. Urethral biopsy of one case revealed hyperemia and chronic nonspecific inflammatory infiltration without eosinophils [18]. Another case had a history of blunt pelvic trauma, which could be an independent cause of the urethral stricture [19]. It is possible that the lesion of EC extends to the urethra causing urethral stricture. Unfortunately, urethral biopsy was not performed in our patient, and there is no evidence to prove the hypothesis.

We reviewed the literature to find patients with EC who may have had HES. Seven out of 9 patients with definite or probable HES were male. This is in agreement with the fact that HES is more common in males than females with a ratio of 9:1 [20], whereas EC has an almost equal male-to-female ratio [21, 22]. None of the 9 patients showed systemic symptoms such as fatigue, cough, dyspnea, rash, and fever generally associated with HES [23]. Instead, dysuria and abdominal pain, symptoms of cystitis, were the presenting signs. Interestingly, an eosinophilic gastrointestinal disorder was seen in 5 out of 9 patients. The occurrence of this complication with EC is reported to be only 4.5% [21]. One patient had unusual symptoms such as ascites, granulomatous peritonitis involving pylorus, and hepatic nodules. Of note, 5 of 9 patients were reported as EC and were not evaluated for HES even though they showed an eosinophil count of  $\geq 1,500/\mu\text{l}$ .

We started treatment with prednisolone 30 mg/day. According to a previous report of 188 patients with HES, the median maximal daily dose of prednisolone was 40 mg [24]. The goals of the therapy are to reduce the symptoms and to keep the eosinophil counts low. In the same study, prednisolone 10 mg/day was reported to be the median maintenance dose [24]. Although the symptoms recurred once after the discontinuation of prednisolone, restarting a lower dose of prednisolone along with an antiallergic agent improved the symptoms as well as eosinophilia. Our patient is currently well on low-dose prednisolone and fexofenadine hydrochloride.

Of 9 patients, 7 (78%) received steroid therapy and 4 (44%) had recurrence. The prognosis of EC is reported to be more benign compared with that of HES. In one case series of 83 adult EC patients, 32 (39%) did not require any treatment [22]. Another review showed that 91 (77%) out of 118 EC patients were cured with treatment and only 15 (13%) had recurrence of the symptoms [21].

In conclusion, we experienced a case of HES which presented only as EC. Although EC is not usually considered as a manifestation of HES, our literature search suggests that HES may not be uncommon as an underlying disorder of EC. Considering this possibility, thorough clinical evaluation and close monitoring are warranted when treating EC patients with a high eosinophil count.

### Disclosure Statement

The authors have no conflicts of interest to declare.

### References

- 1 Chusid MJ, Dale DC, West BC, Wolff SM: The hypereosinophilic syndrome: analysis of fourteen cases with review of the literature. *Medicine* 1975;54:1–27.
- 2 Simon HU, Rothenberg ME, Bochner BS, Weller PF, Wardlaw AJ, Wechsler ME, Rosenwasser LJ, Roufosse F, Gleich GJ, Klion AD: Refining the definition of hypereosinophilic syndrome. *J Allergy Clin Immunol* 2010;126:45–49.
- 3 Amin MA, Hamid MA, Saba S: Hypereosinophilic syndrome presenting with eosinophilic colitis, enteritis and cystitis. *Chin J Dig Dis* 2005;6:206–208.
- 4 Barese CN, Podesta M, Litvak E, Villa M, Rivas EM: Recurrent eosinophilic cystitis in a child with chronic granulomatous disease. *J Pediatr Hematol Oncol* 2004;26:209–212.
- 5 Hidoussi A, Slama A, Jaidane M, Zakhama W, Youssef A, Ben Sorba N, Mosbah AF: Eosinophilic cystitis induced by bacillus Calmette-Guerin (BCG) intravesical instillation. *Urology* 2007;70:591.e9–591.e10.
- 6 Hosoki K, Nagao M, Iguchi K, Ihara T, Yamada Y, Higashigawa M, Kephart GM, Kita H, Fujisawa T: An 8-year-old boy with hypereosinophilic syndrome. *Int Arch Allergy Immunol* 2011;155(suppl 1):117–122.
- 7 Hwang EC, Kwon DD, Kim CJ, Kang TW, Park K, Ryu SB, Ma JS: Eosinophilic cystitis causing spontaneous rupture of the urinary bladder in a child. *Int J Urol* 2006;13:449–450.
- 8 Kim MS, Park H, Park CS, Lee EJ, Rho MH, Park NH, Joh J: Eosinophilic cystitis associated with eosinophilic enterocolitis: case reports and review of the literature. *Br J Radiol* 2010;83:e122–e125.
- 9 Lin HH, Yen TH, Huang CC, Chiang YJ, Kuo HL: Blood eosinophilia, corticoadrenal insufficiency and eosinophilic cystitis. *Urol Int* 2008;80:219–221.
- 10 Matsuura H, Sakurai M, Arima K: Recurrent eosinophilic cystitis with peripheral eosinophilia and hyperimmunoglobulinemia E. *Urol Int* 2003;70:327–329.
- 11 Pomeranz A, Eliakim A, Uziel Y, Gottesman G, Rathaus V, Zehavi T, Wolach B: Eosinophilic cystitis in a 4-year-old boy: successful long-term treatment with cyclosporin A. *Pediatrics* 2001;108:E113.
- 12 Sterrett S, Morton J, Perry D, Donovan J: Eosinophilic cystitis: successful long-term treatment with montelukast sodium. *Urology* 2006;67:423.e419–423.e421.
- 13 Tamai K, Koyama T, Saida S, Nishikomori R, Togashi K: MR imaging findings of eosinophilic cystitis in an 8-year-old girl. *Pediatr Radiol* 2007;37:836–839.
- 14 Verhagen PC, Nikkels PG, de Jong TP: Eosinophilic cystitis. *Arch Dis Childhood* 2001;84:344–346.
- 15 Nofal R: Eosinophilic cystitis as symptom of an idiopathic hypereosinophilic syndrome (in German). *Aktuelle Urol* 2007;38:148–151.
- 16 Ackerman SJ, Bochner BS: Mechanisms of eosinophilia in the pathogenesis of hypereosinophilic disorders. *Immunol Allergy Clin North Am* 2007;27:357–375.
- 17 Lee JJ, Lee NA: Eosinophil degranulation: an evolutionary vestige or a universally destructive effector function? *Clin Exp Allergy* 2005;35:986–994.
- 18 Martino G, Torcasio A, Iavarone C, Cardarelli A, Monti M: Eosinophilic cystitis associated with urethral stricture disease from pelvic trauma. Case report and literature review. *G Chir* 2005;26:425–429.
- 19 Atahan O, Kayigil O, Atahan S, Metin A: Eosinophilic cystitis-induced severe urethral stricture. *Br J Urol* 1995;76:132–133.
- 20 Katz HT, Haque SJ, Hsieh FH: Pediatric hypereosinophilic syndrome (HES) differs from adult HES. *J Pediatr* 2005;146:134–136.
- 21 van den Ouden D: Diagnosis and management of eosinophilic cystitis: a pooled analysis of 135 cases. *Eur Urol* 2000;37:386–394.
- 22 Itano NM, Malek RS: Eosinophilic cystitis in adults. *J Urol* 2001;165:805–807.
- 23 Fauci AS, Harley JB, Roberts WC, Ferrans VJ, Gralnick HR, Bjornson BH: NIH conference. The idiopathic hypereosinophilic syndrome. Clinical, pathophysiologic, and therapeutic considerations. *Ann Intern Med* 1982;97:78–92.
- 24 Ogbogu PU, Bochner BS, Butterfield JH, Gleich GJ, Huss-Marp J, Kahn JE, Leiferman KM, Nutman TB, Pfab F, Ring J, Rothenberg ME, Roufosse F, Sajous MH, Sheikh J, Simon D, Simon HU, Stein ML, Wardlaw A, Weller PF, Klion AD: Hypereosinophilic syndrome: a multicenter, retrospective analysis of clinical characteristics and response to therapy. *J Allergy Clin Immunol* 2009;124:1319–1325.