

Monochorionic Diamniotic Twin Pregnancies: Natural History and Risk Stratification

Liesbeth Lewi Leonardo Gucciardo Tim Van Mieghem Philippe de Koninck
Veronika Beck Helga Medek Dominique Van Schoubroeck Roland Devlieger
Luc De Catte Jan Deprest

Department of Obstetrics and Gynecology, University Hospital Gasthuisberg, Leuven, Belgium

Key Words

Anemia · Monochorionic diamniotic twins · Polycythemia · Twin pregnancies · Twin-to-twin transfusion syndrome

Abstract

About 30% of monochorionic twin pregnancies are complicated by twin-to-twin transfusion syndrome (TTTS), isolated discordant growth, twin anemia-polycythemia sequence, congenital defects or intrauterine demise. About 15% will be eligible for invasive fetal therapy, either fetoscopic laser treatment for TTTS or fetoscopic or ultrasound-guided umbilical cord coagulation for a severe congenital defect in one twin or severe discordant growth with imminent demise of the growth-restricted twin. Ultrasound examination in the first and early second trimester can differentiate the monochorionic twins at high risk for adverse outcome from those likely to be uneventful, which may be useful for patient counselling and planning of care.

Copyright © 2010 S. Karger AG, Basel

Introduction

Monochorionic twins are monozygotic and result from the cleavage of a single zygote. About 70% of monozygotic twins are monochorionic, whereas 30% are dichorionic, depending on the time span between fertilization and cleavage [1]. Monochorionic gestations have a much higher risk of adverse outcome than their dichorionic counterparts because of vascular anastomoses that connect the two circulations. This shared circulation may lead to some unique complications such as twin-to-twin transfusion syndrome (TTTS), twin anemia-polycythemia sequence (TAPS) and demise or neurological damage of the surviving twin if the co-twin dies during pregnancy. Also, the shared circulation mandates a different management of common problems in multiple gestations, such as growth restriction of one twin or discordant abnormalities, because the well-being of the twins is interrelated [2].

Monochorionic twins have a single placenta, which is less efficient to nurture 2 fetuses to term. In fact, the monochorionic placenta consists of three parts: two belonging to each twin individually and a third shared part.

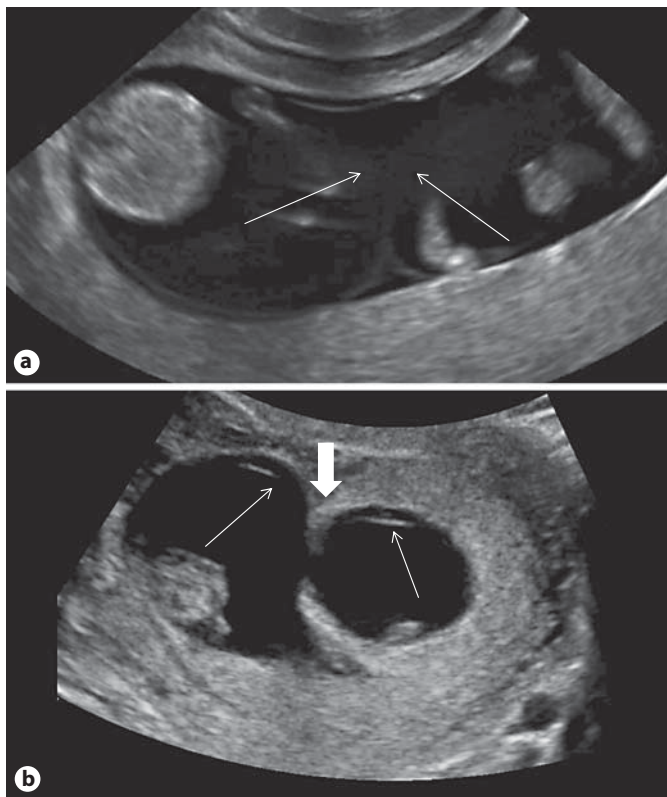


Fig. 1. Chorionicity determination in the first trimester. **a** Ultrasound image of a monochorionic diamniotic twin pregnancy: the twins are separated only by two thin layers of amniotic membrane (thin arrows). **b** In dichorionic pregnancies, there are three layers separating the twins: two thin amniotic membranes (thin arrows) with a thick layer of chorion in between (thick arrow).

Finally, the size of each individual part may differ and lead to growth restriction of the twin with the smaller part and to significant intertwin size discordance [3, 4].

Survival Rates

In areas with access to invasive antenatal therapy, 90% of monochorionic twins diagnosed in the first trimester will survive [5, 6]. More specifically, in 85% of pregnancies both survive, in 7.5% one survives and in 7.5% there are no survivors. Most losses (80%) occur prior to 24 weeks and, as mentioned above, the extra loss in monochorionic twins is entirely due to complications of the shared circulation and for the most part to TTTS. Comparison with earlier series suggests that invasive fetal therapy increases the likelihood of at least one twin surviving, decreasing the double-loss rate [6].

Determination of Chorionicity

The distinction between high-risk monochorionic and lower-risk dichorionic twin pregnancies can be accurately achieved in the first-trimester scan, because amnion and chorion are still separated from one another [7, 8]. Chorionicity is therefore simply a matter of counting the layers that separate the twins. In monochorionic diamniotic twin pregnancies, the fetuses are separated by only two thin layers of amniotic membrane (fig. 1a). In contrast, dichorionic twins are separated by three layers: two thin amniotic membranes with a thick layer of chorion in between (fig. 1b). The lambda sign reflects the apposition of the two placental disks and is also indicative of dichorionicity (fig. 2a). Nevertheless, the concept of the lambda sign may be confusing. In first-trimester monochorionic diamniotic twins, the two amniotic sacs and the uterine wall form a lambda rather than a T sign, although the lambda here is an ‘empty’ rather than a ‘full’ lambda (fig. 2b).

Later in gestation, because of the close apposition of amnion and chorion, it becomes much more difficult to accurately determine if same-sex twins are mono- or dichorionic. Although the lambda sign usually indicates dichorionicity at later gestational ages, some caution is required because folding of the chorionic plate can create a ‘false’ lambda sign in a monochorionic pregnancy (fig. 3). Nevertheless, as chorionicity is most accurately determined in the first trimester and because nearly all pregnant women have nowadays access to a first-trimester scan, the importance of first-trimester chorionicity determination cannot be stressed enough. It is strongly recommended to store the images of the intertwin septum as proof chorionicity, should there be any doubt later on.

Fetal Complications in Monochorionic Twin Pregnancies

Monochorionic twins can be discordant in amniotic fluid volume, in size, in the presence of congenital abnormalities and in hemoglobin concentration. Severe amniotic fluid discordance is typical for TTTS, which complicates 8–10% of monochorionic twin gestations, usually between 16 and 26 weeks [5, 6]. TTTS is the most important cause of death and handicap in monochorionic twin pregnancies [9]. Its sonographic diagnosis is based on strict criteria of amniotic fluid discordance. Most European centers adhere to gestational-age-dependent criteria to define polyhydramnios in the recipient sac: deepest

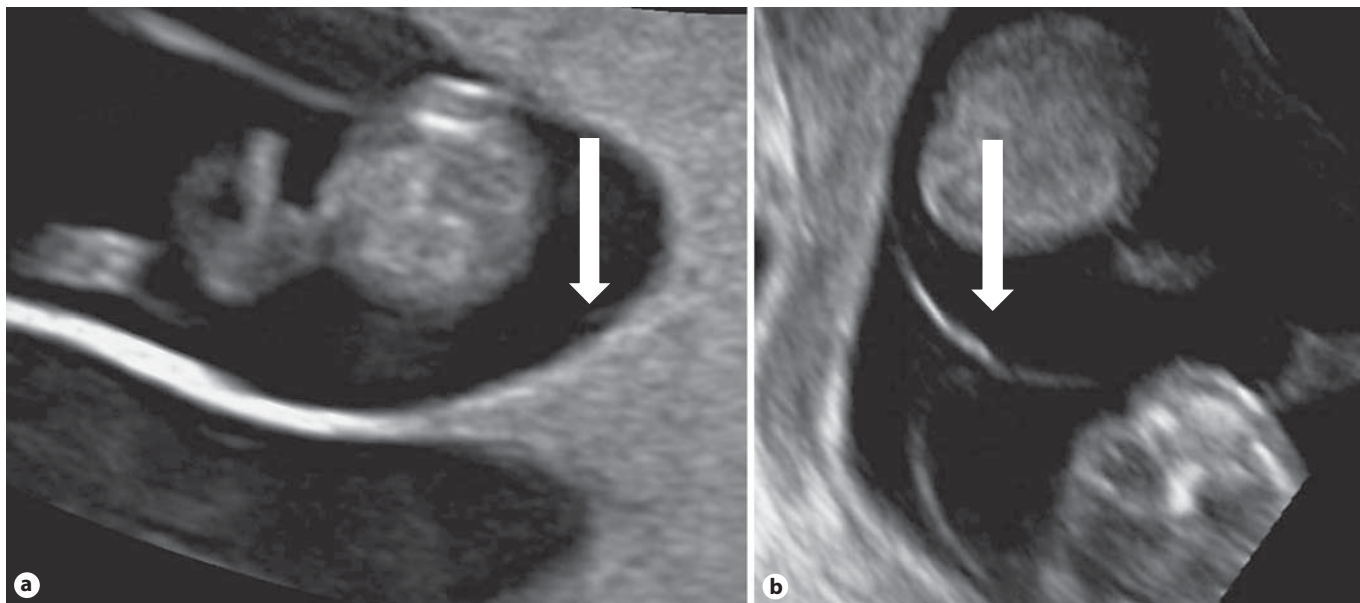


Fig. 2. First-trimester imaging of the ‘full’ lambda of a dichorionic pregnancy created by the close apposition of the two placental disks (**a**; arrow) compared to the ‘empty’ lambda of a monochorionic diamniotic twin pregnancy created by the apposition of the two amniotic sacs (**b**; arrow).

vertical pocket >8 cm prior to 20 weeks and >10 cm after 20 weeks [10]. In contrast, in the United States, the 8-cm cutoff is used more often throughout gestation [11] (fig. 4a). Both continents agree on the definition of oligohydramnios in the donor’s sac (<2 cm deepest vertical pocket; fig. 4b).

TTTS is thought to arise from an intertwin transfusion imbalance across the vascular anastomoses with hypervolemia, polyuria and polyhydramnios in the recipient and hypovolemia, oliguria and oligo-anhydramnios in the donor. However, since most do not have significant intertwin hemoglobin discordance [12], hormonal factors almost certainly play an important role as well [13]. The presentation of TTTS is variable and its course mainly unpredictable. As such, TTTS may present as a slow-onset disease or be rapidly progressive. Most likely, TTTS encompasses different diseases with a variable contribution of transfusion imbalance, unequal placental sharing and hormonal dysfunction.

Untreated mid-trimester TTTS carries an extremely poor prognosis. Fetoscopic laser coagulation of the vascular anastomoses is the only curative and currently the best available treatment (fig. 4c, d). Compared to amniodrainage, laser coagulation results in better survival rates and in a reduced neurological morbidity [10]. Nevertheless, survival rates after fetoscopic laser surgery are

only about 70% [10, 14], and long-term developmental delay occurs in about 15% of survivors [15, 16].

Fetal loss is attributable to intrauterine demise of one twin, which most commonly occurs within the 1st post-operative week [17] and is probably related to cardiac failure, unequal placental sharing or incomplete separation. Miscarriage and preterm birth (often after ruptured membranes) are other important causes of fetal loss [18]. Developmental delay may be related to the disease itself, laser surgery and most importantly to preterm birth [16].

The true mortality and morbidity of TTTS are likely to be still higher, because a not insignificant number of patients present too late for treatment with demise of one or both twins, with ruptured membranes or in active labor, and are not included in the outcome series on fetoscopic laser surgery. In our observational study of monochorionic twins followed from the first trimester, TTTS had a mortality of 55%, which is higher than the 30% usually quoted in fetoscopic laser series [4]. Future research aims to improve survival rates by better prediction, a better case selection for surgery as well as better surgical techniques to reduce the failure rate and risk of postoperative membrane rupture.

Monochorionic twins can also be discordant in size. Isolated discordant growth is usually defined as an intertwin size difference of 25% or more in the absence of

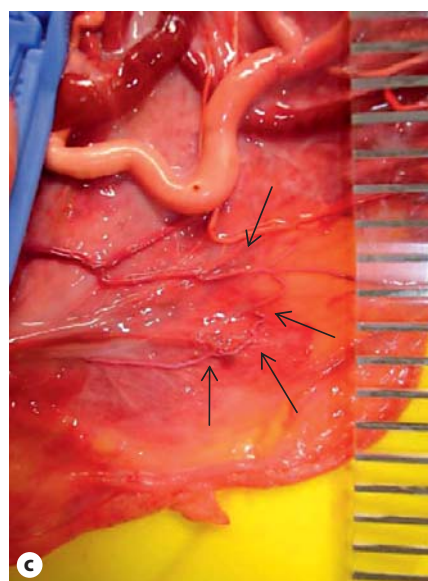
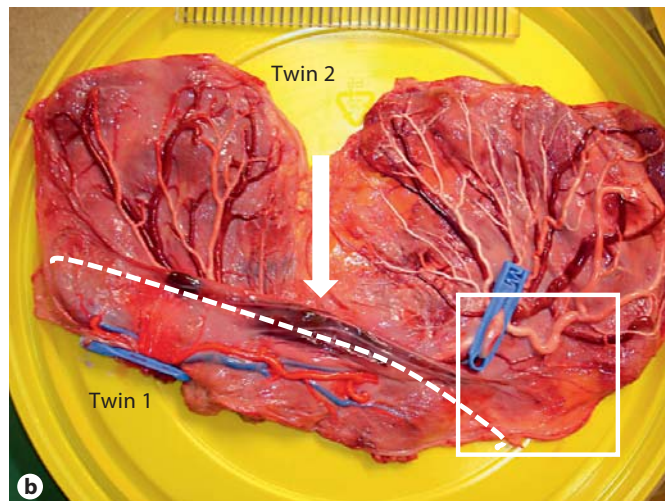
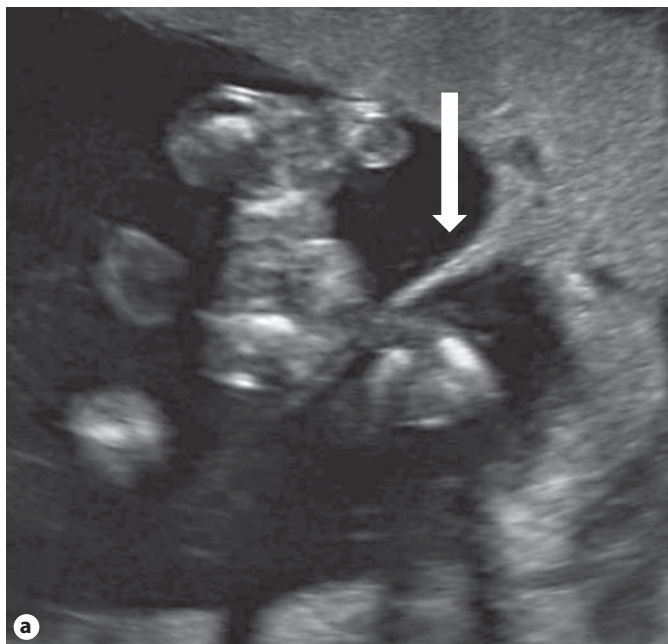

Fig. 3. a A ‘false’ lambda sign (thick arrow) observed at 20 weeks in a monochorionic diamniotic twin pregnancy, which was created by a fold in the chorionic plate. **b** Macroscopic image of the monochorionic placenta after birth 31 weeks after removal of the amniotic membranes. The placenta is unequally shared (dashed line represents the separation) with a chorionic fold (large arrow) in between the two territories. Twin 1 was growth restricted (1,000 g), severely anemic (Hb: 5 g/dl) and died 1 day after birth due to asphyxia, whereas twin 2 (1,700 g) was polycythemic (Hb: 22 g/dl), but had an uneventful neonatal course. **c** There was only one tiny vein-to-vein anastomosis (small arrows).

TTTS. Usually, in these cases, there is a certain degree of amniotic fluid discordance, too. Because of its smaller size, the smaller twin will necessarily produce less urine than its larger co-twin. Also, similar to singletons that are growth restricted, in severe cases, the smaller twin may develop oligo- or anhydramnios with deepest pockets <2 cm. Although discordant growth is commonly present in TTTS, the distinction between isolated discordant growth and TTTS is easily made by the absence of polyhydramnios in the appropriately grown twin as defined by the TTTS criteria described above. Isolated discordant growth complicates about 15% of monochorionic twin pregnancies. However, in contrast to TTTS, it has a much lower mortality, about 10 versus 55% [4]. Discor-

dant growth seems also much less likely to cause developmental delay compared to TTTS [9]. Nevertheless, as long as the twins are undelivered and especially prior to 26 weeks, about 20% of pairs with discordant growth will progress to TTTS. In fact, the diagnosis of discordant growth can only be made in retrospect when the twin pregnancy comes to an end: either at birth or in the event of intrauterine demise of one or both twins. At present, there are no good markers to differentiate the pregnancies that will remain simply growth discordant from those that will progress to TTTS. Therefore, careful surveillance remains indicated in all pregnancies with discordant growth.

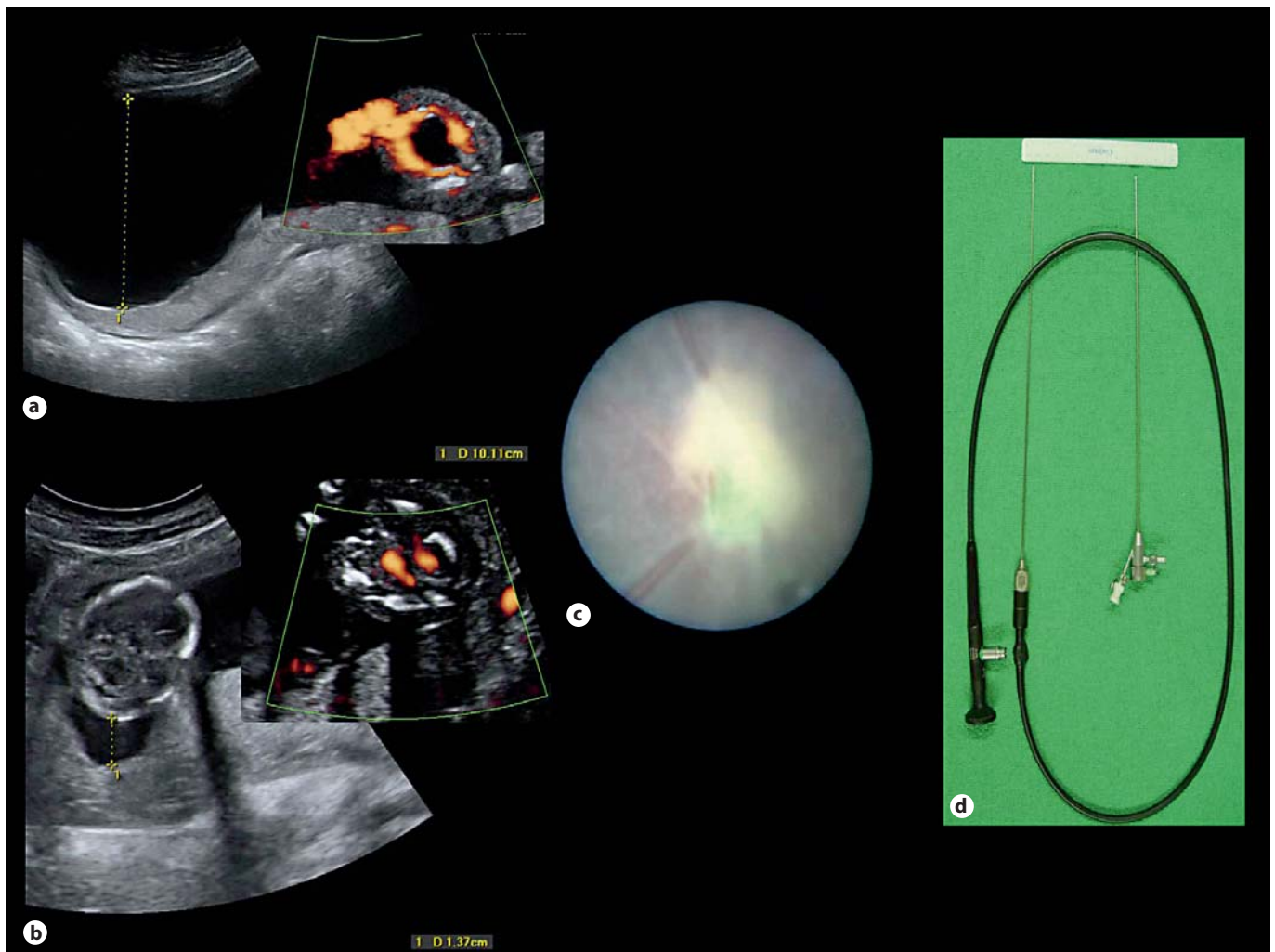


Fig. 4. **a** Ultrasound image of the polyuric polyhydramnios in the recipient twin in a TTTS case diagnosed at 20 weeks with a deepest vertical pocket >10 cm. **b** Ultrasound image of the oliguric oligohydramnios of the co-twin with a deepest vertical pocket of 1.4 cm. **c** Fetoscopic image of laser coagulation of an artery-to-vein anastomosis. **d** Fetoscope (2 mm in diameter and 30 cm in length) with remote eyepiece and straight sheath with a channel for laser fibers up to 600 μm (Storz, Tuttlingen, Germany).

There seem to be two patterns of isolated discordant growth in monochorionic twins [19]. One is early in onset and presents at or before 20 weeks. The other is late in onset and presents after 26 weeks but is usually diagnosed only at the time of birth. As expected, early-onset discordant growth carries the highest mortality (about 15%) and often there is an abnormal flow pattern in the umbilical artery of the smaller twin. Placentas of twin pairs with early-onset discordant growth are typically unequally shared with an elaborate intertwin circulation and a large artery-to-artery anastomosis. On the other hand, the mortality of late-onset discordant growth is

much lower (about 4%) and usually umbilical-artery Doppler scans are normal throughout pregnancy. In one third of pregnancies with late-onset discordant growth, a late intertwin transfusion imbalance underlies the growth discordance (TAPS), which typically presents with severe intertwin hemoglobin discordances. These placentas are usually equally shared with only a few tiny and mostly unidirectional anastomoses.

Next to this classification based on time of presentation, growth-discordant monochorionic twin pregnancies can also be grouped according to the flow pattern in the umbilical artery (fig. 5) [20]. In monochorionic twin

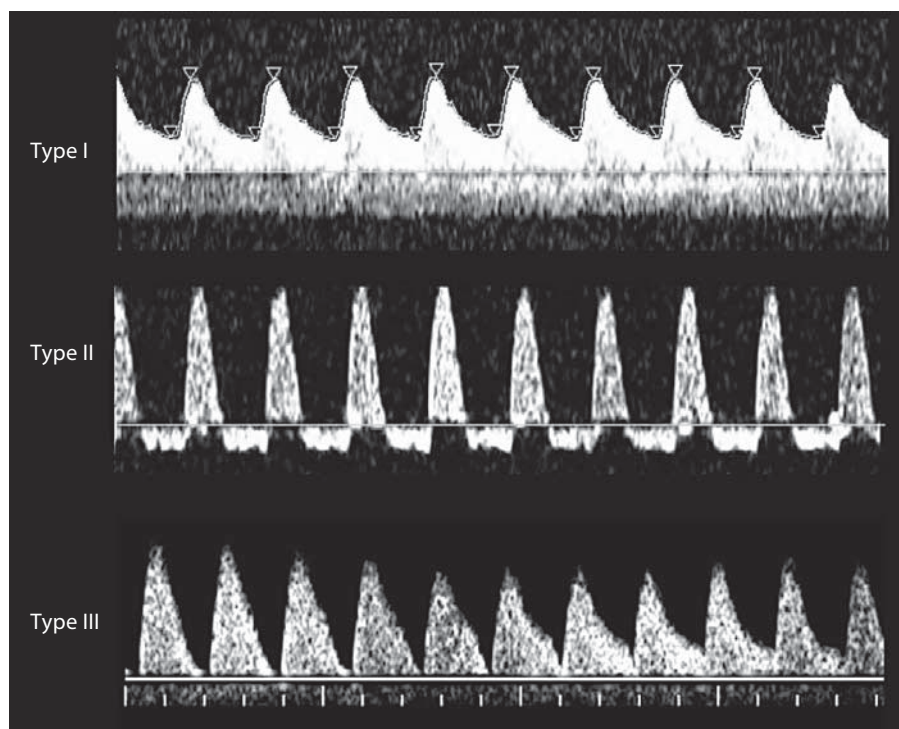


Fig. 5. Representation of the three types of discordant growth according to the umbilical-artery Doppler classification of type I with positive end-diastolic flow, type II with persistently absent end-diastolic flow and type III with intermittently absent or reversed end-diastolic flow.

pregnancies, umbilical-artery Doppler waveforms reflect not only downstream placental vascular resistance but also blood flow across the anastomoses. If umbilical-artery Doppler patterns are normal (type I), outcome is generally good. In these cases, placental sharing is mildly unequal and large artery-to-artery anastomoses are usually present. Less often, end-diastolic flow may be persistently absent or reversed (type II). These cases behave similar to growth-restricted singleton pregnancies, and an absent or reversed a-wave of the ductus venosus usually indicates imminent fetal demise. Type II placentas are more unequally shared than type I placentas, but typically lack the large artery-to-artery anastomoses. Type II cases have the worst prognosis as 90% will eventually show signs of deterioration and imminent demise. Finally, in type III, which is most common in early-onset discordant growth, end-diastolic flow is intermittently absent or reversed in the umbilical artery of the smaller twin because of a large artery-to-artery anastomosis. Type III cases have an intermediate prognosis, but are the most unpredictable. Placental sharing is grossly unequal and nearly all have large artery-to-artery anastomoses. Because of these large artery-to-artery anastomoses, unexpected demise without any signs of deterioration occurs in about 15% and half of these are double demises.

The best management of discordant growth in monochorionic twin pregnancies is not yet well established. In our center, we follow cases with early-onset discordant growth with weekly ultrasound scan to detect any progression to TTTS or signs of deterioration. From 28 weeks onward and for types II and III, we monitor daily and deliver electively 32–33 weeks after the administration of steroids. We offer laser coagulation of the vascular anastomoses in case of progression to TTTS. On the other hand, we offer selective feticide of the smaller twin by umbilical cord coagulation in type II and III cases if there are complicating features prior to viability, e.g. when the smaller twin develops anhydramnios, persistently absent or reversed flow in the ductus venosus or an arrest of growth over a 3-week period. With this policy of careful surveillance, elective preterm birth and selective feticide only for complicated cases, the survival rate for isolated early-onset discordant growth is 85% [4]. The role of laser coagulation in the management of isolated discordant growth is still controversial. Unequal placental sharing is frequently present, especially in type III cases, and here laser separation may leave too little placental territory for the smaller twin to allow an intact survival. On the other hand, separation will protect the larger twin better in the event of spontaneous demise of

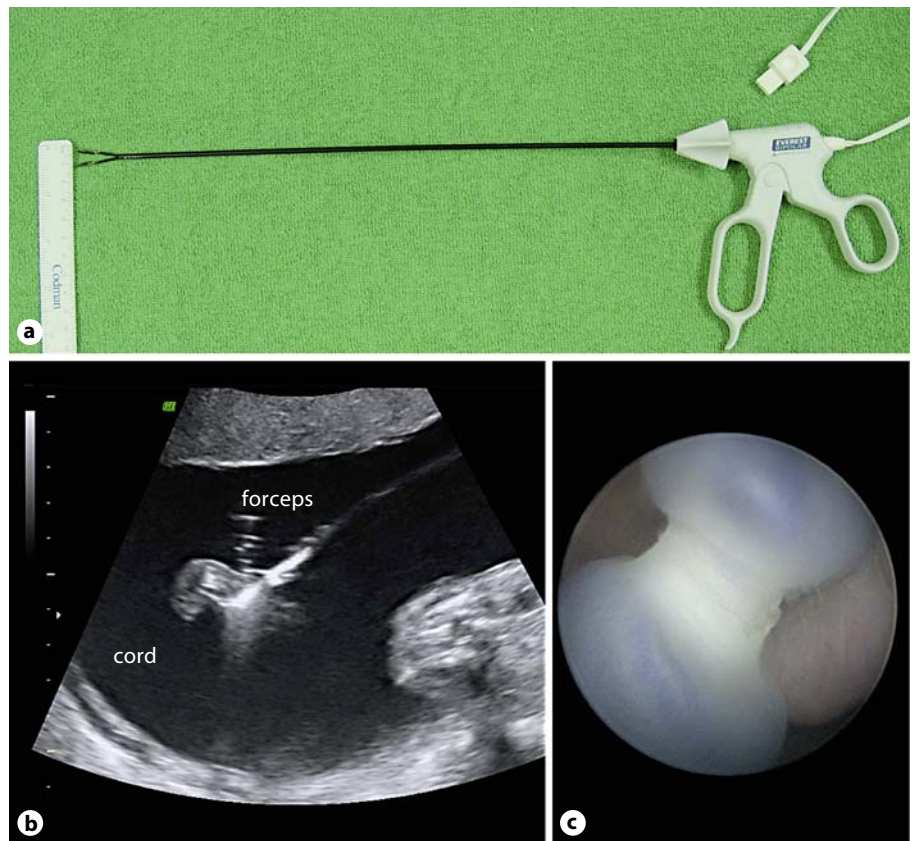


Fig. 6. **a** Disposable bipolar forceps (Everest Medical, Minneapolis, Minn., USA). **b** Ultrasound image of bipolar cord coagulation with steam bubbles indicative of effective coagulation. **c** Fetoscopic control to check for completeness of the coagulation: the segment was fully coagulated by bipolar coagulation.

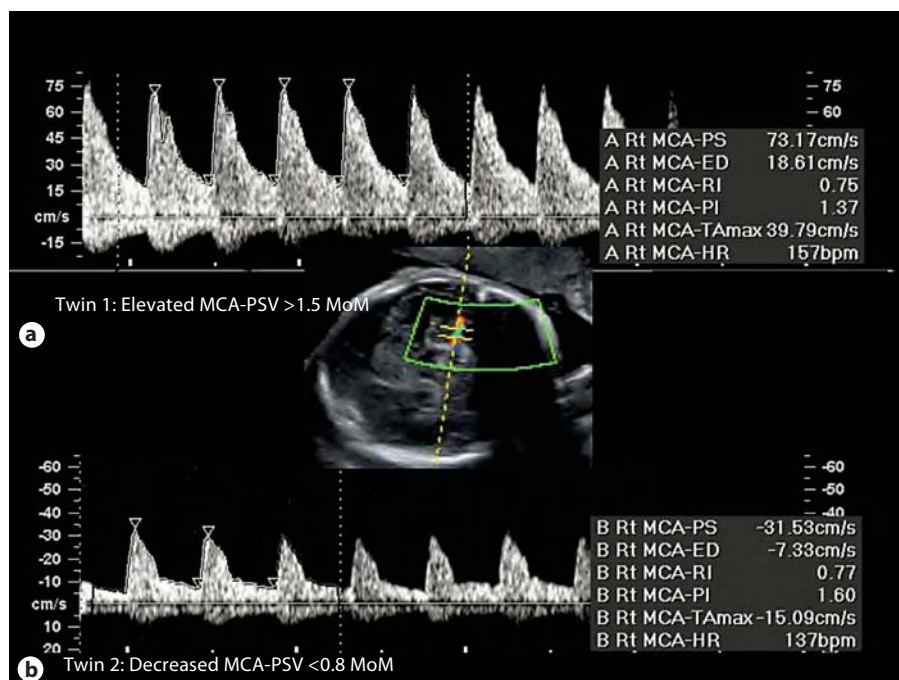
its growth-restricted co-twin. So far, small case series have failed to demonstrate a benefit of laser separation in these cases [21, 22]. For late-onset discordant growth, surveillance of the middle cerebral artery peak systolic velocity (MCA-PSV) may play an important role to detect cases with TAPS [19]. Future research needs to address better predictors to discriminate between discordant-growth twins with a favorable outcome and those at high risk of TTTS, intrauterine demise or long-term neurological morbidity who may benefit from invasive antenatal therapy.

Monochorionic twin pregnancies can also be discordant in the presence of congenital abnormalities, which are more common in monochorionic twins, probably due to a teratogenic effect of embryo cleavage or because of complications of the shared circulation. As such, major congenital defects are found in about 6% of pregnancies and usually only one twin is affected [4]. Cardiac anomalies are especially prevalent amongst monochorionic twins [23]. Therefore, all monochorionic twins should benefit from detailed sonographic follow-up by experienced sonographers. In the event of a severe discordant

abnormality, selective reduction by fetoscopic or ultrasound-guided cord coagulation (fig. 6) is an alternative to termination of the entire pregnancy and has a survival rate of >80% for the non-affected co-twin [24, 25]. About half of the losses are attributable to intrauterine demise and about half to postnatal losses due to very preterm birth, mostly related to iatrogenic membrane rupture [25].

Finally, monochorionic twins can have a discordant hemoglobin level, which was recently described as twin anemia polycythemia sequence (TAPS) [26]. TAPS represents TTTS as it is known by the neonatologist, because it usually presents at the time of birth with a large plethoric twin and usually a small anemic twin. Postnatal diagnosis is based on the presence of chronic anemia with reticulocytosis in the donor and polycythemia in the recipient. The reticulocytosis and the absence of hypovolemic shock in the donor allow differentiation from an acute intrafetal transfusion. Absence of fetal cells in the maternal circulation or red blood cell antibodies excludes fetomaternal hemorrhage and alloimmunization, respectively. TAPS can occur spontaneously in previously

Fig. 7. Ultrasound image at 31 weeks of the MCA-PSV of the 'presumed' dichorionic twin pregnancy where the false lambda sign and placenta is represented in figure 3. The growth-restricted twin had oligohydramnios (deepest pocket 1.5 cm), normal umbilical-artery Doppler waveforms but elevated MCA-PSV (73 cm/s), whereas its appropriately grown co-twin had normal amniotic fluid, normal umbilical-artery Doppler waveforms, but decreased MCA-PSV (31 cm/s). The twins were delivered 1 day later because of abnormal heart rate tracings of twin 1, who died after birth due to severe asphyxia and anemia.



uncomplicated pregnancies [4, 26] or after incomplete laser surgery as a treatment for TTTS [27].

Iatrogenic TAPS may occur in up to 13% of ongoing twin pregnancies after laser treatment and is diagnosed by an elevated MCA-PSV >1.5 multiples of the median (MoM) in one twin, suggesting anemia, and <0.8 MoM in the other, suggesting polycythemia [27]. On the other hand, spontaneous TAPS occurs in about 5% of previously uncomplicated pregnancies, usually after 30 weeks [4], especially in pairs with late-onset discordant growth [19]. TAPS may also account for some late and previously unexplained intrauterine deaths [4]. However, it remains to be demonstrated if MCA-PSV will identify TAPS in previously uncomplicated pregnancies. Nevertheless, MCA-PSV measurements are part of our routine follow-up of monochorionic twins (fig. 7). Similar to discordant growth, the diagnosis of TAPS can only be made in the absence of TTTS. Although some degree of amniotic-fluid discordance is usually present, in TAPS, the discordance is mild and does not comply with the criteria of TTTS. TAPS and TTTS do occasionally go together, and in <5% of TTTS cases, the donor will have a MCA-PSV >1.5 MoM [28].

The placentas of spontaneous TAPS pregnancies show a striking similarity with those of iatrogenic TAPS after incomplete laser surgery. Both have few small unidirectional artery-to-vein anastomoses without compensating

artery-to-artery anastomosis [29, 30], suggesting that TAPS results from a chronic net transfusion across these tiny anastomoses. To all rules there are exceptions, and rare cases with only a small bidirectional anastomosis have been reported [31] as we describe here a case with small vein-to-vein anastomosis (fig. 3).

The best management of iatrogenic as well as spontaneous TAPS is currently unknown. Because of its late presentation, the mortality of TAPS is likely to be lower than that of TTTS. Depending on the characteristics of each case, such as gestational age, recurrence after intrauterine transfusion, fetal hemodynamic condition, presence of congenital defects and placental localization, definitive management may consist of elective birth, cord coagulation or laser separation of the anastomoses.

Risk Stratification in Monochorionic Twin Pregnancies

Although all monochorionic twin pregnancies should be considered at high risk and deserve fortnightly ultrasound evaluations, some sonographic features in early pregnancy can differentiate between those likely to have a complicated rather than an uncomplicated outcome. This information may be useful in the setting of a dichorionic triplet, where selective termination is considered

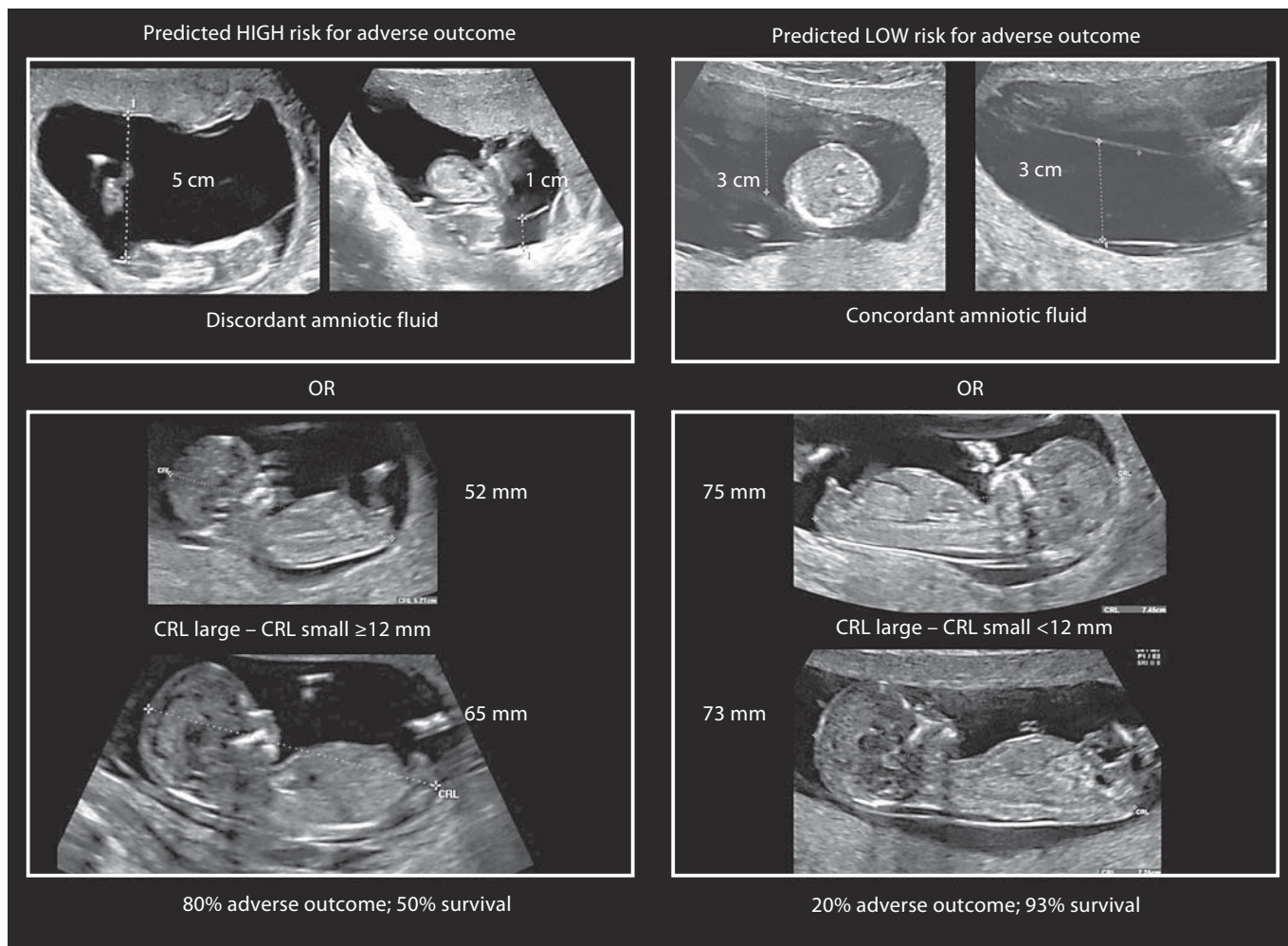


Fig. 8. Representation of the first-trimester risk assessment for the development of discordant growth, TTTS or intrauterine demise. CRL = Crown-rump length.

or in areas where access to specialist care is limited. Furthermore, surveillance may be increased to weekly evaluations in those identified to be at high risk.

In a recent study on 202 monochorionic twins, we determined the value of ultrasound examination in the first trimester and at 16 weeks to predict a complicated outcome, defined as the occurrence of TTTS, isolated discordant growth or intrauterine demise [32]. In the first trimester, pregnancies were classified as high risk if there was either discordant amniotic fluid or a difference in the crown-rump length ≥ 12 mm. Discordant amniotic fluid in the first trimester generally corresponded with deepest vertical pockets ≤ 3 cm in one sac and ≥ 5 cm in the other (fig. 8).

At 16 weeks, a high risk of adverse outcome was predicted by the presence of discordant amniotic fluid and discordant cord insertions. A discordant cord insertion was defined as a velamentous insertion in one twin with an eccentric insertion (>2 cm from the placental edge) in the other. Alternatively, for cases with only discordant fluid but concordant cord insertions, adverse outcome was predicted by an intertwin difference in abdominal circumference ≥ 6 mm, and for cases with concordant fluid but discordant cords by a difference in abdominal circumference ≥ 13 mm. Finally, in the absence of both discordant fluid and cord insertions, an adverse outcome was predicted by a difference in abdominal circumference ≥ 24 mm (fig. 9).

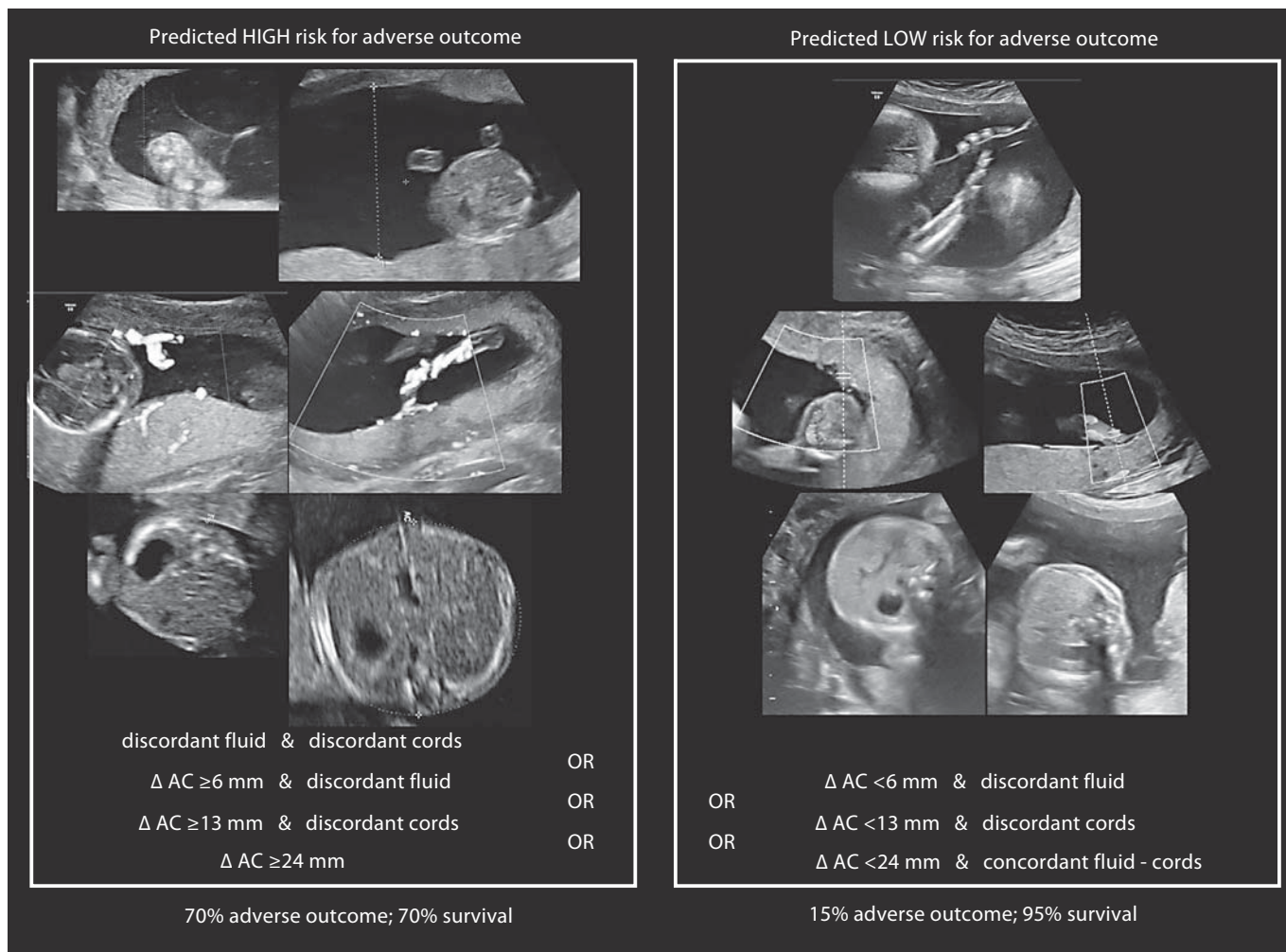


Fig. 9. Representation of the 16-week assessment for the development of discordant growth, TTTS or intrauterine demise. Those at high risk in the first trimester remain high risk and only those with a low risk in the first trimester are re-assessed. AC = Abdominal circumference.

This first-trimester and 16-week evaluations can be performed as a 2-step assessment. Here, only pregnancies with a predicted low risk in the first trimester (concordant fluid and a difference in crown-rump length <12 mm) are assessed at 16 weeks, whereas pregnancies classified as high risk in the first trimester remain high risk and are not re-assessed at 16 weeks. By classifying 20% of pregnancies as high risk, this 2-step assessment detects 60% of the three most important complications of monochorionic twin pregnancies. Of the pregnancies with a predicted low risk, 85% indeed have an uneventful outcome with a survival rate of 95%. In contrast, of the pregnancies classified as high risk, >70% have a complicated fetal outcome and a survival rate of only 70%. For this

high-risk subgroup, close monitoring in a fetal medicine center may be indicated and we now foresee weekly ultrasound evaluations for this subgroup to timely detect TTTS or imminent demise, which may benefit from invasive antenatal therapy.

A similar analysis was done for the prediction of TTTS as a separate complication. Significant predictors were difference in crown-rump length and discordant amniotic fluid in the first trimester and at 16 weeks, respectively. Although a 2-step assessment picked up 78% of TTTS cases, the positive predictive value was only 22%. The low positive predictive value can be explained by the fact that the same factors predict TTTS, discordant growth as well as intrauterine demise. As such, the com-

bined outcome of TTTS, discordant growth and intrauterine fetal death is predicted more accurately than TTTS as a separate entity. This is a drawback, since in our series, 60% of the mortality was attributable to TTTS, in contrast to 12% caused by discordant growth. Consequently, we can identify a high-risk group, but as yet we cannot distinguish the worst-outcome cases that will progress to TTTS or intrauterine demise from those with discordant growth with a much more benign course.

Recently, the group of Nicolaides reported on a large series ($n = 512$) of nuchal translucency discordance to predict TTTS [33]. An increased nuchal translucency is more common in monochorionic gestations and is >95 th percentile in at least one twin in 13% of monochorionic pregnancies, suggesting an influence of the intertwin anastomoses and possible early intertwin transfusion imbalance [34]. Discordance in nuchal translucency of 20% or more identified 52% of cases complicated by TTTS, but only 24% eventually developed TTTS [33]. This low positive predictive value for TTTS as a separate entity is in agreement with our findings [32]. However, in our series as well as in others [35–37], nuchal translucency was not a significant predictor for TTTS. In our series, 45% of twins had nuchal discordance $\geq 20\%$ in comparison with only 25% in the series by Nicolaides' group. Also, in our analysis, we did not exclude TTTS cases with normal Doppler measurements. Nevertheless, discordance in crown-rump length was also a significant predictor of TTTS in the series by Nicolaides, which is in agreement with our findings [32] as well as another series [35].

Inclusion of Doppler measurements, such as the ductus venosus pulsatility index, may allow for a better prediction of TTTS in the first trimester [38]. Another large series by the Nicolaides' group ($n = 179$) [39] reported that similar to increased nuchal translucency, absent or reversed a-wave in the ductus venosus is more common in monochorionic twin gestations. As such, there is an abnormal ductus in at least one twin in 18% of pregnancies. Although the ductus venosus was a better predictor for TTTS than the nuchal translucency or crown-rump length, its sensitivity for TTTS was 40% with a positive predictive value of 30%. Similar to the series on nuchal translucency discordance, only TTTS cases with abnormal Doppler measurements were included in the analysis, whereas these constitute less than half of all TTTS cases. In a recent smaller series on 99 monochorionic twins more optimistic figures were reported for ductus venosus Doppler evaluation for the prediction of TTTS, with a sensitivity of 75% and a positive predictive value of 56%. In these latter series, TTTS was defined as oligohy-

dramnios and an absent bladder in one and polyhydramnios and distended bladder in the other twin [40]. Probably, tricuspid insufficiency, a novel first-trimester marker for chromosomal abnormalities [41], could be an additional marker to detect early hemodynamic imbalances in monochorionic gestations, but no data are available yet.

Although larger studies are necessary, preferentially with a uniform definition of TTTS and taking into account all possible predictors, it is clear that first-trimester and early second-trimester scans can differentiate monochorionic gestations likely to be uneventful from those at high risk of an adverse outcome. Also, by this time, most severe congenital anomalies will be spotted by experienced sonographers. By and large, one can say that the more normal and concordant the size, amniotic fluid, ductus venosus waveforms and umbilical cord insertions, the more likely the pregnancy will be uneventful.

However, we will never succeed in predicting all complications in early gestation. Vascular anastomotic patterns probably change randomly with placental growth [42]. Intertwin transfusion is therefore a fragile equilibrium and monochorionic twin pregnancies will always remain to a certain extent unpredictable, at least as long as both twins are connected to the placenta. As such, it seems unlikely that complications such as late-onset discordant growth, late second-trimester TTTS as well as TAPS will ever be predictable in early pregnancy. Ideally, every monochorionic twin pregnancy should therefore benefit from an ultrasound scan once every other week. This obviously reduces the significance of any risk assessment in early pregnancy, although it remains useful for patient counselling and to determine the frequency of follow-up and whether or not evaluations are best done in a dedicated fetal medicine center.

References

- 1 Ohm Kyvik K, Derom C: Data collection on multiple births – establishing twin registers and determining zygosity. *Early Hum Dev* 2006;82:357–363.
- 2 Lewi L, Van Schoubroeck D, Gratacos E, Witters I, Timmerman D, Deprest J: Monochorionic diamniotic twins: complications and management options. *Curr Opin Obstet Gynecol* 2003;15:177–194.
- 3 Fick AL, Feldstein VA, Norton ME, Wassel Fyr C, Caughey AB, Machin GA: Unequal placental sharing and birth weight discordance in monochorionic diamniotic twins. *Am J Obstet Gynecol* 2006;195:178–183.

- 4 Lewi L, Cannie M, Blickstein I, Jani J, Huber A, Hecher K, Dymarkowski S, Gratacós E, Lewi P, Deprest J: Placental sharing, birth-weight discordance, and vascular anastomoses in monochorionic diamniotic twin placentas. *Am J Obstet Gynecol* 2007;197:587.e1-587.e8.
- 5 Acosta-Rojas R, Becker J, Munoz-Abellana B, Ruiz C, Carreras E, Gratacos E, Catalunya and Balears Monochorionic Network: Twin chorionicity and the risk of adverse perinatal outcome. *Int J Gynaecol Obstet* 2007;96:98-102.
- 6 Lewi L, Jani J, Blickstein I, Huber A, Gucciardo L, Van Mieghem T, Doné E, Boes AS, Hecher K, Gratacós E, Lewi P, Deprest J: The outcome of monochorionic diamniotic twin gestations in the era of invasive fetal therapy: a prospective cohort study. *Am J Obstet Gynecol* 2008;199:514.e1-514.e8.
- 7 Carroll SG, Soothill PW, Abdel-Fattah SA, Porter H, Montague I, Kyle PM: Prediction of chorionicity in twin pregnancies at 10-14 weeks of gestation. *BJOG* 2002;109:182-186.
- 8 Stenhouse E, Hardwick C, Maharaj S, Webb J, Kelly T, Mackenzie FM: Chorionicity determination in twin pregnancies: how accurate are we? *Ultrasound Obstet Gynecol* 2002;19:350-352.
- 9 Ortibus E, Lopriore E, Deprest J, Vandebussche FP, Walther FJ, Diemert A, Hecher K, Lagae L, De Cock P, Lewi PJ, Lewi L: The pregnancy and long-term neurodevelopmental outcome of monochorionic diamniotic twin gestations: a multicenter prospective cohort study from the first trimester onward. *Am J Obstet Gynecol* 2009;200:494.e1-494.e8.
- 10 Senat MV, Deprest J, Boulvain M, Paupe A, Winer N, Ville Y: Endoscopic laser surgery versus serial amnioreduction for severe twin-to-twin transfusion syndrome. *N Engl J Med* 2004;351:136-144.
- 11 Quintero RA, Morales WJ, Allen MH, Bornick PW, Johnson PK, Kruger M: Staging of twin-twin transfusion syndrome. *J Perinatol* 1999;19:550-555.
- 12 Denbow ML, Fogliani R, Kyle P, Letsky E, Nicolini U, Fisk N: Haematological indices at fetal blood sampling in monochorionic pregnancies complicated by fetofetal transfusion syndrome. *Prenat Diagn Ther* 1998;18:941-946.
- 13 Mahieu-Caputo D, Meulemans A, Martinovic J, Gubler MC, Delezoid AL, Muller F, Madelenat P, Fisk NM, Dommergues M: Twin-to-twin transfusion syndrome. Role of the fetal renin-angiotensin system. *Am J Pathol* 2001;156:629-636.
- 14 Huber A, Diehl W, Bregenzler T, Hackeloer BJ, Hecher K: Stage-related outcome in twin-twin transfusion syndrome treated by fetoscopic laser coagulation. *Obstet Gynecol* 2006;108:333-337.
- 15 Graef C, Ellenrieder B, Hecher K, Hackeloer BJ, Huber A, Bartmann P: Long-term neurodevelopmental outcome of 167 children after intrauterine laser treatment for severe twin-twin transfusion syndrome. *Am J Obstet Gynecol* 2006;194:303-308.
- 16 Lopriore E, Ortibus E, Acosta-Rojas R, Le Cessie S, Middeldorp JM, Oepkes D, Gratacos E, Vandebussche FP, Deprest J, Walther FJ, Lewi L: Risk factors for neurodevelopment impairment in twin-twin transfusion syndrome treated with fetoscopic laser surgery. *Obstet Gynecol* 2009;113:361-366.
- 17 Cavicchioni O, Yamamoto M, Robyr R, Takahashi Y, Ville Y: Intrauterine fetal demise following laser treatment in twin-to-twin transfusion syndrome. *BJOG* 2006;113:590-594.
- 18 Yamamoto M, El Murr L, Robyr R, Leleu F, Takahashi Y, Ville Y: Incidence and impact of perioperative complications in 175 fetoscopy-guided laser coagulations of chorionic plate anastomoses in fetofetal transfusion syndrome before 26 weeks of gestation. *Am J Obstet Gynecol* 2005;193:1110-1116.
- 19 Lewi L, Gucciardo L, Huber A, Jani J, Van Mieghem T, Doné E, Cannie M, Gratacós E, Diemert A, Hecher K, Lewi P, Deprest J: Clinical outcome and placental characteristics of monochorionic diamniotic twin pairs with early- and late-onset discordant growth. *Am J Obstet Gynecol* 2008;199:511.e1-511.e7.
- 20 Gratacós E, Lewi L, Muñoz B, Acosta-Rojas R, Hernandez-Andrade E, Martinez JM, Carreras E, Deprest J: A classification system for selective intrauterine growth restriction in monochorionic pregnancies according to umbilical artery Doppler in the smaller twin. *Ultrasound Obstet Gynecol* 2007;30:28-34.
- 21 Quintero RA, Bornick PW, Morales WJ, Allen MH: Selective photocoagulation of the communicating vessels in the treatment of monochorionic twins with selective growth retardation. *Am J Obstet Gynecol* 2001;185:689-696.
- 22 Gratacós E, Antolin E, Lewi L, Martínez JM, Hernandez-Andrade E, Acosta-Rojas R, Enríquez G, Cabero L, Deprest J: Monochorionic twins with selective intrauterine growth restriction and intermittent absent or reversed end-diastolic flow (type III): feasibility and perinatal outcome of fetoscopic placental laser coagulation. *Ultrasound Obstet Gynecol* 2008;31:669-675.
- 23 Karatza AA, Wolfenden JL, Taylor MJ, Wee L, Fisk NM, Gardiner HM: Influence of twin-twin transfusion syndrome on fetal cardiovascular structure and function: prospective case-control study of 136 monochorionic twin pregnancies. *Heart* 2002;88:271-277.
- 24 Robyr R, Yamamoto M, Ville Y: Selective fetocide in complicated monochorionic twin pregnancies using ultrasound-guided bipolar cord coagulation. *BJOG* 2005;112:1344-1348.
- 25 Lewi L, Gratacos E, Ortibus E, Van Schoubroeck D, Carreras E, Higuera T, Perapoch J, Deprest J: Pregnancy and infant outcome of 80 consecutive cord coagulations in complicated monochorionic multiple pregnancies. *Am J Obstet Gynecol* 2006;194:782-789.
- 26 Lopriore E, Middeldorp JM, Oepkes D, Kanhai HH, Walther FJ, Vandebussche FP: Twin anemia-polycythemia sequence in two monochorionic twin pairs without oligo-polyhydramnios sequence. *Placenta* 2007;28:47-51.
- 27 Robyr R, Lewi L, Salomon LJ, Yamamoto M, Bernard JP, Deprest J, Ville Y: Prevalence and management of late fetal complications following successful selective laser coagulation of chorionic plate anastomoses in twin-to-twin transfusion syndrome. *Am J Obstet Gynecol* 2006;194:796-803.
- 28 Kontopoulos EV, Quintero RA: Assessment of the peak systolic velocity of the middle cerebral artery in twin-twin transfusion syndrome. Part I: preoperative assessment. *Am J Obstet Gynecol* 2009;200:61.e1-61.e5.
- 29 Lopriore E, Deprest J, Slaghekke F, Oepkes D, Middeldorp JM, Vandebussche FP, Lewi L: Placental characteristics in monochorionic twins with and without twin anemia-polycythemia sequence. *Obstet Gynecol* 2008;112:753-758.
- 30 Lewi L, Jani J, Cannie M, Robyr R, Ville Y, Hecher K, Gratacos E, Vandecruys H, Vandecaveye V, Dymarkowski S, Deprest J: Intertwin anastomoses in monochorionic placentas after fetoscopic laser coagulation for twin-to-twin transfusion syndrome: is there more than meets the eye? *Am J Obstet Gynecol* 2006;194:790-795.
- 31 van Meir H, Slaghekke F, Lopriore E, van Wijngaarden WJ: Arterio-arterial anastomoses do not prevent the development of twin anemia-polycythemia sequence. *Placenta* 2010;31:163-165.
- 32 Lewi L, Lewi P, Diemert A, Jani J, Gucciardo L, Van Mieghem T, Doné E, Gratacós E, Huber A, Hecher K, Deprest J: The role of ultrasound examination in the first trimester and at 16 weeks' gestation to predict fetal complications in monochorionic diamniotic twin pregnancies. *Am J Obstet Gynecol* 2008;199:493.e1-493.e7.
- 33 Kagan KO, Gazzoni A, Sepulveda-Gonzalez G, Sotiriadis A, Nicolaides KH: Discordance in nuchal translucency thickness in the prediction of severe twin-to-twin transfusion syndrome. *Ultrasound Obstet Gynecol* 2007;29:527-532.
- 34 Sebire NJ, Souka A, Skentou H, Geerts L, Nicolaides KH: Early prediction of severe twin-to-twin transfusion syndrome. *Hum Reprod* 2000;15:2008-2010.
- 35 El Kateb A, Nasr B, Nassar M, Bernard JP, Ville Y: First-trimester ultrasound examination and the outcome of monochorionic twin pregnancies. *Prenat Diagn Ther* 2007;27:922-925.

- 36 Casasbuenas A, Wong AE, Sepulveda W: Nuchal translucency thickness in monochorionic multiple pregnancies: value in predicting pregnancy outcome. *J Ultrasound Med* 2008;27:363–369.
- 37 Sperling L, Kiil C, Larsen LU, Brocks V, Wojdemann KR, Qvist I, Schwartz M, Jørgensen C, Espersen G, Skajaa K, Bang J, Tabor A: Detection of chromosomal abnormalities, congenital abnormalities and transfusion syndrome in twins. *Ultrasound Obstet Gynecol* 2007;29:517–526.
- 38 Matias A, Ramalho C, Montenegro N: Search for hemodynamic compromise at 11–14 weeks in monochorionic twin pregnancy: is abnormal flow in the ductus venosus predictive of twin-twin transfusion syndrome? *J Matern Fetal Neonatal Med* 2005;18:79–86.
- 39 Maiz N, Staboulidou I, Leal AM, Minekawa R, Nicolaides KH: Ductus venosus Doppler at 11 to 13 weeks of gestation in the prediction of outcome in twin pregnancies. *Obstet Gynecol* 2009;113:860–865.
- 40 Matias A, Montenegro N, Loureiro T, Cunha M, Duarte S, Freitas D, Severo M: Screening for twin-twin transfusion syndrome at 11–14 weeks of pregnancy: the key role of ductus venosus blood flow assessment. *Ultrasound Obstet Gynecol* 2010;35:142–148.
- 41 Kagan KO, Valencia C, Livanos P, Wright D, Nicolaides KH: Tricuspid regurgitation in screening for trisomies 21, 18 and 13 and Turner syndrome at 11+0 to 13+6 weeks of gestation. *Ultrasound Obstet Gynecol* 2009;33:18–22.
- 42 Sebire NJ, Talbert D, Fisk NM: Twin-to-twin transfusion syndrome results from dynamic asymmetrical reduction in placental anastomoses: a hypothesis. *Placenta* 2001;22:383–391.