

Cerebrovascular Complications of Neck Manipulation

Maurizio Paciaroni^a Julien Bogouslavsky^b

^aStroke Unit, Division of Cardiovascular Medicine, University of Perugia, Perugia, Italy; ^bDepartment of Neurology and Neurorehabilitation, Swiss Medical Network, Valmont-Genolier, Glion sur Montreux, Switzerland

Key Words

Neck manipulation · Cerebrovascular complications · Artery dissection · Neck pain · Chiropractic therapy

Abstract

The safety of spinal manipulation is an issue that demands regular and rigorous assessment, as manipulation of the upper spine has been associated with serious adverse events such as cerebrovascular accidents due to cervical artery dissection. A correlation between stroke and cervical manipulation has been reported with increasing frequency, and each new report seems to reignite debate between neurologists and manual therapists. Specific risk factors for cerebrovascular complications related to spinal manipulation have not been identified yet; for this reason, any patient may be at risk, particularly those below 45 years of age. Patients undergoing spinal manipulative therapy need to consent to the possible risk of stroke or vascular injury from the procedure.

Copyright © 2008 S. Karger AG, Basel

Introduction

Spinal manipulation entails a range of manual manoeuvres that stretch, mobilize or manipulate the spine, paravertebral tissues and other joints in order to relieve spinal pain and improve locomotor function [1]. In fact,

it is commonly used by osteopaths, physiotherapists and physicians and is the hallmark treatment of manual therapists. Specifically, manual therapists use spinal manipulation regularly to treat low back and other musculoskeletal pain [2]. The safety of spinal manipulation is an issue that requires regular and rigorous assessment, as the manipulation of the upper spine has been associated with serious adverse events such as cerebrovascular accidents.

In this review, we systematically identified and synthesized available data on cerebrovascular adverse events associated with upper spinal manipulation.

Neck Pain and Spinal Manipulation

Neck pain is a common problem associated with considerable comorbidity, disability and cost to society [3, 4], and spinal manipulation is the form of treatment commonly used [5]. Manipulation of the spine differs from mobilization, as it involves a sudden applied thrust that generally cannot be resisted by the patient, whereas mobilization involves a low-velocity, passive movement that can be limited or even halted by the patient [6]. Several systemic reviews have suggested that manual therapy can benefit neck pain [7, 8], but a large and well-designed randomized clinical trial has shown that cervical manipulation was no better than mobilization for acute neck pain [9].

KARGER

Fax +41 61 306 12 34
E-Mail karger@karger.ch
www.karger.com

© 2008 S. Karger AG, Basel
0014-3022/09/0612-0112\$26.00/0

Accessible online at:
www.karger.com/ene

Maurizio Paciaroni
Stroke Unit, Division of Cardiovascular Medicine
Department of Internal Medicine, Santa Maria della Misericordia Hospital
University of Perugia, IT-06100 Perugia (Italy)
Tel./Fax +39 075 578 2765, E-Mail mpaciaroni@med.unipg.it

Approximately 12% of American and Canadian adults seek chiropractic care annually and 80% of these visits result in spinal manipulation [10]. This increasing interest has led to a rapid growth in the number of patients who seek chiropractic care and has also focused attention on neck manipulation by physicians and the government [11]. The estimated 13,000 chiropractors licensed in the United States in 1970 increased to 40,000 by 1990, to approximately 50,000 by 1994, and this latter number is expected to double by the year 2010 [12].

The safety of spinal manipulation requires regular and rigorous control. In particular, manipulation of the upper spine has been associated with serious adverse events such as cerebrovascular accidents, paraplegia, rib fractures and death [13, 14]. Fortunately, the incidence of serious complications is generally considered to be low [15]; however, relatively minor side effects of spinal manipulative therapy are common in clinical practice. According to Senstad et al. [16], side effects are divided into common and uncommon reactions, based on frequency of occurrence. Common reactions can include local discomfort, headache, fatigue and radiating discomfort, while uncommon reactions can include dizziness, nausea and hot skin.

Numerous absolute and relative contraindications of spinal manipulations have been proposed. These include acute fracture, dislocation, ligamentous rupture, instability, tumour, infection, acute myelopathy, cauda equina syndrome, spondylolisthesis, recent surgery, acute soft tissue injury, osteoporosis, ankylosing spondylitis, rheumatoid arthritis, vascular disease (e.g., severe atherosclerosis), vertebral artery abnormalities (e.g., in patients with Klippel-Feil), connective tissue disease (e.g., Marfan, Ehlers-Danlos type IV), anticoagulant therapy, and bleeding dyscrasia [17–19]. The inclusion of the presence of a herniated disc in this list of relative and absolute contraindications to spinal manipulation is controversial. Patients with significant disc herniations are likely at higher risk of complications after spinal manipulation. Cervical spinal manipulation therapy may worsen pre-existing cervical disc herniation or cause disc herniation resulting in radiculopathy, myelopathy or vertebral artery compression [20]. The risk of manipulation causing a symptomatic herniation in a previously asymptomatic patient has been reported [21]. In a series of 18 patients who received spinal manipulation with neurological complication, 3 patients presented with symptoms that were distant from the site of their subsequent manipulation and developed complications at the manipulated site, rather than at the site of original complaint. This

strongly suggests that their complications were associated with de novo injuries directly related to the manipulation itself, rather than due to an exacerbation of pre-existing pathology [22]. Conversely, another study found that after repeat magnetic resonance imaging (MRI) scans, 63% of the patients treated with spinal manipulation had a reduced size or completely resorbed disc herniation [23]. In cases of cervical spondylosis, spinal manipulation may also worsen pre-existing myelopathy or radiculopathy. Therefore, it may be reasonable and appropriate to recommend MRI or computed tomography imaging to rule out the presence of either significant disc herniations or cervical spondylosis before any spinal manipulation.

Cerebrovascular Complications of Neck Manipulation

Manual cervical spine manipulations have been reported to result in cerebrovascular insults, primarily due to dissection of the vertebral artery [24]. These patients usually present symptoms and signs of sudden neck pain onset and/or vertebrobasilar ischaemia. The interval between chiropractic manipulation and symptom onset is variable; while approximately half of the patients have an acute onset during or immediately after manipulation, some patients present to the hospital several hours or even several days after the manipulation [13, 25–29]. Rossetti et al. [30] described 6 patients with artery dissections (5 vertebral artery dissections and 1 carotid artery dissection combined with vertebral artery dissection) after neck manipulation. The interval between chiropractic manipulation and symptom onset ranged from 10 to >30 h.

In 1934, a medical legal abstract first noted cerebrovascular accidents after cervical spine manipulation [31]. An association between stroke and cervical manipulation has been reported with increasing frequency, and each new report seems to reignite debate between neurologists and chiropractors [32].

The principal involvement of the vertebral artery could be due to the anatomy of this artery which may suffer torsion injury as it curves around the atlas (fig. 1). This artery changes its direction from a vertical to a horizontal path and is therefore very likely susceptible to injury from rotation and extension [33]. The proximity of the vertebral artery to the C1 and C2 vertebral bodies may play a crucial role in the development of dissection. The V1 and V3 segments of the vertebral artery are the most mobile. This may be the reason why the V3 segment is a frequent

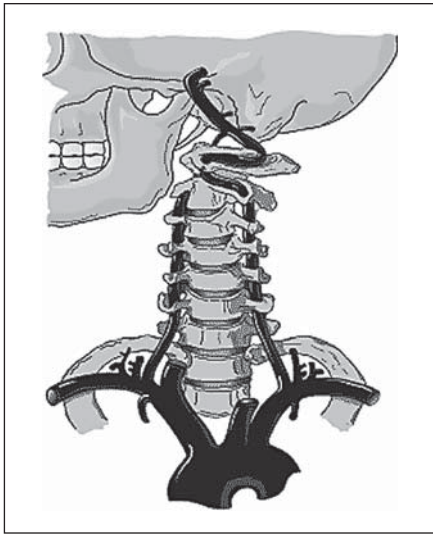


Fig. 1. Mechanism of injury of the vertebral arteries in motor vehicle crashes or with chiropractic manipulation. From Spence JD (ed): *How to Prevent Your Stroke* [69]. © 2006 Vanderbilt University Press. Reproduced by permission.

site of dissection, although dissection can occur in any segment of the artery [34] (fig. 2).

The cervical internal carotid artery is less frequently injured than the vertebral artery during chiropractic manoeuvres, probably because it lies freely in the soft tissue of the neck and is thus more mobile. It is assumed that internal carotid artery dissection during chiropractic manipulation results from compression of the artery against either the transverse processes or the bony mass of the upper cervical vertebrae. The pharyngeal segment of the internal carotid artery extending from the carotid bifurcation to its entry at the petrous portion of the temporal bone is mobile, and therefore susceptible to injury.

Several reports and case-control studies have associated manual therapy of the neck and cervical artery dissection involving one or more arteries contemporarily [19, 26–28, 30, 33, 35–48]. The first-ever reported case of vertebral artery dissection due to chiropractic manipulation was described in 1947 [39]. Later studies have sug-

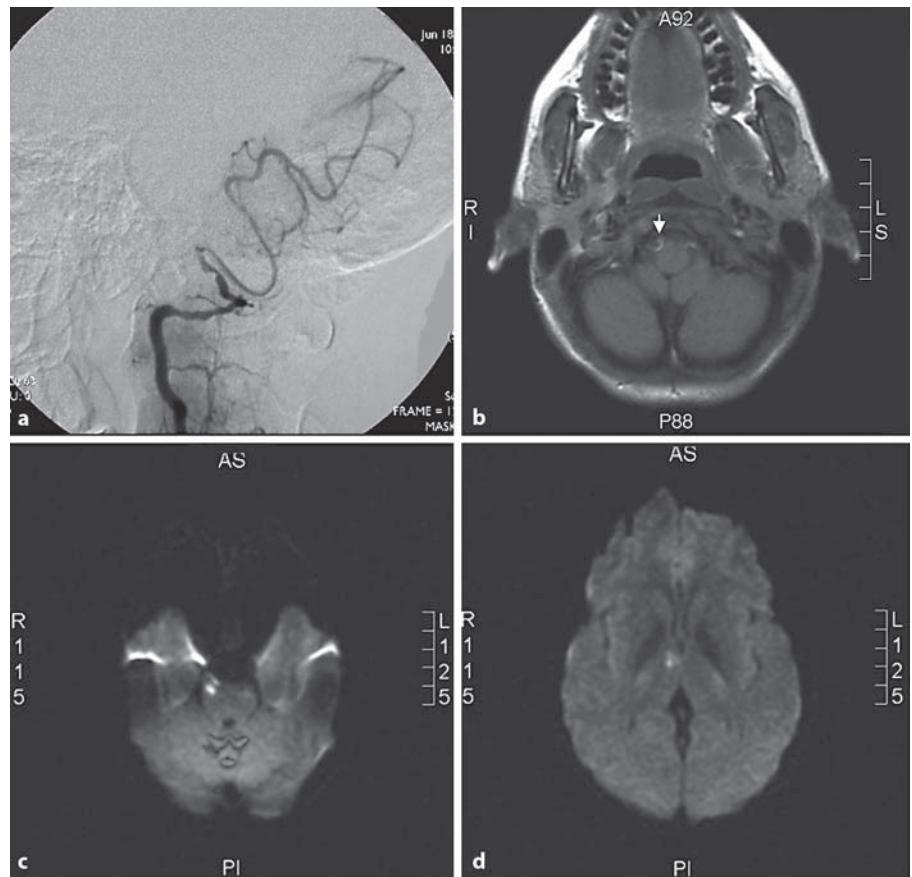


Fig. 2. Dissection of the right vertebral artery on cerebral angiography (a) and MRI (b) with right ischaemic lesions in the pons and thalamus on diffusion-weighted imaging sequences (c, d).

gested stroke rates ranging from 1 in 100,000 to 1 in 2,000,000 cervical manipulations [2, 26, 27]. A large population-based, nested case-control study in Ontario, Canada, reported a positive association between vertebral artery dissection or occlusion and chiropractic manipulation in adults younger than 45 years of age, but not for those older [27]. Since younger people are more likely to have dissection as a cause of stroke [49] and are more likely to visit a chiropractor [50], age should be considered as a possible confounding factor. Smith et al. [26] identified patients with dissection and vertebrobasilar stroke from a prospective stroke registry and assigned stroke etiology in a blind and systematic fashion. The authors compared controls matched for age and sex from the same registry and interviewed all subjects to determine the timings of both neck pain and cervical manipulation. In multivariate analysis, vertebral artery dissection was independently associated with spinal manipulative therapy within 30 days (OR 6.62; 95% CI 1.4–30). However, patients treated with cervical manipulation showed a trend to be younger than the controls.

However, it is still controversial whether manual therapy of the cervical spine is truly associated with an increased risk of cervical artery dissection, and there has also been significant disagreement between neurologists and manual therapists regarding the issue [51, 52]. In fact, practitioners of manipulation, irrespective of their professional training (medicine, osteopathy, physical or chiropractic therapy), have consistently claimed that the risk of stroke after manipulation is so small that it should be considered insignificant [53–55]. All of the current evidence in favour of this association has been derived from case series, survey questionnaires or retrospective case-control studies; however, none of these have had high levels of evidence. Furthermore, a causal relationship may occasionally appear ambiguous [56]. A recent case-control and case-crossover study confirmed an association between chiropractic care and vertebral artery dissection resulting in vertebrobasilar stroke [57]. But this latter study also found a strong association between primary care physician visits and subsequent vertebrobasilar stroke. The authors hypothesized that patients with head and neck pain due to vertebral artery dissection seek care for these symptoms, which precede more than 80% of vertebrobasilar strokes [58]. Since it is unlikely that primary care physicians can cause stroke while caring for these patients, the authors assumed that the observed association between a recent primary care physician visit and vertebrobasilar stroke represents the background risk associated with patients seeking care for dissection-related

symptoms that eventually lead to vertebrobasilar stroke. Because the association between chiropractic visits and vertebrobasilar stroke is not greater than the association between primary care physician visits and vertebrobasilar stroke, the authors concluded that there was no excess risk of vertebrobasilar stroke from chiropractic care. Halderman et al. [59] in their study concluded that the perceived risk after cervical manipulation by chiropractors and neurologists is related to a selection or referral bias: each patient who has a stroke after manipulation will likely be seen by only 1 chiropractor but by 3 or more neurologists and this could partially explain the difference in the perceptions of risk that these 2 professions have.

There are several activities other than cervical spinal manipulation that may cause minor trauma to the arteries in the neck and that are associated with cervical artery dissection and stroke [60]. Cervical artery dissections due to whiplash injury during a car accident, falls, bicycle accidents, horse riding injuries and sport activities may have similarities and dissimilarities with cervical artery dissection due to spinal manipulation [61] (fig. 1). Both neck manipulation and motor vehicle collision events rapidly apply loads to the spinal column. While neck manipulation loads are slower to develop and displacements smaller, they may reach peak amplitude on maximum effort comparable with those seen in low-velocity collision experiments. Whiplash injury is principally due to a flexion-extension trauma while chiropractic manipulation principally determines a rotational trauma. Flexion-extension trauma is more likely to injure the carotid arteries, whereas rotational trauma more often injures the vertebral arteries [62, 63]. Cervical artery dissection after whiplash is uncommon, but its incidence has increased over the last years [64], and careful note should be made of patients for early recognition of this disorder.

Risk Factors for Cerebrovascular Complications during Neck Manipulation

Some therapists have started advocating screening patients for risk factors before treatment. Based on post-mortem studies of human vertebral arteries, Cagnie et al. [65] have suggested that, in the presence of arteriosclerotic changes, the stretching and compression effects of rotational manipulation may constitute a risk factor for vascular accidents. These authors concluded that ‘therapists should avoid manipulative techniques at all levels of the cervical spine in the presence of any indirect signs of arteriosclerotic disease or in presence of calcified arterial

walls or tortuosities of the vessel'. Doppler ultrasound screening seems capable to provide an indirect assessment of the mechanical stresses to the artery during cervical movements, even if absolute proof that Doppler ultrasound examination of vertebral arteries in pre-manipulative screening can identify patients at risk of stroke after manipulation is unavailable at present [66]. Other authors have suggested that high homocysteine levels constitute a risk factor for arterial dissection [67], while others have claimed that the presence of anatomic variations of the cervical vessels are associated with arterial dissection [43]. Therefore, spinal manipulation might be contraindicated in such individuals. However, the effectiveness of screening has not been convincingly demonstrated, and Haldeman et al. [68] concluded that cerebrovascular accidents after manipulation appear to be unpredictable and should be considered inherent, idiosyncratic and rare complications of this treatment approach.

To date, there has been no reported relationship between the type of manual therapy and risk of stroke, as stroke symptoms have been reported to begin immediately after the first manipulation or several treatments. Some authors have found no relation between the number of chiropractic manipulations and the incidence of cervical artery dissection. In patients with neck manipulation, strokes have been reported to occur after any form of standard cervical manipulation technique including rotation, extension, lateral flexion and non-forced and neutral position manipulations.

Conclusions and Key Points

- (1) There is little evidence on the specific beneficial therapeutic effects of spinal manipulation.

References

- 1 Ernst E: Spinal manipulation: its safety is uncertain. *Can Med Assoc J* 2002;166:40–41.
- 2 Hurwitz EL, Coulter ID, Adams AH, Genovese BJ, Shekelle PG: Use of chiropractic services from 1985 through 1991 in the United States and Canada. *Am J Public Health* 1998; 88:771–776.
- 3 Borghouts JA, Koes BW, Vondeling H, et al: Cost-of-illness of neck pain in the Netherlands in 1996. *Pain* 1999;80:629–636.
- 4 Côté P, Cassidy JD, Carroll LJ, et al: The annual incidence and course of neck pain in the general population: a population-based cohort study. *Pain* 2004;112:267–273.
- 5 Côté P, Cassidy JD, Carroll L: The treatment of neck and low back pain: who seeks care? Who goes where? *Med Care* 2001;39:956–967.
- 6 Stevinson C, Ernst E: Risks associated with spinal manipulation. *Am J Med* 2002;112: 566–570.
- 7 Gross AR, Kay T, Hondras M, et al: Manual therapy for mechanical neck disorders: a systematic review. *Man Ther* 2002;7:131–149.
- 8 Gross AR, Hoving JL, Haines TA, Goldsmith CH, Kay T, Aker P, Bronfort G; Cervical Overview Group: A Cochrane review of manipulation and mobilization for mechanical neck disorders. *Spine* 2004;29:1541–1548.
- 9 Hurwitz L, Morgenstern H, Harber P, Kominski GF, Yu F, Adams AH: A randomized trial of chiropractic manipulation and mobilization for patients with neck pain: clinical outcomes from the UCLA neck-pain study. *Am J Public Health* 2002;92:1634–1641.

- (2) Evidence shows an association between spinal manipulation and mild adverse effects as well as with serious complications including dissection of cervical arteries most commonly involving the vertebral arteries.
- (3) Specific risk factors for cerebrovascular complications such as cervical artery dissection and stroke related to spinal manipulation have not been identified yet. For this reason any patient may be at risk, particularly those younger than 45 years.
- (4) Patients undergoing spinal manipulative therapy should be informed of the risk of stroke or vascular injury from this procedure.
- (5) The diagnosis of a cerebrovascular complication should be seriously taken into consideration in patients presenting with recent onset vertigo and loss of balance, and anamnesis should inquire about any recent spinal manipulations.
- (6) Further research is required to examine both the possible benefits and harms associated with cervical spine manipulation.

Search Strategy and Selection Criteria

Data for this review were identified by searching PubMed for single or combined terms including: neck manipulation, stroke, manual therapy, chiropractic manipulation, spinal manipulation, spinal manipulative therapy, artery dissection, carotid dissection, vertebral dissection, neck pain, cerebrovascular complications, risk factors, disk herniation, whiplash injury. Original research papers, clinical series, case reports and reviews were included. Our research covered all relevant data to 1 June 2008.

- 10 Hurwitz EL, Chiang LM: A comparative analysis of chiropractic and general practitioner patients in North America: findings from the joint Canada/United States Survey of Health, 2002–03. *BMC Health Serv Res* 2006;6:49.
- 11 Cherkin DC, Mootz RD: Chiropractic in the US: training, practice, and research. AHCPR publication No. 98-N002. Rockville, Agency for Health Care Policy and Research, 1997.
- 12 Coulter ID, Shekelle PG: Supply, distribution and utilization of chiropractic services in the United States; in Cherkin DC, Mootz RD (eds): Chiropractic in the US: training, practice, and research. AHCPR publication No. 98-N002. Rockville, Agency for Health Care Policy and Research, 1997.
- 13 Stevinson C, Honan W, Cooke B, Ernst E: Neurological complications of cervical spine manipulation. *J R Soc Med* 2001;94:107–110.
- 14 Vohra S, Johnston BC, Cramer K, Humphreys K: Adverse events associated with pediatric spinal manipulation: a systematic review. *Pediatrics* 2007;119:e275–e283.
- 15 Cagnie B, Vink E, Beernaert A, Cambier D: How common are side effects of spinal manipulation and can these side effects be predicted? *Man Ther* 2004;9:151–156.
- 16 Senstad O, Leboeuf-Yde C, Borchgrevink C: Predictors of side effects to spinal manipulation therapy. *J Manipulative Physiol Ther* 1996;19:441–445.
- 17 Schmidley JW, Kock T: The noncerebrovascular complications of chiropractic manipulation. *Neurology* 1984;34:684–685.
- 18 Sturzenegger M: Dissektion der Arteria vertebralis nach Manipulation der Halswirbelsäule. *Schweiz Med Wochenschr* 1993;123:1389–1399.
- 19 Assendelft WJ, Bouter LM, Knipschild PG: Complication of spinal manipulation. A comprehensive review of the literature. *J Fam Pract* 1996;42:475–480.
- 20 Malone DG, Baldwin NG, Tomecek FJ, Boxell CM, Gaede SE, Covington CG, Kugler KK: Complications of cervical spine manipulation therapy: 5-year retrospective study in a single-group practice. *Neurosurg Focus* 2002;13:ecp1.
- 21 Malmivaara A, Pohjola R: Cauda equina syndrome caused by chiropraxis on a patient previously free of lumbar spine symptoms. *Lancet* 1982;ii:986–987.
- 22 Oppenheim JS, Spitzer DE, Segal DH: Non-vascular complications following spinal manipulation. *Spine J* 2005;5:660–667.
- 23 BenElياهو DJ: Magnetic resonance imaging and clinical follow-up: study of 27 patients receiving chiropractic care for cervical and lumbar disc herniations. *J Manipulative Physiol Ther* 1996;19:597–606.
- 24 Caso V, Paciaroni M, Bogousslavsky J: Environmental factors and cervical artery dissection; in Baumgartner R, Bogousslavsky J, Caso V, Paciaroni M (eds): *Handbook on Cerebral Artery Dissection*. Basel, Karger, 2005, pp 44–53.
- 25 Dziejewski R, Konrad C, Drager B, et al: Cervical artery dissection – clinical features, risk factors, therapy and outcome in 126 patients. *J Neurol* 2003;250:1179–1184.
- 26 Smith WS, Johnston SC, Skalabrini EJ, Weaver M, Azari P, Albers GW, Gress DR: Spinal manipulation therapy is an independent risk factor for vertebral artery dissection. *Neurology* 2003;60:1424–1428.
- 27 Rothwell DM, Bondy SJ, Williams JL: Chiropractic manipulation and stroke: a population-based case-control study. *Stroke* 2001;32:1054–1060.
- 28 Hufnagel A, Hammers A, Schonle PW, Bohm KD, Leonhardt G: Stroke following chiropractic manipulation of the cervical spine. *J Neurol* 1999;246:683–688.
- 29 Nazir FS, Muir KW: Prolonged interval between vertebral artery dissection and ischemic stroke. *Neurology* 2004;62:1646–1647.
- 30 Rossetti AO, Combremont PC, Bogousslavsky J: Manipulations cervicales et dissection arterielle. *Schweiz Arch Neurol Psychiatr* 2000;151:247–252.
- 31 Thornton FV: Malpractice: death resulting from chiropractic treatment of headache (medicolegal abstract). *JAMA* 1934;103:1260.
- 32 Kapral MK, Bondy SJ: Cervical manipulation and risk of stroke. *Can Med Assoc J* 2001;165:907–908.
- 33 Norris JW, Beletsky V, Nadareishvili ZG: The Canadian Stroke Consortium. Sudden neck movement and cervical artery dissection. *Can Med Assoc J* 2000;163:38–40.
- 34 Paciaroni M, Caso V, Agnelli G: Magnetic resonance imaging, magnetic resonance and catheter angiography for diagnosis of cervical artery dissection; in Baumgartner R, Bogousslavsky J, Caso V, Paciaroni M (eds): *Handbook on Cerebral Artery Dissection*. Basel, Karger, 2005, pp 54–63.
- 35 Frisoni GB, Anzola GP: Vertebrobasilar ischemia after neck motion. *Stroke* 1991;22:1452–1460.
- 36 Haldeman S, Kohlbeck FJ, McGregor M: Risk factors and precipitating neck movements causing vertebrobasilar dissection after cervical trauma and spinal manipulation. *Spine* 1999;24:785–794.
- 37 Haldeman S, Kohlbeck FJ, McGregor M: Stroke, cervical artery dissection and cervical spine manipulation therapy. *J Neurol* 2002;249:1098–1104.
- 38 Yu NR, Eberhardt RT, Menzoian JO, Urlick CL, Raffetto JD: Vertebral artery dissection following intravascular catheter placement: a case report and review of the literature. *Vasc Med* 2004;9:199–203.
- 39 Bratt-Thomas HR, Berger HR: Cerebellar and spinal injuries after chiropractic manipulation. *JAMA* 1947;133:600–603.
- 40 Frumkin LR, Baloh RW: Wallenberg's syndrome following neck manipulation. *Neurology* 1990;40:611–615.
- 41 Mas JL, Boussier MG, Hasboun D, Laplane D: Extracranial vertebral artery dissections: a review of 13 cases. *Stroke* 1987;18:1037–1047.
- 42 Saeed AB, Shuaib A, Al-Sulaiti G, Emery D: Vertebral artery dissection: warning symptoms, clinical features and prognosis in 26 patients. *Can J Neurol Sci* 2000;27:292–296.
- 43 Sedat J, Did M, Mahagne MH, Lonjon M, Paquis P: Stroke after chiropractic manipulation as a result of extracranial postero-inferior cerebellar artery dissection. *J Manipulative Physiol Ther* 2002;25:588–590.
- 44 Williams S, Biller J: Vertebrobasilar dissection and cervical spine manipulation. *Neurology* 2003;60:1408–1409.
- 45 Chen WL, Chern CH, Wu YL, Lee CH: Vertebral artery dissection and cerebellar infarction following chiropractic manipulation. *Emerg Med J* 2006;23:e1–e2.
- 46 Ernst E: Adverse effects of spinal manipulation: a systematic review. *J R Soc Med* 2007;100:330–338.
- 47 Gouveia LO, Castanho P, Ferreira JJ, Guedes MM, Falcao F, Melo TP: Chiropractic manipulation: reasons for concern? *Clin Neurol Neurosurg* 2007;109:922–925.
- 48 Nadgir RN, Loevner LA, Ahmed T, Moonis G, Chalela J, Slawek K, Imbesi S: Simultaneous bilateral internal carotid and vertebral artery dissection following chiropractic manipulation: case report and review of the literature. *Neuroradiology* 2003;45:311–314.
- 49 Bogousslavsky J, Despland PA, Regli F: Spontaneous bilateral internal carotid and vertebral artery dissection with acute stroke. *Arch Neurol* 1987;44:137–140.
- 50 Coulter ID, Hurwitz EI, Adams AH, Benovese BJ, Hays R, Shekelle PG: Patients using chiropractors in North America: who are they and why are they in chiropractic care? *Spine* 2002;27:291–296.
- 51 Inamasu J, Guiot BH: Iatrogenic vertebral artery injury. *Acta Neurol Scand* 2005;112:349–357.
- 52 Rubenstein SM, Peerdeman SM, van Tulder MW, Riphagen I, Haldeman S: A systematic review of the risk factors for cervical artery dissection. *Stroke* 2005;36:1575–1580.
- 53 Dabbs V, Lauretti WJ: A risk assessment of cervical manipulation versus NSAIDs for the treatment of neck pain. *J Manipulative Physiol Ther* 1995;18:530–553.
- 54 Zimmerman AW, Kumar AJ, Gadoth N, Hodges FJ: Traumatic vertebrobasilar occlusive disease in childhood. *Neurology* 1978;28:185–188.
- 55 Cohn A: A review of the literature regarding stroke and chiropractic. *J Vertebral Subluxation Res* 2001;4:52–59.

- 56 Rubenstein SM, Haldeman S: Cervical manipulation to a patient with a history of traumatically induced dissection of the internal carotid artery: a case report and review of the literature on recurrent dissections. *J Manipulative Physiol Ther* 2001;24:520–525.
- 57 Cassidi JD, Boyle E, Côté P, He Y, Hogg-Johnson S, Silver FL, Bondy SJ: Risk of vertebrobasilar stroke and chiropractic care. *Spine* 2008;33:S176–S183.
- 58 Lee VH, Brown RD JR, Mandrekar JN, et al: Incidence and outcome of cervical artery dissection: a population-based study. *Neurology* 2006;67:1809–1812.
- 59 Haldeman S, Carey P, Townsend M, Papadopoulos C: Clinical perceptions of the risk of vertebral artery dissection after cervical manipulation: the effect of referral bias. *Spine J* 2002;2:334–342.
- 60 Chung YS, Han DH: Vertebrobasilar dissection: a possible role of whiplash injury in its pathogenesis. *Neurol Res* 2002;24:129–138.
- 61 Haneline M, Triano J: Cervical artery dissection. A comparison of highly dynamic mechanisms: manipulation versus motor vehicle collision. *J Manipulative Physiol Ther* 2005;28:57–63.
- 62 Inamasu J, Guiot BH: Vertebral artery injury after blunt cervical trauma: an update. *Surg Neurol* 2006;65:238–245.
- 63 Janjua KJ, Goswami V, Sagar G: Whiplash injury associated with acute bilateral internal carotid arterial dissection. *J Trauma* 1996;40:456–458.
- 64 Nedeltchev K, Baumgartner R: Traumatic cervical artery dissection; in Baumgartner R, Bogousslavsky J, Caso V, Paciaroni M (eds): *Handbook on Cerebral Artery Dissection*. Basel, Karger, 2005, vol 20, pp 54–63.
- 65 Cagnie B, Barbaix E, Vinck E, D’Herde K, Cambier D: Atherosclerosis in the vertebral artery; an intrinsic risk factor in the use of spinal manipulation? *Surg Radiol Anat* 2006;28:129–134.
- 66 Haynes MJ: Vertebral arteries and cervical movement: Doppler ultrasound velocimetry for screening before manipulation. *J Manipulative Physiol Ther* 2002;25:556–567.
- 67 Pezzini A, Del Zotto E, Padovani A: Hyperhomocysteinemia: a potential risk factor for cervical artery dissection following chiropractic manipulation of the cervical spine. *J Neurol* 2002;249:1401–1403.
- 68 Haldeman S, Kohlbeck FJ, McGregor M: Unpredictability of cerebrovascular ischemia associated with cervical spine manipulation therapy. *Spine* 2002;27:49–55.
- 69 Spence JD, Hackman D: Strokes from neck injury; in Spence JD (ed): *How to Prevent Your Stroke*. Nashville, Vanderbilt University Press, 2006.