

Neurological Deficits in the Life and Works of Frida Kahlo

Valmantas Budrys

Clinics of Neurology and Neurosurgery, Faculty of Medicine, Vilnius University, Vilnius, Lithuania

I never painted dreams. I painted my own reality.
Frida Kahlo

Key Words

Neurology and art · Frida Kahlo · Spina bifida ·
Poliomyelitis · Spine injury · Neuropathic pain

Abstract

World-famous Mexican painter Frida Kahlo is an impressive example of an artist whose entire life and creativity were extremely influenced by chronic, severe illness. Many of her best-known works depict her physical and mental suffering. She was one of those very uncommon artists who dared to show their nude, sick body. This article describes biographical events and works of Frida Kahlo that are closely related to neurology: congenital anomaly (spina bifida), poliomyelitis, spine injury, neuropathic pain.

Copyright © 2006 S. Karger AG, Basel

All paintings but figure 4 are reproduced with the kind permission of the Banco de México Diego Rivera & Frida Kahlo Museums Trust, Mexico.

Introduction

Mexican painter Frida Kahlo (1907–1954) almost attained cult status for her extraordinary life and art. Tempestuous life-long love to prominent Mexican artist Diego Rivera, love affairs, infidelity, divorce and remarriage, several miscarriages, years of being bedridden or wheelchair bound, intractable pain and multiple unsuccessful operations defined this great artist's talent. Interest in her works has dramatically increased, and nowadays Frida Kahlo ranks among the world's most renowned 20th century female artists. Her deeply and even painfully personalized surrealist paintings fascinate art lovers around the world.

It is difficult to find an artist whose life and works were more deeply affected by illness than Frida Kahlo's. Her art is permeated by her struggle against medical hardships; physical and psychical suffering lay at the heart of her talent [1]. She was one of those very uncommon artists who dared to show their nude, sick body. Many of her best-known works depict her physical suffering: her bleeding, broken and weeping body. Her paintings and drawings are like medical case reports. Interestingly, most of her maladies were related to neurology.

Spina Bifida

One could say that neurological problems in Frida Kahlo's life started even before she was born in Coyoacán (a suburb of Mexico City) in 1907. The third daughter of a Mexican mother and German father was born with a congenital anomaly: spina bifida, i.e. nonfusion of the laminae of the spinal arches. This abnormality (a form of dysraphism) develops due to a defect in the formation of the primitive neural tube during the first 4 weeks of the intrauterine period. Depending on the severity of the fusion defect, spina bifida may be asymptomatic or present with different skeletal, urogenital and neurological manifestations, including deformation and trophic disorders of extremities (e.g. clubfeet), motor paresis and others [2].

What do we know about spina bifida in Frida Kahlo's case? Her biographical essays usually completely ignore her malformation or merely mention it in passing. This is nothing unusual: as is often the case in patients with congenital defects, Frida Kahlo preferred to blame her leg problems on some external causes that took place during her life; poliomyelitis and trauma. Most of her doctors underestimated spina bifida, too. However, it is very likely that almost all of her life-long spine and leg problems related to spina bifida.

Her doctor and friend, famous American surgeon Leo Eloesser (she met him in San Francisco in 1930), noticed and properly evaluated Frida Kahlo's spine anomaly: 'X-rays showed a spina bifida, the decreased sensitivity in the lower part of her body was characteristically compatible with this disorder. Her disability grew and various operations to her right foot and leg made matters worse. To hide the disorder she wore long starched Mexican shirts' [quoted from 3].

There are no surviving medical documents specifying the defect, but we do have the remarkable Frida Kahlo painting 'What I saw in the water' (fig. 1), illustrating various events from her life. The painting's dominant element is a pair of feet sticking out of the bathtub water. We can clearly see the bleeding sore between the deformed big and second toes of the right foot, a typical defect accompanying congenital dysraphisms, including spina bifida. Do the small portraits of Frida Kahlo's parents in the painting allude to her congenital defect? Who could deny it, the same as nobody would deny the mystical providence (impossible not to be related to Frida Kahlo's disease) of the burning skyscraper?

Poliomyelitis

In Frida Kahlo's biographies, the earliest documented handicap is poliomyelitis (polio). Frida Kahlo caught polio in 1913, aged six, and had to spend several months in bed. The paralytic form of the disease was not badly disabling, however it did have some unavoidable consequences – her right leg remained slightly deformed and shorter than her left leg, so that she had to wear built-up shoes. Other children teased her about her 'peg leg' and this physical defect had a considerable psychological impact on an already energetic and rebellious child.

That polio was the only cause of Frida Kahlo's leg and toe deformity is doubtful. More likely, the poliomyelitis only heightened an already existing slight congenital leg defect that became more notable as the child grew up, so her right leg problems were probably due to the combined effect of both conditions.

Frida Kahlo's right leg became visibly damaged. Moreover, trophic ulcers started to appear and, together with the deformity, were a source of considerable discomfort and pain. 'My foot is still ill – trophic ulcers, what is that?', she later wrote in her diary [3]. The drawing sketched in 1931 during her 4-year stay in the USA (where Frida Kahlo, already married to Diego Rivera, had moved to for artistic and political reasons) depicts a bandaged, ulcerated right leg (fig. 2). From 1934 onwards, several unsuccessful and unnecessary operations on her foot and leg were performed that eventually led to gangrene and amputation of the leg below the knee in 1953, shortly before Frida Kahlo's death. How provident the work of Diego Rivera, painted 10 years before (1943): a little boy with the face of Diego Rivera sadly examines a doll with a detached right leg (fig. 3).

Spine Injury

In 1925, aged 18, Frida Kahlo survived a tram crash which profoundly changed her life. Due to multiple traumas – her spine was injured in several places, the right(!) foot and leg broken and her pelvis badly damaged by a piece of metal handrail (one of the reasons she was unable to carry a child to term) – she was confined to bed for 3 months. A small pencil sketch drawn by Kahlo in 1926 depicts her in this fateful accident (fig. 4). Despite the displacement of several vertebrae (later documented by X-ray), the spinal cord seemingly was undamaged and no serious peripheral nerve lesions were detected. After initially seeming to make a full recovery, Kahlo began to



Fig. 1. Frida Kahlo. What I saw in the water, 1938. Collection Daniel Filipacchi, Paris.




Fig. 2. Frida Kahlo. Self-portrait, sitting, 1931. Collection Teresa Proenza, Mexico City.



Fig. 3. Diego Rivera. Sunflowers, 1943.

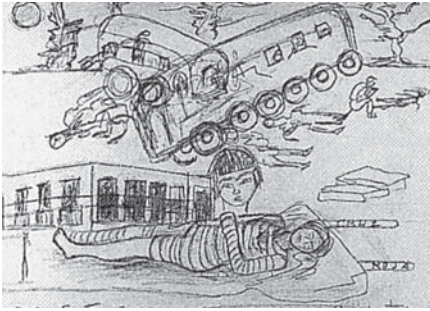


Fig. 4. Frida Kahlo. Accident, 1926. Collection Juan Rafael Coronel Rivera, en promesa de donación al Museo Nacional de Arte.




Fig. 5. Frida Kahlo working in bed, 1952. Photo by Juan Guzman.

suffer from frequent pain in her spine and right foot. She also felt permanently tired. An X-ray examination performed 1 year after the accident revealed a number of displaced vertebrae. She was readmitted to hospital and for several months had to wear plaster corsets that considerably restricted her mobility [4].

Being confined to bed for a long time and trying to escape from boredom and pain, she asked her father for his box of oil paints and some paintbrushes (he sometimes painted landscapes). A special easel was arranged for her so that she could paint lying down, and painting became her way to cope with being bedridden. 'I felt I still had enough energy to do something other than studying to be-

come a doctor. Without giving it any particular thought, I started painting' [quoted from 4]. The trauma deeply affected Frida Kahlo's life. She gave up her medical studies and joined the Mexican Communist Party in 1928, where she met Diego Rivera (also a member of the Communist Party) and developed a live-long passionate love for him. One year later they got married for the first time.

A photograph of Frida Kahlo taken 2 years before her death (fig. 5) shows her in the very same position in which she started off as a painter after the fateful accident. Symbolically, the photograph frames her artistic life, which began and finished lying in bed with a special easel and a paintbrush in hand.

One of the most shattering artistic testimonies of the impact of the spinal trauma on her continuous suffering is a self-portrait with a broken column (fig. 6). In 1944, when Frida Kahlo painted this masterpiece, her health had deteriorated to the point where she, unable to sit upright without being tied to the back of a chair, was encased in a steel corset to support her spine. Her spinal column, represented as an ancient pillar broken in several places, plenty of nails sticking into her naked body (note the nails going down the right side of the blanket covering the lower part of her body), and the fissured, dry, bare landscape became a symbol of the artist's pain and solitude. Though very impressive, this famous painting, stressing the broken spinal column as the main source of her excruciating pain and suffering, overestimates the role of the spinal column injury from a neurological point of view. It is noteworthy that medical professionals later also overestimated her injuries, performing numerous unnecessary operations.

During 1946–1950 Frida Kahlo underwent 8 operations to her spine. The first of them was performed in the USA in June 1946, and Kahlo describes it in a letter to her old friend Alejandro Gomez Arias: 'So the big operation is now behind me. [...] I have two huge scars on my back in this shape' [quoted from 4]. The same scars from the incisions 'which those surgeon sons of bitches landed me with' Frida Kahlo depicted in her self-portrait named 'Tree of Hope. Keep firm' (fig. 7). The shape of the two scars reveals the unusual complexity of this first operation.

Following her discharge from hospital after the last operation in 1951, Frida Kahlo was confined to a wheelchair for most of the time. From then on she regularly had to take painkillers.




Fig. 6. Frida Kahlo. The broken column, 1944. Collection Dolores Olmedo, Mexico City.



Fig. 7. Frida Kahlo. Tree of hope. Keep firm, 1946. Collection Daniel Filipacchi, Paris.

Pain

Lingering pain in the right foot, leg and back accompanied Frida Kahlo for almost all her life, reaching its peak in the last decade of her life. What kind of pain did she suffer? What were the causes of this excruciating malady? Undoubtedly, neuropathic pain has several sources.

Congenitally and probably as a consequence of the polio infection, Kahlo's crippled leg and toe deformity were the source of recurrent foot skin sores, infections, chronic ulceration (finally ending in foot gangrene and amputation) and pain. Her congenitally abnormal spinal column, leg deformity, the displacement of several vertebrae after the traffic accident, her a-dynamic spinal muscle atrophy due to prolonged use of orthopedic corsets led to spinal column instability, chronic asymmetrical overstretching of the spinal muscles and back pain.

Another important source of the chronic pain in her right leg directly relates to the traffic accident in 1925. The documented displacement of several vertebrae could be and probably was a cause of early post-traumatic albeit transient radicular pain. Interestingly and essentially, the obvious worsening of the pain in her spine and right leg was documented only several months after an initially seemingly full recovery. Together with the other factors, this strongly suggests post-traumatic causalgia (complex regional pain syndrome type II) or another closely related syndrome, reflex sympathetic dystrophy (RSD; complex regional pain syndrome type I). The principal difference between these two syndromes is a peripheral nerve injury in the case of causalgia. The fact that no clear signs of peripheral nerve injury after the accident are documented argues in favor of RSD. The pathogenesis of RSD is not completely understood. Though RSD

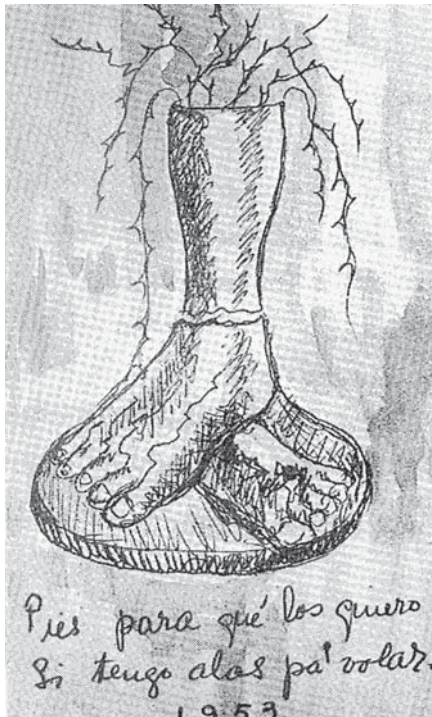

Fig. 8. Page from Frida Kahlo's diary, 1953. Museo Frida Kahlo, Mexico City.

is more common in mid life it occurs at all ages and women account for about 70% of cases [5]. An individual predisposition to RSD also plays a role. RSD usually develops within days or months after even minor traumatic tissue injury, bone fracture, surgical intervention or prolonged immobilization, and Frida Kahlo had experienced them all. RSD is a syndrome with variable major components of burning, aching, shooting pain, autonomic dysfunction, edema, dystrophy and atrophy of the mostly distal part (hand, foot) of the affected extremity, and sometimes restricted movement. The pain usually spreads diffusely from the site of the injury, potentially involving both or even all four extremities and is commonly associated with hyperalgesia, allodynia, and hyperpathia. RSD patients are often depressed and anxious [5, 6]. In summary, Frida Kahlo was affected by virtually all of these signs and a diagnosis of RSD as the key source of her permanent intractable pain is very credible. Different kinds of conservative and surgical treatment usually have (and had) an only partial and short-lived effect.

Her intractable pain provoked numerous unsuccessful and unnecessary operations. The main medical principle – *primum non nocere* – was obviously ignored and had serious consequences. The many operations per-




Fig. 9. Frida Kahlo. Diego in my thoughts, 1943. Collection Jacques and Natasha Gelman, Mexico City.

formed on her foot, leg and spine undoubtedly increased her neuropathic pain, becoming extremely severe and devastating in her last years of life. Another kind of neuropathic pain, phantom-limb pain after the leg amputation in 1953, cannot be excluded either. A sketch from the same year in Frida Kahlo's diary (fig. 8) supports this possibility: severed below the right knee, the leg radiates stabbing, shooting pain. Despite various treatments, this kind of pain often is also intractable.

Distressing life events (years of being bedridden or wheelchair bound, her husband's continuous infidelity and devastating miscarriages) undoubtedly lowered her pain threshold and was an important psychogenic pain component.

With the pain worsening in the last years of her life, Frida Kahlo became exhausted, depressed and increasingly dependent on strong painkillers (pethidine and morphine). Under their influence her artistic ability started to deteriorate. She lost interest in life and began to con-

template suicide. 'They amputated my leg six months ago, they have given me centuries of torture and at moments I almost lost my reason. I keep on waiting to kill myself ... Never in my life have I suffered more.' The last entry in her diary reads: 'I hope the exit is joyful ... and I hope never to come back ... Frida.' [quoted from 4]. On 13 July 1954 she unexpectedly died from pneumonia. Pulmonary embolism was diagnosed as the official cause of death.

Passion

Passion of course cannot be directly attributed to neurology, let alone to a neurological disorder. Kahlo's passion, however, could sometimes reach excessive levels, as can be glimpsed from her immense faith in Communism, especially during her last years.

The remarkable self-portrait with Diego Rivera's face on her forehead named 'Diego in my thoughts' (fig. 9) illustrates her other life-long passion: obsessive love for Diego Rivera who, like a spider in its web, had trapped his prey and immensely influenced her life. This excerpt from Frida Kahlo's diary summarizes her thoughts on Diego Rivera: 'Diego: the beginning, builder, my child, my boyfriend, painter, my lover, my husband, my friend, my mother, me, the universe' [quoted from 1].

Conclusion

Frida Kahlo is an impressive example of an artist whose entire life and creativity was profoundly influenced by chronic, severe illness; an artist whose talent arose from psychical and physical suffering yet never was overcome by it. Her work is the best illustration of her life, thoughts and diseases. We just need to look at them, decipher – and admire.

References

- 1 White A (ed): Frida Kahlo, Diego Rivera and Mexican Modernism. The Jacques and Natasha Gelman Collection. Canberra, National Gallery of Australia, 2001.
- 2 Golden JA, Bönnemann CG: Neural tube defects; in Goetz CG, Pappert EJ (eds): Textbook of Clinical Neurology. Philadelphia, Saunders, 1999, pp 514–518.
- 3 Sandblom P: Creativity and Disease, ed 12. New York, Boyars, 1999.
- 4 Kettenmann A: Frida Kahlo. Köln, Taschen, 2003.
- 5 Evans RW, Wilberger JE: Reflex sympathetic dystrophy and causalgia; in Goetz CG, Pappert EJ (eds): Textbook of Clinical Neurology. Philadelphia, Saunders, 1999, pp 1053–1054.
- 6 Schwartzman RJ: Reflex sympathetic dystrophy and causalgia; in Evans RW (ed): Neurology and Trauma. Philadelphia, Saunders, 1996, pp 496–510.