

Management of Pancreatic Cystic Lesions

Giampaolo Perri^a Giovanni Marchegiani^a Isabella Frigerio^b
Christos G. Dervenis^c Kevin C. Conlon^d Claudio Bassi^a Roberto Salvia^a

^aDepartment of General and Pancreatic Surgery, The Pancreas Institute, University of Verona Hospital Trust, Verona, Italy; ^bDepartment of Hepato-Pancreato-Biliary Surgery, Pederzoli Hospital, Peschiera del Garda, Italy; ^cUniversity of Cyprus and Department of Surgical Oncology and HPB Surgery Metropolitan Hospital, Athens, Greece; ^dDepartment of Surgery, Trinity College Dublin, Tallaght Hospital, Dublin, Ireland

Keywords

Pancreatic cystic lesions · Surgical management ·
Intraductal papillary mucinous neoplasm · Pancreatic cyst ·
Pancreatic cystic neoplasms ·

Abstract

Background: The prevalence of undefined pancreatic cystic neoplasms (PCNs) is high in the general population, increasing with patient age. PCNs account for different biological entities with different potential for malignant transformation. The clinician must balance his or her practice between the risk of surgical overtreatment and the error of keeping a malignant lesion under surveillance. **Methods:** We review and discuss the clinical management of PCNs. Specifically, we analyze the main features of PCNs from the surgeon's point of view, as they present in the outpatient clinic. We also review the different consensus guidelines, address recent controversies in the literature, and present the current clinical practice at 4 different European Centers for pancreatic surgery. **Results:** The main features of PCNs were analyzed from the surgeon's point of view as they present in the outpatient clinic. All aspects of surgical management were discussed, from indications for surgery to intraoperative management and surveillance strategies. **Conclusions:** Manage-

ment of PCNs requires a selective approach with the aim of minimizing clinically relevant diagnostic mistakes. Through the evaluation of clinical and radiological features of a PCN, the surgeon can elaborate on a diagnostic hypothesis and assess malignancy risk, but the final decision should be tailored to the individual patient's need. © 2019 S. Karger AG, Basel

Introduction

Large studies have estimated that the overall prevalence of undefined pancreatic cystic neoplasms (PCNs) in the general population ranges from 2.6 to 15%, increasing with age to 37% in patients >80 years old [1, 2].

Due to the extensive use of high-quality cross-sectional imaging in clinical practice, PCNs are also frequently discovered in otherwise asymptomatic patients. Consequently, high-volume centers for pancreatic surgery evaluate an increasing number of patients for PCNs every year, while the median size of the main cystic lesion at

Contribution from the EDS Visceral Medicine Course 2018, Moscow, Russia, February 27 until March 1, 2018. This Postgraduate Course was supported in part by United European Gastroenterology.

Table 1. WHO 2010 classification [4]

Histological classification of pancreatic cystic tumors	
Benign	
Acinar cell cystadenoma	
Serous cystadenoma	
Premalignant lesions	
Intraductal papillary mucinous neoplasms with low- or intermediate-grade dysplasia	
Intraductal papillary mucinous neoplasms with high-grade dysplasia	
Intraductal tubulopapillary neoplasms	
Mucinous cystic neoplasms with low- or intermediate-grade dysplasia	
Mucinous cystic neoplasms with high-grade dysplasia	
Malignant	
Acinar cell cystadenocarcinoma	
Intraductal papillary mucinous neoplasms with an associated invasive carcinoma	
Mucinous cystic neoplasms with an associated invasive carcinoma	
Serous cystadenocarcinoma	
Solid-pseudopapillary neoplasms	

Table 2. Typical epidemiological features and malignancy rates of PCNs

PCN	Age (decade)	Gender, female, %	Location (body/tail), %	Malignancy rate (from surgical series), %
MCN	4th–5th	>95	95	10–15
SCN	6th	70	50	0.1
SPT	3th	80	60	10–16
BD-IPMN	6th–7th	55	30	3–25
Mix-IPMN	6th–7th	55	–	33–60
MD-IPMN	6th–7th	55	–	33–60

MCN, mucinous cystic neoplasm; SCN, serous cystic neoplasm; BD-IPMN, branch duct intraductal papillary mucinous neoplasm; MD-IPMN, main duct intraductal papillary mucinous neoplasm; SPT, solid pseudopapillary tumor; Mix-IPMN, mixed type intraductal papillary mucinous neoplasm; PCNs, pancreatic cystic neoplasms.

diagnosis continues to decrease (with an average cyst diameter at diagnosis of approximately 20 mm) [3].

PCNs account for different biological entities, as listed in the 2010 WHO classification [4] and summarized in Table 1. Looking at such a classification and discriminating those cases for which resection should be advocated seems to be an easy task. The main controversy regarding the treatment of PCNs is the inability to precisely determine the histopathologic diagnosis without surgical resection. Fortunately, the vast majority of patients who are referred to the surgeon for a pancreatic cyst will never need a precise histopathologic diagnosis. Many PCNs harbor the potential for malignancy as precancerous lesions. This potential was shown to be very variable (Table 2), ranging from high (the risk of invasive carcinoma associated with main duct intraductal papillary mucinous neoplasms (IPMNs)

is approximately 44% in surgical series [5]) to, in some cases, extremely low (like in small, indolent branch duct-IPMNs [BD-IPMNs]) or even almost absent (like in serous cystadenoma). Because of this heterogeneity, it is very challenging for clinicians to balance their practice between the risk of surgical overtreatment and the tragic error of keeping a malignant lesion under surveillance (Fig. 1).

Even if data on this specific topic are limited, the current accuracy of cross-sectional imaging modalities in PCN ranges from 47 to 78% [6–8]. Although a “perfect test” to preoperatively define the true nature of a cyst is currently lacking, diagnostic improvement due to current endoscopic techniques, a better understanding of the biology of the various histopathological entities from observational studies and the introduction of several guidelines [5, 9–14] attempting risk stratification have led to a

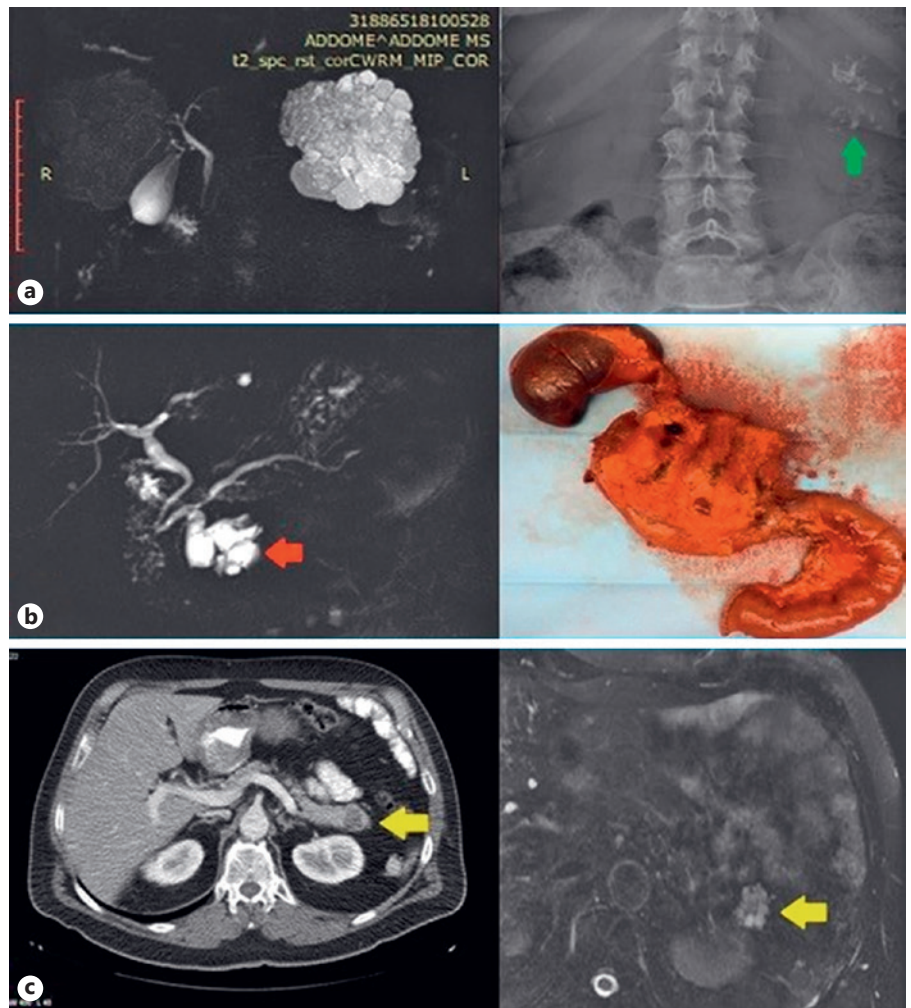


Fig. 1. “The good, the bad, and the ugly”. **a** The good: asymptomatic, big serous cystadenoma of the pancreatic tail (micro-macrocytic type, with typical big central scar and calcifications) incidentally found in a middle-aged woman. Incidental diagnosis was due to calcification resulting from abdominal X-Ray (green arrow). **b** The bad: a 4-cm cystic lesion of the pancreatic head, with a solid enhancing component and initial retro-dilation of common bile duct and MPD (red arrow). Final pathology after PD revealed and invasive ductal adenocarcinoma arising in BD-IPMN (the IPMN showed an intestinal phenotype with high grade dysplasia adjacent to the invasive component). **c** The ugly: a 2.5-cm cystic lesion in the pancreatic tail (yellow arrow) with multiple small enhancing septations was associated to an enhancing solid component reported at EUS (a “high risk stigmata” [11]). Final pathology after surgery revealed a “harmful”, microcystic serous cystadenoma.

more selective approach, with the aim of minimizing clinically relevant diagnostic errors.

The purpose of the present article is to critically review, from the surgeon’s point of view, the main features of PCNs as they present in the outpatient clinic to guide clinical decision making and management. Recent controversies in the literature are addressed in the discussion.

Epidemiology of PCNs

In the era of cross-sectional imaging and endoscopic ultrasound (EUS), some crucial epidemiological aspects of PCNs should not be underestimated while searching for a presumptive diagnosis and must always be kept in mind when evaluating a patient for PCN for the first time. In general, IPMN prevalence increases with age. Some PCNs are more likely to develop in females or males and

at a specific age and location of presentation. The main epidemiological features of PCNs are listed in Table 2, together with their likelihood of malignant progression.

Diagnostic Tools for PCNs

Radiology

MRI/magnetic resonance cholangiopancreatography (MRCP), which differentiates approximately 40–95% of PCN (compared with 40–81% for CT) [15, 16], is the gold standard when PCN is suspected because it is more sensitive than CT for identifying communication with the pancreatic duct system, the presence of a solid component or a mural nodule (MN) and for identifying multifocal PCNs [17, 18].

However, the accuracy of radiological imaging for identifying the specific type of PCN using single imaging

modalities remains relatively low, and frequently, a combined approach is needed.

Endoscopy

Currently, EUS is an essential diagnostic tool in the management of PCNs. EUS is recommended as a second-line examination in addition to CT/MRI in all cases when a radiological diagnosis of malignancy is not conclusive and/or whenever a PCN has clinical or radiological features of concern. In particular, contrast-enhanced EUS (CE-EUS) should always be considered in the presence of MNs or solid components to assess the presence of vascularization [11, 14, 19].

Cytology and Biomarkers

EUS-guided fine-needle aspiration should be considered when malignant transformation is suspected, in particular where the radiological findings are unclear. Cytology is highly specific (83–100%), although it has relatively low sensitivity (27–48%), resulting in low diagnostic accuracy (8–59%). Therefore, it should always be combined with EUS morphology [20–22].

Chemical analyses of fluid CEA and amylase levels can be useful but will not distinguish Mucinous Cystic Neoplasms (MCNs) and IPMNs. Elevated CEA is a marker that distinguishes mucinous from non-mucinous cysts but not malignant from benign cysts. A cutoff of ≥ 192 –200 ng/mL is $\sim 80\%$ accurate for the diagnosis of a mucinous cyst (with high specificity but low sensitivity) [22].

Molecular analysis of the cyst fluid for diagnosis is still evolving. KRAS mutations more accurately support the diagnosis of a mucinous but not necessarily malignant cyst. GNAS mutations may be helpful in distinguishing significant mucinous cysts from indolent cysts that can be conservatively managed [11].

Serum CA19.9 is an independent predictor of malignancy in IPMNs, and a CA19.9 value higher than 37 U/L is associated with an increased risk of invasive carcinoma [23–25]. In the literature, the low specificity of CA19.9 is probably also because, unfortunately, most studies have included HGD and invasive cancer in one single “malignant” category [11].

Clinical Features of PCNs

Symptoms

The reported rates of symptomatic PCNs in the literature range from 44 to 80% [26, 27]. This evidence seems to be in contrast with everyday clinical experience, as the

vast majority of PCNs presenting to outpatient clinics are incidentally diagnosed in asymptomatic individuals. Of note, data regarding symptomatic PCNs are mainly derived from surgical series and may be affected by selection bias. In observational studies, the prevalence of symptoms in PCN patients decreases to 17–21% [28–30].

Except for obstructive jaundice and acute pancreatitis, it is indeed extremely difficult to accurately correlate those symptoms to the presence of a PCN. Non pancreas-specific symptoms, such as abdominal pain, appear to be extremely frequent though difficult to evaluate.

For these reasons, in current guidelines that address symptoms, the sole “absolute” criterion for surgery is a lesion-related obstructive jaundice [5, 9–14], a condition that is highly suggestive of malignancy but could also be observed in benign lesions (i.e., a large serous cystadenoma located in the pancreatic head). PCN-related pancreatitis is also considered an indicator of malignancy [31–33] and therefore a “worrisome feature” and a “relative indication” for surgery (especially in IPMNs [5, 9–14] and for recurrent episodes).

Radiological Features of PCNs (Namely, “The Shape of Water”)

Size

Size is the most obvious feature of a PCN, a crucial parameter that in the recent past has always driven surgical management. Despite its importance, a cutoff for definitively recommending surgery based on dimensions does not exist in the literature. In the absence of strong evidence supporting a correlation between dimensions and malignancy of PCNs, current IAP and AGA guidelines address a size parameter of ≥ 30 mm as a “worrisome feature” and therefore an indication for EUS-fine-needle aspiration [11, 12], while European guidelines [14] set a dimensional cutoff of ≥ 40 mm as a “relative indication” for surgery for both IPMNs and MCNs. In selected cases, the morphology of PCNs can guide a presumptive diagnosis that de-emphasizes the role of size in decision making. This is the case for SCNs, in which dimensions are never related to malignancy potential, and for solid pseudopapillary tumors (SPTs), in which resection is always advocated regardless of dimensional parameters.

In several surgical series of resected IPMNs, the presence of a cyst size ≥ 30 mm had a positive predictive value for malignancy of between 27 and 33% [34–37]. On the other hand, a large cohort of individuals under surveil-

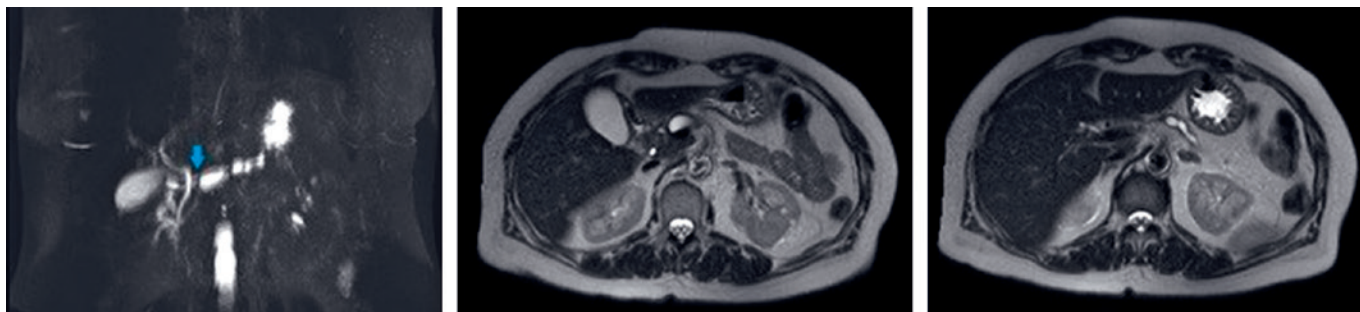


Fig. 2. A presumed MD-IPMN of the pancreatic body-tail underwent extended DP. Final pathology revealed an obstructive retro-dilation of MPD (blue arrow) due to a small, G1 pNET of the pancreatic body (not visible at pre-op imaging).

lance has validated the safety of observation of BD-IPMN measuring <40 mm in the absence of other risk factors [38]. The risk of malignancy should be stratified by the presence of other suspect features. In the absence of other risk factors, malignancy risk is still present but very low [37, 39], indicating that cyst size alone is not an appropriate indication for surgery, while if multiple risk factors are present, the sensitivity of size to detect malignancy increases [36, 40].

PCN growth rate during follow-up is a more accurate parameter for predicting the risk of progression, rather than cyst size at first observation. A rapid growth rate (>2 mm/year) is reported to have a 5-year risk for developing malignancy of 45%, even for BD-IPMN <30 mm [41]. In the presence of a growth rate of >5 mm/year or a total growth of 10 mm in 36 months, malignant progression has been found to be 20-fold higher for IPMNs [42].

Unpublished data from a 30-year experience of dedicated outpatient cyst clinic at the single high-volume center of Verona Pancreas Institute suggest that IPMNs with a rapid growth rate (>2.75 mm/year) will likely progress to pancreatic cancer through the development of WF and HRS during the first year of follow-up.

MNs or Solid Component

MNs are one of the strongest predictors of malignancy and should be considered an absolute indication for surgery in all suitable patients when the diagnosis is certain. In particular, MN is indeed the strongest predictor of either HGD or invasive cancer for all types of suspected IPMNs, with the sole exception of HGD in BD-IPMNs [43].

According to new guidelines [11, 14], the presence of an enhancing MN ≥ 5 mm represents a clear indica-

tion for surgery. Although no evidence for a possible dimensional cutoff related to an increased risk of invasive cancer or HGD is available, the risk of malignancy appears to be directly proportional to the size of the MN [43].

As MNs should be considered morphologic and solid expressions of tumor proliferation, their dimensions appear extremely useful for predicting the presence of invasive cancer or HGD because the same correlation between size and the risk of malignancy does not apply to the cyst size of an IPMN. In fact, although the dimensions of the cyst should be considered a surrogate parameter of neoplastic growth, the dimensions of the growing solid component represent the actual burden of the neoplastic process.

Whenever the presence of MN is unclear at the arterial phase of an MRI, CE-EUS should be considered the second procedure of choice [11, 14, 42] for differentiating MNs from mucin clots.

Dilation of Main Pancreatic Duct

Main pancreatic duct (MPD) dilation in IPMNs is often an indirect sign of the disease, resulting in mucous, which is produced by the underlying neoplastic process and that which is located in the duct walls. Such dilation therefore represents a diagnostic dilemma for the clinicians once it becomes visible via tomographic imaging. MPD dilations represent indeed a broad spectrum of conditions, from IPMNs to other benign (ductal hypertension caused by mucin hypersecretion/mucin plugs and obstructive chronic pancreatitis) as well as malignant entities (solid tumors with retrograde MPD dilation; Fig. 2).

Surgery is warranted in all cases of IPMNs involving the MPD according to all current guidelines, but there is

still no consensus regarding clinical management once an MPD dilation is diagnosed. In the absence of other features suspect for malignancy, MPD dilation alone is characterized by a considerable risk of misdiagnosis and possible overtreatment.

Some authors have suggested radiologic surveillance in asymptomatic patients who have “worrisome” MPD dilation (5–9 mm) and who lack other high-risk stigmata [44]. Conversely, after observing a “risk” of malignancy of 59% among resected IPMNs with an MPD involvement between 5 and 9 mm and the lack of statistical correlations between MPD diameter and clinical and/or IPMN features, other authors have suggested lowering the threshold for surgery to all MPD dilations greater than 5 mm [45].

As stated before, the clear majority of studies defining the malignancy risk for IPMNs are derived from surgical series, which by definition fail to evaluate the actual incidence of malignancy in the overall population of individuals with MPD dilation. A multicenter study has analyzed the midterm outcomes and predictors of survival in non-operated patients with presumed IPMNs. The authors found that patients with IPMNs with “worrisome features” (such as MPD dilation between 5 and 9 mm) had a 5-year disease-specific survival of 96%, suggesting that conservative management is appropriate in these cases. On the other hand, the presence of “high-risk stigmata” (such as MPD dilation ≥ 10 mm) was associated with a 40% risk of IPMN-related death, reinforcing the policy of surgical resection in fit patients [28].

Other Radiological Features

The above-mentioned clinical and radiological features are the most relevant in predicting the risk of malignancy among PCNs. However, many other radiological findings can lead to a presumptive diagnosis.

SCNs have a lobulated shape, usually with a fine honeycomb pattern on CT, which is indicative of their microcystic morphology and, in some cases, a pathognomonic, central calcified scar. However, their macrocystic and oligo- or monocystic variants can appear similar to mucinous tumors on both CT and EUS.

SPTs exhibit solid growth with cystic degeneration, often resulting in the findings of both solid and cystic areas upon imaging.

MCN appear as uni- or multilocular round lesions, without communication with the pancreatic duct. The cystic wall and the septa are usually thick. Occasionally, peripheral “eggshell” calcification may be seen, being almost pathognomonic.

Surgical Management

In earlier sections, we described the main clinical features of PCNs, which usually lead the surgeon to a presumptive diagnosis and, above all, an estimation of a PCNs biological behavior and likelihood of malignancy. Through the different features observed, the surgeon can interpret what we used to call the “shape of water” of a cystic neoplasm, elaborating a diagnostic hypothesis and possibly discriminating lesions with no malignant potential, such as SCNs.

Clinical and radiological suspicion, however, is not the only parameter leading surgical decision making, as the patient is a crucial variable to consider. Patient fitness for surgery represents a continuous variable based on age and life expectancy, patient frailty, overall health status and comorbidities, and patient will and motivation for surgery. Considering the low overall rate of malignancy of PCNs, this parameter is of paramount importance. Each case should always be carefully evaluated with input from the patient after adequate counseling. Surgery type also plays a role in the final decision, as pancreaticoduodenectomy and distal pancreatectomy bear a substantially different burden in terms of morbidity, mortality, and sequelae.

The criteria for surgical indication in mucinous PCNs (IPMNs and MCNs) at Author’s Institutions (Fig. 3) are in line with the IAP 2017 and European 2018 guidelines [11, 14]. Guidelines are useful tools for identifying patients at relatively high risk for harboring cancer, but they must be applied with flexibility and with the awareness that, at the present time, they are mostly based on “expert opinion” and not supported by strong scientific evidence. The final surgical decision must be tailored to the individual patient, considering all the above-mentioned variables.

“High-risk stigmata” or “absolute,” standalone indications for surgery in all fit patients include PCN-related jaundice, the presence of a vascularized MN or solid component, and a cytology suggesting malignancy. Surgery is also recommended for all fit patients presenting with an MPD dilation > 1 cm, only if there is a high suspicion of main duct or mixed IPMN (no signs of MPD obstruction or chronic pancreatitis). These clinical features are sufficient to advocate surgery at diagnosis.

Other features, such as MPD between 5 and 9 mm or a progressively increasing MPD dilation, recurrent acute pancreatitis, a cyst size ≥ 30 mm or a rapid growth rate (> 2.75 mm/year), thick vascularized cyst walls and

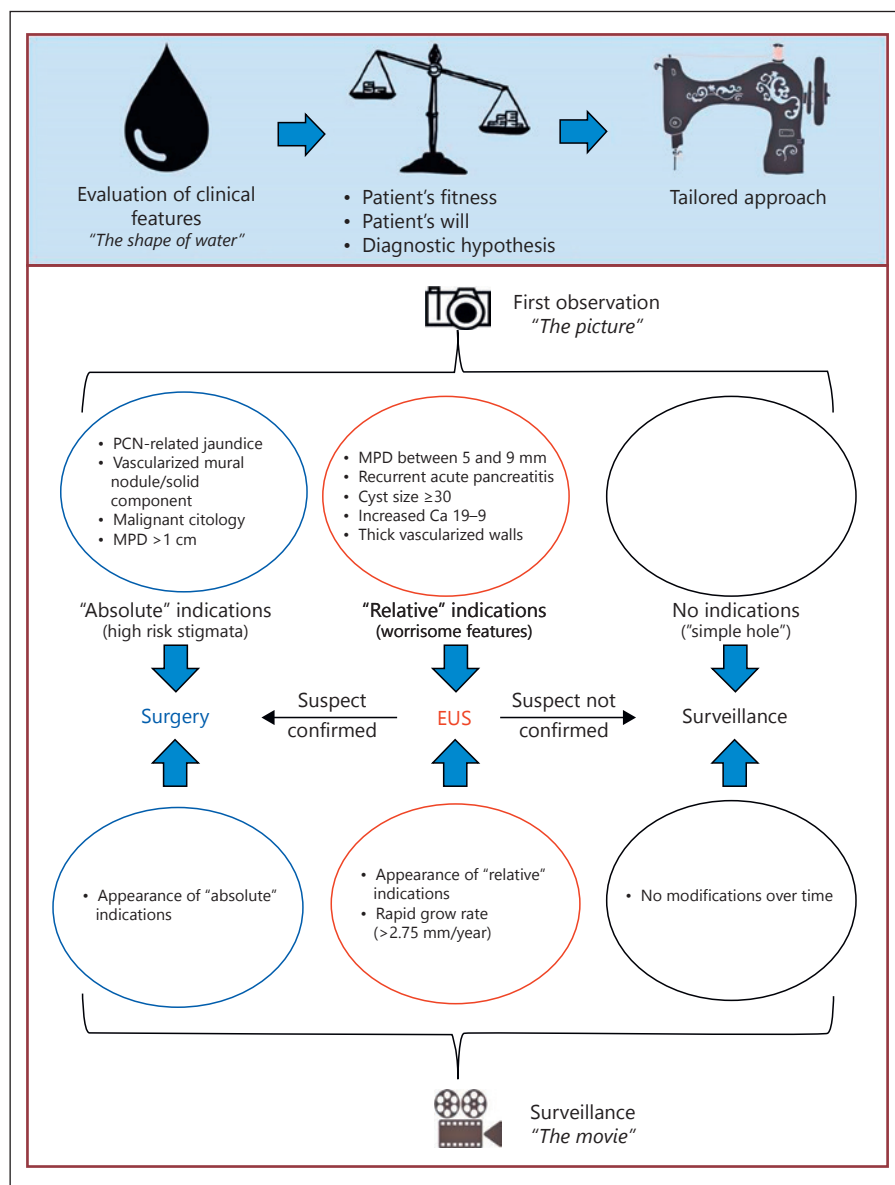


Fig. 3. The Verona policy regarding mucinous PCNs (IPMNs and MCNs). EUS, endoscopic ultrasound.

increased serum levels of CA19-9, are all features of concern but are not strong standalone predictors of malignancy; therefore, they are not indications for surgery if encountered alone and after a single observation.

Patients with suspected features but without absolute indications for surgery should undergo CE-EUS; if the malignancy suspicion is not confirmed endoscopically, patients should undergo close surveillance with MRI/MRCP, oncological markers and CE-EUS when indicated.

The single pictures of each observation aggregated into a movie provide a longitudinal appraisal of the natural history of the disease, and the worsening of a single

parameter or the appearance of a second suspect feature are sound criteria for reconsidering a surgical approach.

When patients with an SCN can be identified, recommendations regarding resection and long-term surveillance can focus on issues surrounding symptoms of local growth and progression rather than the development of cancer.

In cases of suspected IPMNs, MCNs, and SPTs, surgical resection should always achieve the complete removal of the tumor with appropriate lymphadenectomy and negative resection margins evaluated from an intraoperative frozen section. Parenchyma sparing pancreatotomy

does not represent a safe procedure for all these PCNs because the disease is frequently presumed to be malignant; therefore, the procedure should be reserved for selected cases or for SCNs.

Even in young patients, an acceptable risk of recurrence and related death seems preferable to the morbidity and mortality of a total pancreatectomy if “free margins” are achieved from the frozen section.

As stated before, guidelines [11, 14] are useful for identifying patients at high risk due to their sensitivity. However, these guidelines have a low level of specificity because they are mostly based on retrospective series of resected PCNs. This selection bias may overestimate the overall risk of malignant progression, limiting the knowledge regarding a large proportion of PCNs under surveillance. IPMNs represent the largest proportion, as they account for at least 80% of PCNs [46] and may progress to pancreatic cancer.

Recently, several large observational series [28, 38, 47–50] that included large numbers of patients under long-term surveillance allowed us to better define a population that could be safely kept under surveillance due to a low

overall risk of pancreatic cancer and to reduce the significance of some risk factors.

However, even if the benefit of prolonged follow-up has not yet been demonstrated in reducing cancer-related mortality, all these studies showed that cyst stability at 5 years does not preclude the risk of future progression to pancreatic cancer, thereby resulting in a lifelong risk of malignancy. Therefore, follow-up should never be discontinued because repeated observations are crucial for risk stratification. At present, several follow-up schedules have been proposed in guidelines [11, 14], but none of them have been shown to be the most cost effective. In the absence of suspected features mentioned above, authors usually recommend follow-up with MRI/MRCP and oncological markers every 6 months for the 1st year. In the absence of progression, follow-up with MRI/MRCP and serum markers at 12 or 18 months is maintained.

Disclosure Statement

The authors declare that they have no conflicts of interest to disclose.

References

- 1 Farrell JJ: Prevalence, diagnosis and management of pancreatic cystic neoplasms: current status and future directions. *Gut Liver* 2015;9: 571–589.
- 2 Lee KS, Sekhar A, Rofsky NM, et al: Prevalence of incidental pancreatic cysts in the adult population on MR imaging. *Am J Gastroenterol* 2010;105:2079–2084.
- 3 Gaujoux S, Brennan MF, Gonen M, et al: Cystic lesions of the pancreas: changes in the presentation and management of 1,424 patients at a single institution over a 15-year time period. *J Am Coll Surg* 2011;212:590–600.
- 4 Hruban RH, Kloepfel G, Bofetta P, et al: Tumours of the pancreas; in Bosman FT, Carneiro F, Hruban RH (eds): *WHO Classification of Tumours of the Digestive System* (ed 4). Lyon, International Agency for Research on Cancer, 2010, pp 280–330.
- 5 Tanaka M, Fernandez-del Castillo C, Adsay V, et al: International consensus guidelines 2012 for the management of IPMN and MCN of the pancreas. *Pancreatol* 2012;12:183–197
- 6 Del Chiaro M, Segersvård R, Pozzi Mucelli R, et al: Comparison of preoperative conference-based diagnosis with histology of cystic tumors of the pancreas. *Ann Surg Oncol* 2014; 21:1539–1544.
- 7 Salvia R, Malleo G, Marchegiani G, et al: Pancreatic resections for cystic neoplasms: from the surgeon's presumption to the pathologist's reality. *Surgery* 2012;152(3 suppl 1):S135–S142.
- 8 Cho CS, Russ AJ, Loeffler AG, et al: Preoperative classification of pancreatic cystic neoplasms: the clinical significance of diagnostic inaccuracy. *Ann Surg Oncol* 2013;20:3112–3119.
- 9 Tanaka M, Chari S, Adsay V, et al: International consensus guidelines for management of intraductal papillary mucinous neoplasms and mucinous cystic neoplasms of the pancreas. *Pancreatol* 2006;6:17–32.
- 10 Tanaka M, Fernandez-del Castillo C, Adsay V, et al: International consensus guidelines 2012 for the management of IPMN and MCN of the pancreas. *Pancreatol* 2012;12:183–197
- 11 Tanaka M, Fernández-Del Castillo C, Kamisawa T, et al: Revisions of international consensus Fukuoka guidelines for the management of IPMN of the pancreas. *Pancreatol* 2017;17:738–753.
- 12 Vege SS, Ziring B, Jain R, et al; Clinical Guidelines Committee; American Gastroenterology Association: American gastroenterological association institute guideline on the diagnosis and management of asymptomatic neoplastic pancreatic cysts. *Gastroenterology* 2015;148:819–22; quiz 12–23.
- 13 Del Chiaro M, Verbeke C, Salvia R, et al; European Study Group on Cystic Tumours of the Pancreas: European experts consensus statement on cystic tumours of the pancreas. *Dig Liver Dis* 2013;45:703–711.
- 14 European Study Group on Cystic Tumours of the Pancreas: European evidence-based guidelines on pancreatic cystic neoplasms. *Gut* 2018;67:789–804.
- 15 Jang DK, Song BJ, Ryu JK, et al: Preoperative diagnosis of pancreatic cystic lesions: the accuracy of endoscopic ultrasound and cross-sectional imaging. *Pancreas* 2015;44:1329–1333.
- 16 Lee HJ, Kim MJ, Choi JY, et al: Relative accuracy of CT and MRI in the differentiation of benign from malignant pancreatic cystic lesions. *Clin Radiol* 2011;66:315–321.
- 17 Sahani DV, Kambadakone A, Macari M, et al: Diagnosis and management of cystic pancreatic lesions. *AJR Am J Roentgenol* 2013;200: 343–354.
- 18 Waters JA, Schmidt CM, Pinchot JW, et al: CT vs MRCP: optimal classification of IPMN type and extent. *J Gastrointest Surg* 2008;12: 101–109
- 19 Harima H: Differential diagnosis of benign and malignant branch duct intraductal papillary mucinous neoplasm using contrast-enhanced endoscopic ultrasonography. *World J Gastroenterol* 2015;21:6252–6260.
- 20 Cizginer S, Turner BG, Bilge AR, et al: Cyst fluid carcinoembryonic antigen is an accurate diagnostic marker of pancreatic mucinous cysts. *Pancreas* 2011;40:1024–1028.

- 21 Sedlack R, Affi A, Vazquez-Sequeiros E, et al: Utility of EUS in the evaluation of cystic pancreatic lesions. *Gastrointest Endosc* 2002;56:543–547.
- 22 Brugge WR, Lewandrowski K, Lee-Lewandrowski E, Centeno BA, Szydio T, Regan S, et al: Diagnosis of pancreatic cystic neoplasms: a report of the cooperative pancreatic cyst study. *Gastroenterology* 2004;126:1330–1336.
- 23 Jang JY, Park T, Lee S, et al: Proposed nomogram predicting the individual risk of malignancy in the patients with branch duct type intraductal papillary mucinous neoplasms of the pancreas. *Ann Surg* 2017;266:1062–1068.
- 24 Wang W, Zhang L, Chen L, et al: Serum carcinoembryonic antigen and carbohydrate antigen 19-9 for prediction of malignancy and invasiveness in intraductal papillary mucinous neoplasms of the pancreas: a meta-analysis. *Biomed Rep* 2015;3:43–50.
- 25 Kim JR, Jang JY, Kang MJ, et al: Clinical implication of serum carcinoembryonic antigen and carbohydrate antigen 19–9 for the prediction of malignancy in intraductal papillary mucinous neoplasm of pancreas. *J Hepatobiliary Pancreat Sci* 2015;22:699–707.
- 26 Masica DL, Dal Molin M, Wolfgang CL: A novel approach for selecting combination clinical markers of pathology applied to a large retrospective cohort of surgically resected pancreatic cysts. *J Am Med Inform Assoc* 2017;24:145–152.
- 27 Jang JY, Park T, Lee S: Proposed nomogram predicting the individual risk of malignancy in the patients with branch duct type intraductal papillary mucinous neoplasms of the pancreas. *Ann Surg* 2017;266:1062–1068.
- 28 Crippa S, Bassi C, Salvia, et al: Low progression of intraductal papillary mucinous neoplasms with worrisome features and high-risk stigmata undergoing non-operative management: a mid-term follow-up analysis. *Gut* 2017;66:495–506.
- 29 Mukewar S, De Pretis N, Aryal-khanal A, et al: Fukuoka criteria accurately predict risk for adverse outcomes during follow-up of pancreatic cysts presumed to be intraductal papillary mucinous neoplasms. *Gut* 2017;66:1811–1817.
- 30 Han Y, Lee H, Kang JS, et al: Progression of pancreatic branch duct intraductal papillary mucinous neoplasm associates with cyst size. *Gastroenterology* 2018;154:576–584.
- 31 Roch AM, Parikh JA, Al-Haddad MA, et al: Abnormal serum pancreatic enzymes, but not pancreatitis, are associated with an increased risk of malignancy in patients with intraductal papillary mucinous neoplasms. *Surgery* 2014;156:923–930.
- 32 Rivera JA, Fernández-del Castillo C, Pins M, et al: Pancreatic mucinous ductal ectasia and intraductal papillary neoplasms. A single malignant clinicopathologic entity. *Ann Surg* 1997;225:637–646.
- 33 Shin SH, Han DJ, Park KT, et al: Validating a simple scoring system to predict malignancy and invasiveness of intraductal papillary mucinous neoplasms of the pancreas. *World J Surg* 2010;34:776–783.
- 34 Sahara K, Mino-Kenudson M, Brugge W, et al: Branch duct intraductal papillary mucinous neoplasms: does cyst size change the tip of the scale? A critical analysis of the revised international consensus guidelines in a large single-institutional series. *Ann Surg* 2013;258:466–475.
- 35 Nguyen AH, Toste PA, Farrell JJ, et al: Current recommendations for surveillance and surgery of intraductal papillary mucinous neoplasms may overlook some patients with cancer. *J Gastrointest Surg* 2015;19:258–265.
- 36 Roch AM, Ceppa EP, DeWitt JM, et al: International consensus guidelines parameters for the prediction of malignancy in intraductal papillary mucinous neoplasm are not properly weighted and are not cumulative. *HPB (Oxford)* 2014;16:929–935.
- 37 Robles EP, Maire F, Cros J, et al: Accuracy of 2012 international consensus guidelines for the prediction of malignancy of branch-duct intraductal papillary mucinous neoplasms of the pancreas. *United European Gastroenterol J* 2016;4:580–586.
- 38 Del Chiaro M, Ateeb Z, Hansson MR, et al: Survival analysis and risk for progression of intraductal papillary mucinous neoplasia of the pancreas (IPMN) under surveillance: a single-institution experience. *Ann Surg Oncol* 2017;24:1120–1126.
- 39 Jang JY, Park T, Lee S, et al: Validation of international consensus guidelines for the resection of branch duct-type intraductal papillary mucinous neoplasms. *Br J Surg* 2014;101:686–692.
- 40 Ohtsuka T, Kono H, Nagayoshi Y, et al: An increase in the number of predictive factors augments the likelihood of malignancy in branch duct intraductal papillary mucinous neoplasm of the pancreas. *Surgery* 2012;151:76–83.
- 41 Kang MJ, Jang JY, Kim SJ, et al: Cyst growth rate predicts malignancy in patients with branch duct intraductal papillary mucinous neoplasms. *Clin Gastroenterol Hepatol* 2011;9:87–93.
- 42 Kwong WT, Lawson RD, Hunt G, et al: Rapid growth rates of suspected pancreatic cyst branch duct intraductal papillary mucinous neoplasms predict malignancy. *Dig Dis Sci* 2015;60:2800–2806.
- 43 Marchegiani G, Andrianello S, Borin A, et al: Systematic review, meta-analysis, and a high-volume center experience supporting the new role of mural nodules proposed by the updated 2017 international guidelines on IPMN of the pancreas. *Surgery* 2018;163:1272–1279.
- 44 Crippa S, Pergolini I, Rubini C, et al: Risk of misdiagnosis and overtreatment in patients with main pancreatic duct dilatation and suspected combined/main-duct intraductal papillary mucinous neoplasms. *Surgery* 2016;159:1041–1049.
- 45 Hackert T, Fritz S, Klaus M, et al: Main-duct intraductal papillary mucinous neoplasm: high cancer risk in duct diameter of 5 to 9 mm. *Ann Surg* 2015;262:875–880.
- 46 Laurent L, Vullierme MP, Rebours V, et al: Estimation of the prevalence of intraductal papillary mucinous neoplasm of the pancreas in the French population through patients waiting for liver transplantation. *United European Gastroenterol J* 2017;5:499–503.
- 47 Pergolini I, Sahara K, Ferrone CR, et al: Long-term risk of pancreatic malignancy in patients with branch duct intraductal papillary mucinous neoplasm in a referral center. *Gastroenterology* 2017;153:1284–1294.e1.
- 48 Han Y, Lee H, Kang JS, et al: Progression of pancreatic branch duct intraductal papillary mucinous neoplasm associates with cyst size. *Gastroenterology* 2018;154:576–584.
- 49 Lawrence SA, Attiye MA, Seier K, et al: Should patients with cystic lesions of the pancreas undergo long-term radiographic surveillance: results of 3024 patients evaluated at a single institution. *Ann Surg* 2017;266:536–544.
- 50 Ohno E, Hirooka Y, Kawashima H, et al: Natural history of pancreatic cystic lesions: a multicenter prospective observational study for evaluating the risk of pancreatic cancer. *J Gastroenterol Hepatol* 2018;33:320–328.