

## Case Studies

# Pagetoid Reticulosis: Report of Two Cases and Review of the Literature

Krista Larson Mark R. Wick

Division of Dermatopathology, University of Virginia School of Medicine,  
Charlottesville, Va., USA

### Key Words

Cutaneous T-cell lymphoma · Pagetoid reticulosis · Woringer-Kolopp disease · Mycosis fungoides · Skin tumors

### Abstract

Pagetoid reticulosis is a rare variant of mycosis fungoides that presents with a large, usually single, erythematous, slowly growing scaly plaque containing an intraepidermal proliferation of neoplastic T lymphocytes. Histopathologically, this disease has distinctive attributes. In this report, we present two cases of pagetoid reticulosis, compare its microscopic features to those of 'classical' mycosis fungoides, and provide a brief review of the pertinent literature.

© 2016 The Author(s)  
Published by S. Karger AG, Basel

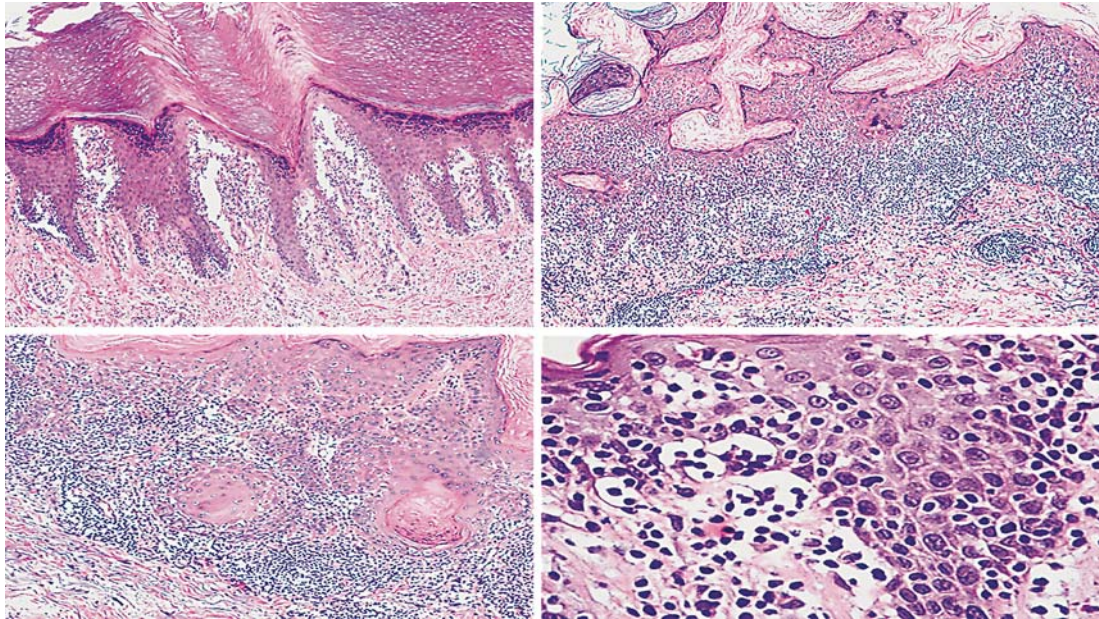
Pagetoid reticulosis (PR; also known as Woringer-Kolopp disease) is a rare, distinctive variant of mycosis fungoides (MF). It usually presents in adults as a single, erythematous, slowly growing scaly or verrucous plaque that is typically found on the extremities [1]. We herein report two cases of PR and compare its histological features to those of classical MF.

### Case 1

A 61-year-old woman presented with a verrucoid pink-tan plaque on the right heel, measuring 3 cm in diameter, which was subjected to an excisional biopsy. It had been present for approximately 1 year. There were no cutaneous lesions elsewhere, and the remaining physical examination also showed no abnormalities. The results of a hemogram and a biochemical blood survey were normal.

Histological analysis showed a well-demarcated, discrete area of hyperkeratosis and parakeratosis with epidermal acanthosis. The surface epithelium was permeated by an infil-

Dr. M.R. Wick  
Room 3020, University of Virginia Hospital  
1215 Lee St.  
Charlottesville, VA 22908-0214 (USA)  
E-Mail [mrw9c@virginia.edu](mailto:mrw9c@virginia.edu)



**Fig. 1.** Composite of images from both PR cases showing a dense intraepidermal infiltrate of atypical lymphoid cells, with epidermal acanthosis. There are only a few lesional cells in the upper dermis.

trate of atypical mononuclear cells with pale eosinophilic cytoplasm, large nuclei, and prominent nucleoli. They were dispersed randomly throughout the epidermis, singly and in small nests, with the greatest density being in its basal aspect. The superficial corium contained similar cellular elements as well as a mixture of other inflammatory cells (fig. 1).

Immunostaining showed that the lesional cells were reactive for CD2, CD3, CD7, CD43, and CD45R0. CD8+ lymphocytes were sparse, and CD7 labeling was less intense than that of the other lymphoid markers (fig. 2). CD30 was absent.

There has been no recurrence of any cutaneous lesions 10 months after excision of the pedal tumor, and the patient is currently well.

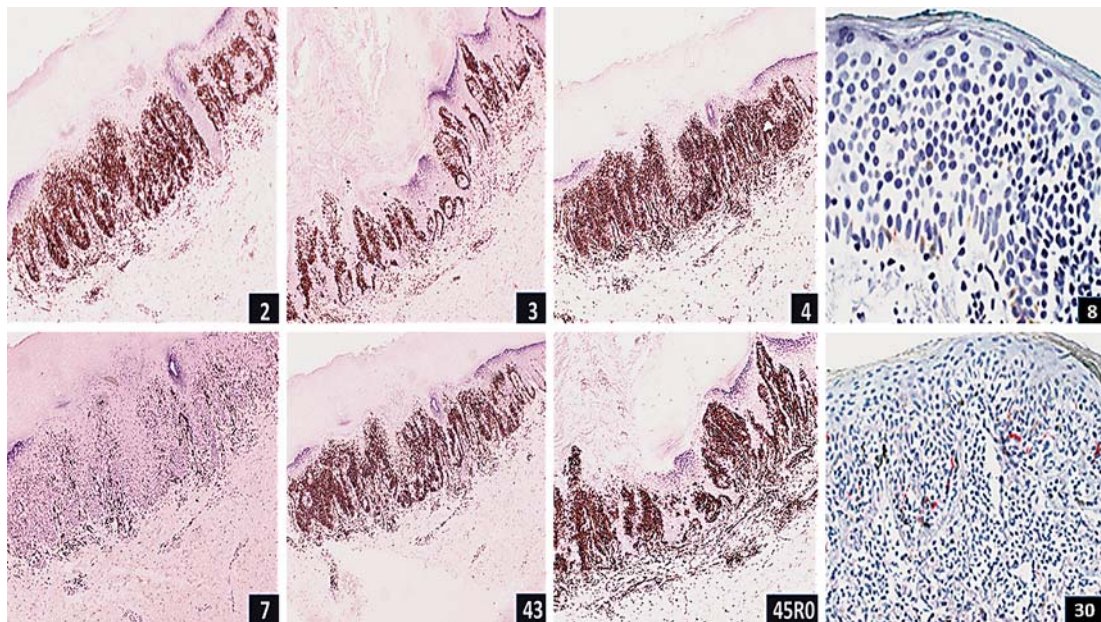
## Case 2

A 50-year-old man developed a 1-cm pearly white-tan lesion on the chest, which had evolved over approximately 3 years. In the previous 3–4 months, it had increased in size and began to burn and itch.

Histological examination of an excisional biopsy specimen showed epidermal acanthosis with marked exocytosis, creating a ‘sieve-like’ appearance. The intraepithelial lymphoid cells were atypical cytologically, and they contained occasional mitotic figures. Those elements manifested significant irregularities in the nuclear membranes, with nuclear hyperchromasia and pleomorphism, and the cytoplasm was amphophilic or vacuolated. A mixed, superficial, perivascular dermal inflammatory infiltrate was also present (fig. 1). Immunohistochemical studies showed diffuse lesional reactivity for CD3, but labeling for CD7 was significantly diminished. Intraepidermal lymphoid cells were nearly all reactive for CD4, with only scattered staining for CD8 (fig. 2).

The patient is currently well, with no additional cutaneous lesions 16 months after the diagnosis.





**Fig. 2.** Immunohistological findings of both PR cases. Diffuse immunoreactivity was present for CD2, CD3, CD4, CD43, and CD45R0, but labeling for CD7 was comparatively diminished. CD8+ lymphocytes were sparse and CD30 was absent.

## Discussion

PR was first described by Frederick Woringer and Pierre Kolopp in 1939, in Strasbourg, France [2]. The first documented case was that of a 13-year-old boy who had a lesion on his forearm that measured <1 cm in diameter and had been present for 6 years; it then enlarged quickly. Original clinical diagnostic considerations included those of MF, melanocytic nevus, and Paget's disease; an intraepidermal lymphoid infiltrate was observed microscopically [3]. In 1973, Braun-Falco and colleagues assigned the designation of 'pagetoid reticulosis' to this condition because of the intraepidermal pagetoid distribution of lymphoid cells, which were thought to possibly represent T cells [3]. Those authors believed that PR was a disease entity distinct from MF because of its localized nature and more marked lymphoid epidermotropism. Revuz and colleagues later concluded that the Woringer-Kolopp disease and PR were one and the same condition [3].

Currently, it is still difficult to distinguish PR from other variants of MF by microscopy alone. Indeed, the differential diagnosis of PR includes MF of the 'palmaris et plantaris' type. Primary epidermotropic CD8+ cytotoxic T-cell lymphoma represents another consideration [4]. PR almost exclusively comprises dense intraepidermal lymphoid infiltrates with variable acanthosis [5]; few atypical cells are seen in the dermis [1], but the corium commonly contains mature lymphocytes and histiocytes. Immunologically, the lesional cells in PR are typically CD4+ T cells, although examples with CD8+ and CD4-/CD8- phenotypes have also been described [5]. The cellular proliferation rate, as measured immunohistologically with the Ki-67/MIB1 antibody, is usually >30%, and CD30 reactivity may be present as well [5].

In comparison, classical MF typically manifests both epidermal and dermal components; the latter comprise a polymorphous cell population consisting of neoplastic and mature lymphocytes, histiocytes, plasma cells, and eosinophils [5]. Clinically, typical MF lesions are

most often thin plaques on the distal extremities and trunk [5]. Immunologically, the tumor cells are CD4+ with a low proliferation index (<10%), and they are usually CD30– [4]. Despite those differences, the World Health Organization has recently classified PR as a unilesional variant of MF [6].

PR is generally believed to be an indolent disease. However, it seems that this is not always the case. In a study by Haghighi et al. [5], some patients with PR had clinically progressive lesions that required aggressive therapy. Another publication suggested that it was sometimes difficult to distinguish PR from MF of the ‘palmaris et plantaris’ type, and that the latter cases could require active treatment [7].

It is important to include other aggressive T-cell lymphomas in the differential diagnosis of PR. For example, in one reported case, a patient with high-grade peripheral T-cell lymphoma was erroneously categorized initially as PR. The tumor subsequently exhibited visceral involvement and proved fatal in <2 years [8]. Another similar example was that of adult T-cell lymphoma/leukemia that was first thought to represent PR; it likewise pursued an aggressive clinical course [9].

Immunohistochemical analysis of the lesions and thorough clinical correlation are necessary to avoid such problems. Recent investigations of T-cell receptor gene rearrangements in PR have shown that either TCR $\gamma\delta$  or TCR $\alpha\beta$  may be aberrant [10]. The proliferative index of the lesional cells is only debatably related to prognosis [11].

Recently documented cases of PR [12–17] have included patients of all ages, including children. Localized perioral lesions have also been reported [18] as well as a generalized form of the disorder known as Ketrion-Goodman disease [19]. On dermoscopy, PR has been said to show features that are similar to those of Bowen’s disease. They include glomerular and dotted vessels, whitish scaly areas, and reticular depigmentation [20].

Several treatments have been employed in PR cases, such as topical steroids, topical nitrogen mustard, light therapy, interferon alpha-2b [21], localized [22] and modulated [23] radiation therapy, imiquimod [24], alitretinoin [25], and fractional laser-assisted photodynamic therapy [26, 27]. In the reported experience of Lee et al. [22], localized radiation therapy seemed to produce the best results. Photodynamic therapy may be an alternative to irradiation in young patients [27].

In summary, we have presented two cases of PR. Their features and a review of the literature support the conclusion that PR is a unilesional variant of MF with distinctive clinicopathologic features.

### Statement of Ethics

The approval of the authors’ institutional review board was obtained for this study as well as the patients’ consent.

### Disclosure Statement

The authors have no fiduciary interests or conflicts of interest to disclose.

## References

- 1 Weedon D: Skin Pathology, ed 2, Elsevier, New York, 2009, pp 739–740.
- 2 Cribier B: Frederic Woringer (1903–1964) and Woringer-Kolopp disease. *Am J Dermatopathol* 2005;27:534–545.
- 3 Steffen C: Ketron-Goodman disease, Woringer-Kolopp disease, and pagetoid reticulosis. *Am J Dermatopathol* 2005;27:68–85.
- 4 Cho-Vega JH, Tschen JA, Duvic M, Vega F: Early-stage mycosis fungoides variants: case-based review. *Ann Diagn Pathol* 2010;14:369–385.
- 5 Haghghi B, Smoller BR, LeBoit PE, Warnke RA, Sanders CA, Kohler S: Pagetoid reticulosis (Woringer-Kolopp disease): an immunophenotypic, molecular, and clinicopathologic study. *Mod Pathol* 2000;13:502–510.
- 6 Ally MS, Obson A: A review of the solitary cutaneous T-cell lymphomas. *J Cutan Pathol* 2014;41:703–714.
- 7 McNiff JM, Schechner JS, Crotty PL, Glusac EJ: Mycosis fungoides palmaris et plantaris or acral pagetoid reticulosis? *Am J Dermatopathol* 1998;20:271–275.
- 8 Leinweber B, Chott A, Kerl H, Cerroni L: Epidermotropic precursor T-cell lymphoma with highly aggressive clinical behavior simulating localized pagetoid reticulosis. *Am J Dermatopathol* 2007;29:392–394.
- 9 Grubb B, Henderson DB, Pandya AG: Adult T-cell lymphoma/leukemia presenting as pagetoid reticulosis of the palms and soles. *J Am Acad Dermatol* 2009;65:1063–1064.
- 10 Tomasini D, Niccoli A, Crivelli F: Pagetoid reticulosis tumor cells with double expression of TCR $\gamma\delta$  and TCR $\alpha\beta$ : an off-target phenomenon or genuine expression? *J Cutan Pathol* 2015;42:427–434.
- 11 Mourtzinou N, Puri PK, Wang G, Liu ML: CD4/CD8 double negative pagetoid reticulosis: a case report and review of the literature. *J Cutan Pathol* 2010;37:491–496.
- 12 Morariu SH, Rotaru M, Vartolomei MD, Turcu M, Chiotoroiu AL, Siciu M, Cotoi OS: Pagetoid reticulosis, Woringer-Kolopp type, a particular variant of mycosis fungoides: a case report. *Rom J Morphol Embryol* 2014;55:1469–1472.
- 13 Scarabello A, Fantini F, Ginannetti A, Cerroni L: Localized pagetoid reticulosis (Woringer-Kolopp disease). *Br J Dermatol* 2002;147:806.
- 14 Miedler J, Gould J, Tamburro J, Gilliam A: Pagetoid reticulosis in a 5 year old boy. *J Am Acad Dermatol* 2008;58:679–681.
- 15 Lichte V, Ghoreschi K, Metzler G, Mohrle M, Geyer A, Rocken M, Schaller M: Pagetoid reticulosis (Woringer-Kolopp) disease. *J Deutsch Dermatol Ges* 2009;7:353–354.
- 16 Martin SJ, Cohen PR, Cho-Vega JH, Tschen JA: CD8+ pagetoid reticulosis presenting as a solitary foot plaque in a young woman. *J Clin Aesth Dermatol* 2010;3:46–49.
- 17 Pedrosa AF, Ferreira P, Barros AM, Nogueira A, Bettencourt H, Azevedo F: Case for diagnosis. *Ann Bras Dermatol* 2013;88:824–825.
- 18 Sedghizadeh PP, Allen CM, Kalmar JR, Magro CM: Pagetoid reticulosis: a case report and review of the literature. *Oral Maxillofac Pathol* 2002;95:318–323.
- 19 Carlesimo M, Tammara A, Cox C, Mari E, Fidanza L, Narcisi A, Cacchi C, Camplone G: A case of Ketron-Goodman disease. *Case Rep Dermatol* 2009;1:39–43.
- 20 Suzaki R, Kobayashi K, Ishiaki S, Fujibayashi M, Tanaka M: Dermatoscopic features of CD8 positive solitary pagetoid reticulosis on the left leg. *Dermatol Res Pract* 2010, DOI: 10.1155/2010/850416.
- 21 Wang T, Liu YH, Zheng HY: Localized pagetoid reticulosis (Woringer-Kolopp disease): complete response to NB-UVB combined with IFN. *Dermatol Ther* 2014;27:227–229.
- 22 Lee J, Viakhireva N, Cesca C, Lee P, Kohler S, Hoppe RT, Kim YH: Clinicopathological features and treatment outcomes in Woringer-Kolopp disease. *J Am Acad Dermatol* 2008;59:706–712.
- 23 Mount C, Ferraro D, Gru A, Bradbury M, Cornelius L, Gay H: Treatment of pagetoid reticulosis with intensity modulated radiation therapy. *Dermatol Online J* 2014;20. pii: 13030/qt67d7n40j.
- 24 Su O, Dizman D, Onsun N, et al: Treatment of localized pagetoid reticulosis with imiquimod: a case report and review of the literature. *J Eur Acad Dermatol Venereol* 2016;30:324–326.
- 25 Schmitz L, Bierhoff E, Dirschka T: Alitretinoin: an effective treatment option for pagetoid reticulosis. *J German Soc Dermatol* 2013;11:1194–1195.
- 26 Jung SE, Kim YC: A case of pagetoid reticulosis treated with fractional laser- assisted photodynamic therapy. *Clin Exp Dermatol* 2015;40:468–470.
- 27 Mendes GW, Beckford A, Krejci N, Mahalingam M, Goldberg L, Gilchrist BA: Pagetoid reticulosis in a prepubescent boy successfully treated with photodynamic therapy. *Clin Exp Dermatol* 2012;37:759–761.