

Carcinoid Tumor of the Cystic Duct: Case Report, Literature Review and Comparison of Surgical Approaches

Jennifer Garland^a Elizabeth O'Leary^a Joseph Haggerty^b
Thomas G. Zorc^a

^aChevy Chase Surgical Associates, P.C., Chevy Chase, Md., and ^bOncology and Hematology Associates, Bethesda, Md., USA.

Key Words

Carcinoid · Cystic duct · Laparoscopic resection

Abstract

We present the case of a 48-year-old female with a cystic duct carcinoid that was found incidentally upon laparoscopic cholecystectomy. The patient subsequently underwent excision of the cystic duct remnant. This is the tenth reported case of a cystic duct carcinoid and the second reported laparoscopic excision.

© 2014 S. Karger AG, Basel

Introduction

Carcinoid tumors of the gastrointestinal (GI) tract are rare, frequently indolent and have a high survival rate without metastasis [1]. They are variable and present with nonspecific symptoms, thus making a diagnosis difficult [1]. An extremely rare site of GI carcinoid tumor is the extrahepatic biliary tree, harboring 0.1–0.2% of all GI tumors [2]. In the extrahepatic biliary tree, cystic duct carcinoids represent 11% [3] of all reported cases.

Case Report

A 48-year-old female presented with right upper quadrant and epigastric pain, also complaining of nausea, vomiting and diarrhea. She was first examined in the emergency room, where a sonogram identified a normal gallbladder with no evidence of gallstones, no thickening of the gallbladder wall and no pericholecystic fluid. A Disida scan identified a

Jennifer Garland
Chevy Chase Surgical Associates, P.C.
5530 Wisconsin Avenue, Suite 1455
Chevy Chase, MD 20815 (USA)
E-Mail jgarland@chevychasesurgical.com

delayed visualization of the gallbladder and small bowel, which is consistent with biliary dyskinesia. A liver panel was ordered and the total bilirubin was 2.2 mg/dl (normal range: 0.3–1.5), ALT (SGPT) was 475 IU/l (normal range: 5–60), AST (SGOT) was 630 IU/l (normal range: 15–43) and the alkaline phosphatase was 158 IU/l (normal range: 34–121).

The patient's case was complicated as she was being treated for complex Lyme's disease with co-infections of babesiosis and Bartonella. She was taking Factive (fluoroquinolone), azithromycin, minocycline and IV Rocephin (a ceftriaxone antibiotic). Gallbladder disease symptoms have been reported with the use of ceftriaxone [4].

A follow-up liver panel performed 8 days after emergency room consultation was within normal limits. Follow-up ultrasound performed 2 weeks after emergency room consultation identified what appeared to be 1–2 stones in the neck of the gallbladder.

A laparoscopic cholecystectomy was recommended and performed uneventfully, and the patient did well postoperatively. The surgical pathology identified an incidental carcinoid tumor in the cystic duct measuring up to 2.5 mm without a negative margin. The tumor cells were positive for keratin, synaptophysin and chromogranin.

The identification of the carcinoid tumor led to further evaluation and imaging, which was done prior to the reoperation to remove the remaining tumor and obtain clear margins. An MRI of the abdomen with and without contrast identified a 13-mm remnant of the cystic duct. Imaging revealed no obvious residual carcinoid or metastatic disease. Surgery was performed with laparoscopic removal of the cystic duct remnant and the pathology report identified a cystic duct remnant with no evidence of residual carcinoid tumor. At follow-up by a medical oncologist, the patient had a normal serum serotonin level. At a subsequent follow-up 4 years after the laparoscopic excision, the patient had a normal physical examination and normal liver ultrasound with no evidence of metastasis.

Discussion

A literature review identified only 9 previously reported cases of cystic duct carcinoids (table 1). Of these, only 1 case was reported to be laparoscopically excised.

A carcinoid of the cystic duct arises from enterochromaffin cells, which are neuroendocrine cells of the GI tract [5]. These tumors have been found to be more prevalent in women than in men (8 out of 10 cases) [3, 6]. Patients' ages range from 28 to 69 years [2, 3], and the most common preoperative complaint is right upper quadrant abdominal pain [3, 6]. All cystic duct carcinoids reported were found incidentally upon laparotomy or laparoscopy with pathologic analysis.

As there are so few cases reported of cystic duct carcinoids, the surgical standard of care has yet to be established. Laparoscopic or open surgery is performed to obtain clear margins. In the only other reported laparoscopic removal of the cystic duct carcinoid [3], a Roux-en-Y hepaticojejunostomy was performed in conjunction with the excision of a large mesenteric lymph node. In this case, the patient had locoregional disease.

We propose that if the cystic duct carcinoid is small and there is no common duct involvement, a complete laparoscopic resection of the cystic duct can be performed without injuring the common bile duct (fig. 1). This obviates the need for common bile duct excision and reconstruction of the biliary tree. Laparoscopic resection is possible if negative margins are achieved and no involvement of the regional lymph nodes can be confirmed. Metastasis to the regional lymph nodes and the liver are the most common sites reported [2, 6]. In cystic duct carcinoids, metastasis is infrequent, occurring in 2 of the 10 cases [2].

In conclusion, carcinoid of the cystic duct is quite rare and difficult to diagnose. Thus far, surgical resection is the primary modality of treatment [2]. Our case demonstrates the excellent outcome of a laparoscopic resection (fig. 2). In suitable patients, it can be performed to obtain clear margins, obviating the need for common bile duct resection or complex biliary tree reconstruction.

Disclosure Statement

The authors have no conflicts of interest to declare.

References

- 1 National Cancer Institute: General information about gastrointestinal carcinoid tumors. Health professional version. <http://www.cancer.gov>.
- 2 Felekouras E, Petrou A, Bramis K, et al: Malignant carcinoid tumor of the cystic duct: a rare cause of bile duct obstruction. *Hepatobiliary Pancreat Dis Int* 2009;8:640–646.
- 3 Lim HU, Chan CC, Knotts FB: An incidental finding of carcinoid tumor of the cystic duct. *J Surg Case Rep* 2013, DOI: 10.1093/jscr/rjt021.
- 4 The American Association of Endocrine Surgeons: Background: neuroendocrine tumor/carcinoid tumor features. Patient education site. 2013. <http://endocrinediseases.org>.
- 5 Menezes AAC, Diver AJ, McCance D, Diamond T: Carcinoid tumour of the extrahepatic bile duct – report of a case and literature review. *Ulster Med J* 2004;73:59–62.
- 6 Zinberg J, Chernaik R, Coman E, Rosenblatt R, Brandt LJ: Reversible symptomatic biliary obstruction associated with ceftriaxone pseudolithiasis. *Am J Gastroenterol* 1991;86:1251–1254.
- 7 Goodman Z, Albores-Saavedra J, Lundblad D: Somatostatinoma of the cystic duct. *Cancer* 1984;53:498–502.
- 8 Nicolescu PG, Popescu A: Carcinoid tumor of the cystic duct. *Morphol Embryol (Bucur)* 1986;32:275–277.
- 9 Chittal SM, Ra PM: Carcinoid of the cystic duct. *Histopathology* 1989;15:643–646.
- 10 Rugge M, Sonogo F, Militello C, Guido M, Ninfo V: Primary carcinoid tumor of the cystic and common bile ducts. *Am J Surg Pathol* 1992;16:802–807.
- 11 Meyer CN, Geerdsen J, Christensen N: Limited surgical excision of a localized carcinoid tumour of the cystic duct. *Dig Surg* 1997;14:423–425.
- 12 Shah IA, Schlageter MO, Wong SX, Gani OS: Carcinoid tumor of the cystic duct. *Dig Surg* 1998;15:372–373.
- 13 Hermina M, Starling J, Warner TF: Carcinoid tumor of the cystic duct. *Pathol Res Pract* 1999;195:707–709.

Table 1. Patient data of reported cystic duct carcinoids

Case	Authors [ref.], year	Age	Sex	Preoperative complaint	Metastasis
1	Goodman et al. [7], 1984	28	F	Right upper quadrant pain	Lymph node
2	Nicolescu and Popescu [8], 1986	50	F	Right upper quadrant pain	None
3	Chittal and Ra [9], 1989	46	F	Right upper quadrant pain	None
4	Rugge et al. [10], 1992	64	M	Jaundice	None
5	Meyer et al. [11], 1997	56	F	Right upper quadrant pain	None
6	Shah et al. [12], 1998	52	F	Right upper quadrant pain	None
7	Hermina et al. [13], 1999	69	M	Right upper quadrant pain	Lymph node
8	Felekouras et al. [2], 2007	60	F	Jaundice	None
9	Lim et al. [3], 2012	58	F	Right upper quadrant pain	None
10	Present case, 2014	48	F	Right upper quadrant pain	None

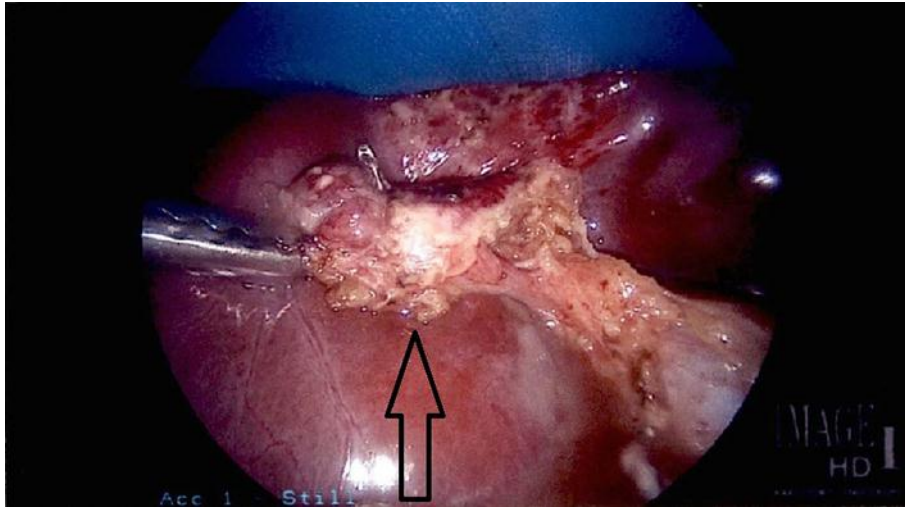


Fig. 1. Cystic duct remnant retracted.

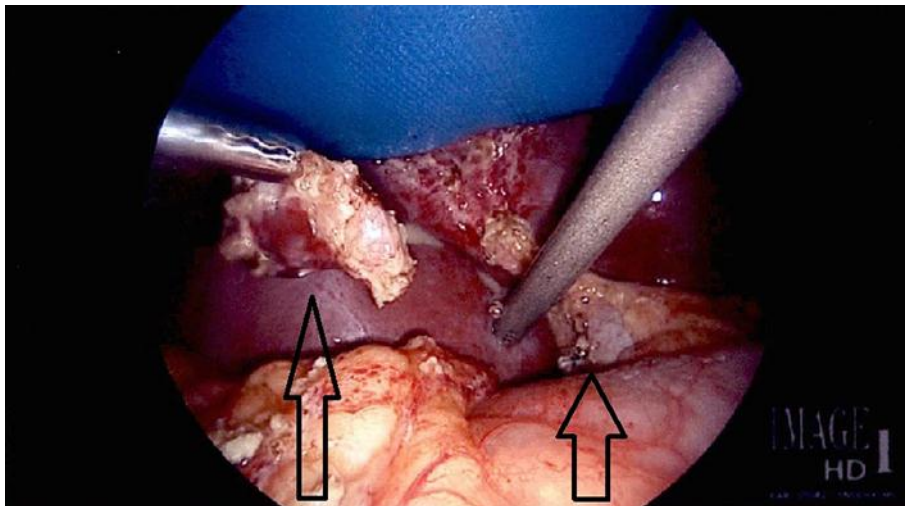


Fig. 2. Cystic duct remnant (long arrow). Common bile duct retracted (short arrow).