

Case Report

Metastatic Small Cell Carcinoma of the Breast from Cancer of the Uterine Cervix: A Case Report

Beom Seok Kwak

Department of Surgery, College of Medicine, Dongguk University,
Goyang, Republic of Korea

Keywords

Small cell carcinoma · Breast · Metastasis

Abstract

We report here on a case of 51-year-old woman with metastatic small cell carcinoma of the breast that came from her cancer of the uterine cervix. She underwent radical hysterectomy with bilateral salpingo-oophorectomy due to small cell carcinoma of the uterine cervix, and adjuvant radiotherapy was administered to the pelvis. Breast metastasis with a palpable mass then occurred 3 months after the primary surgery. Simple mastectomy and adjuvant chemotherapy were performed. She initially showed a good response to the therapy, yet she ultimately died of multiple metastases with a fulminating disease course. This is an extremely rare case, and only 1 similar case has been reported earlier, so we report on this case along with a review of the relevant literature.

© 2018 The Author(s)
Published by S. Karger AG, Basel

Introduction

Although primary breast cancer is the most common female cancer in Korea and western countries [1–3], breast metastases from extramammary malignancies are uncommon, constituting only about 2% of all breast malignancies [4]. Any malignancy may metastasize

to the breast. Lymphoma, melanoma, rhabdomyosarcoma, lung, and ovarian carcinomas are the most common extramammary sources [5].

Extrapulmonary small cell carcinoma (SCC) is an uncommon malignancy that shares many of the clinical and pathological characteristics of pulmonary SCC, and is a biologically aggressive tumor with a high rate of metastasis [6–10]. Primary SCC of the uterine cervix is a rare neuroendocrine tumor constituting up to 6% of all uterine cervical cancers with about 200 reported cases [11, 12]. Metastatic SCC of the breast from the uterine cervix is extremely rare, and only 1 case has been reported [13].

Case Report

A 51-year-old postmenopausal woman presented with a month of vaginal bleeding. An MRI revealed a 9.0-cm diameter, well-defined bulging mass at the posterior lip of the uterine cervix with upper vaginal involvement, but there was no evidence of distant metastases. These findings were compatible with uterine cervical cancer. First, a radical hysterectomy and a bilateral salpingo-oophorectomy were performed. The tumor size was 6.0 × 6.0 × 3.0 cm involving the full thickness of the cervix. There was no parametrial or uterine invasion, but lymphovascular invasion was present and 7 out of 34 dissected lymph nodes were involved. Thus, the FIGO stage was IIb. Immunohistochemical staining showed tumor cells positive for synaptophysin and chromogranin (Fig. 1a, b). These findings were consistent with SCC of the uterine cervix. Adjuvant radiation therapy (4,860 cGy) to the pelvic region was performed.

Three months after the primary surgery, the patient was referred to the department of breast surgery with a palpable painless lump in the right breast. A 3.0-cm sized, well-circumscribed, round, movable, non-tender, and hard mass was palpated in the upper outer quadrant of the right breast with no associated axillary lymphadenopathy. Mammograms showed a 2.5-cm sized, well-defined, round, and lobulated mass in the upper outer quadrant of the right breast, suggesting a well-circumscribed breast cancer (Fig. 2a). Ultrasound examination demonstrated 3.0 × 3.0 × 3.0 cm and 1.7 × 1.0 × 2.0 cm sized heterogeneous, hypoechoic, irregular-margined masses in the right breast (Fig. 2b). These masses showed prominent blood flow on a color Doppler image, consistent with breast cancer. Fine needle aspiration cytology was performed. Tumor cells with diffuse and strongly positive immunohistochemical staining for synaptophysin and chromogranin, respectively, were observed. These results supported the diagnosis of SCC. A right simple mastectomy without axillary lymph node dissection was performed. Surgical pathology revealed 4.0 × 4.0 × 3.8 cm and 2.5 × 2.5 × 2.3 cm sized carcinomas without any intraductal component. The tumors had no involvement of the nipple or skin, but lymphovascular invasion was seen. The surgical resection margins were clear. The findings of multiple lesions, the absence of in situ carcinoma, well-demarcated tumors, and a history of SCC were compatible with the diagnosis of metastatic SCC (Fig. 2c). Immunohistochemical staining showed tumor cells strongly positive for synaptophysin and chromogranin (Fig. 2d) and negative for CK-20 and CK-7. These findings supported the diagnosis.

Two weeks after surgery, 3.0- and 1.0-cm sized masses were palpated in the lateral portion of the right chest wall. The patient received adjuvant chemotherapy with an EP regimen (etoposide and cisplatin). After the first cycle of chemotherapy, the masses completely disappeared and could not be palpated. The masses appeared to be responsive to chemotherapy, and 6 cycles with the EP regimen were completed. However, new masses were palpated

in the right chest wall, and a bone scan showed bone metastasis in the right proximal humerus. A second phase of chemotherapy was performed with paclitaxel and carboplatin. During the chemotherapy, the patient presented with lower abdominal pain and hematochezia due to proximal ileal bleeding from a bulky tumor in the abdominal cavity. The patient died of disseminated intravascular coagulopathy.

Discussion

Extrapulmonary SCC is an uncommon malignancy that is reported as a biologically aggressive tumor with a poor prognosis [6–10]. Primary SCC of the breast is one of the least common types of breast cancer, and fewer than 25 cases have been reported in the literature. Immunohistochemical analysis of primary breast SCC demonstrated immunoreactivity for neuron-specific enolase (NSE), E-cadherin, thyroid transcription factor-1 (TTF-1), bcl-2, synaptophysin, and chromogranin. Primary SCC of the breast is characteristically CK-7 positive and CK-20 negative, whereas pulmonary SCC is negative for both [6, 9, 10]. It is difficult to distinguish metastatic breast carcinoma from primary breast carcinoma. However, some histological features are useful for the diagnosis of metastasis, such as atypical histological features for a primary breast carcinoma, a well-circumscribed tumor with multiple satellite foci, absence of an in situ intraductal component, and the presence of many lymphatic emboli [14]. Our findings, including multiple lesions, absence of in situ carcinoma, well-demarcated tumors, a history of SCC, strong positive reactions for synaptophysin and chromogranin, and negative reactions for CK-20 and CK-7 confirmed the diagnosis of metastatic SCC of the breast from the uterine cervix.

There is no standard therapy for extrapulmonary and metastatic SCC due to its rarity. However, it seems acceptable that the disease should be treated in the same manner as pulmonary SCC. The commonly used chemotherapeutic agents are etoposide and cisplatin. Despite aggressive multidisciplinary treatments, this case showed a rapid fatal clinical course. Metastatic SCC of the breast from the uterine cervix is extremely rare, and only 1 previous case has been reported [13].

Statement of Ethics

The author has no ethical conflicts to declare.

Disclosure Statement

The author has no conflicts of interest to disclose.

References

- 1 Ahn SH; Korean Breast Cancer S: Clinical characteristics of breast cancer patients in Korea in 2000. Arch Surg 2004;139:27–30.
- 2 Son BH, Kwak BS, Kim JK, Kim HJ, Hong SJ, Lee JS, Hwang UK, Yoon HS, Ahn SH: Changing patterns in the clinical characteristics of Korean patients with breast cancer during the last 15 years. Arch Surg 2006;141:155–160.

Kwak: Metastatic Small Cell Carcinoma of the Breast from Cancer of the Uterine Cervix: A Case Report

- 3 Korean Breast Cancer Society: Clinical characteristics of breast cancer patients in Korea in year 2000. *J Korean Breast Cancer Soc* 2002;5:217–224.
- 4 Toombs BD, Kalisher L: Metastatic disease to the breast: clinical, pathologic, and radiographic features. *AJR Am J Roentgenol* 1977;129:673–676.
- 5 Vizcaino I, Torregrosa A, Higuera V, Morote V, Cremades A, Torres V, Olmos S, Molins C: Metastasis to the breast from extramammary malignancies: a report of four cases and a review of literature. *Eur Radiol* 2001;11:1659–1665.
- 6 Samli B, Celik S, Evrensel T, Orhan B, Tasdelen I: Primary neuroendocrine small cell carcinoma of the breast. *Arch Pathol Lab Med* 2000;124:296–298.
- 7 Jochems L, Tjalma WA: Primary small cell neuroendocrine tumour of the breast. *Eur J Obstet Gynecol Reprod Biol* 2004;115:231–233.
- 8 Galanis E, Frytak S, Lloyd RV: Extrapulmonary small cell carcinoma. *Cancer* 1997;79:1729–1736.
- 9 Shin SJ, DeLellis RA, Ying L, Rosen PP: Small cell carcinoma of the breast: a clinicopathologic and immunohistochemical study of nine patients. *Am J Surg Pathol* 2000;24:1231–1238.
- 10 Shin SJ, DeLellis RA, Rosen PP: Small cell carcinoma of the breast – additional immunohistochemical studies. *Am J Surg Pathol* 2001;25:831–832.
- 11 Morris M, Gershenson DM, Eifel P, Silva EG, Mitchell MF, Burke TW, Wharton JT: Treatment of small cell carcinoma of the cervix with cisplatin, doxorubicin, and etoposide. *Gynecol Oncol* 1992;47:62–65.
- 12 Collinet P, Lanvin D, Declerck D, Chevalier-Place A, Leblanc E, Querleu D: Neuroendocrine tumors of the uterine cervix. Clinicopathologic study of five patients. *Eur J Obstet Gynecol Reprod Biol* 2000;91:51–57.
- 13 Chang DH, Hsueh S, Soong YK: Small cell carcinoma of the uterine cervix with neurosecretory granules associated with pregnancy. A case report. *J Reprod Med* 1994;39:537–540.
- 14 Vergier B, Trojani M, de Mascarel I, Coindre JM, Le Treut A: Metastases to the breast: differential diagnosis from primary breast carcinoma. *J Surg Oncol* 1991;48:112–116.

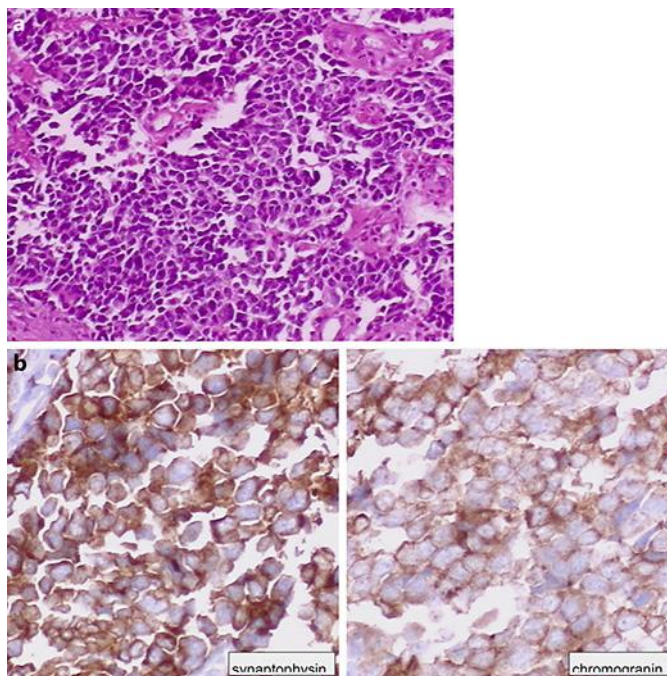


Fig. 1. a Microscopic findings of the hysterectomy specimen showed small cell carcinoma. H&E stain. $\times 200$. b Immunohistochemical (IHC) staining showed tumor cells positive for synaptophysin and chromogranin. IHC stain. $\times 400$.

Kwak: Metastatic Small Cell Carcinoma of the Breast from Cancer of the Uterine Cervix: A Case Report

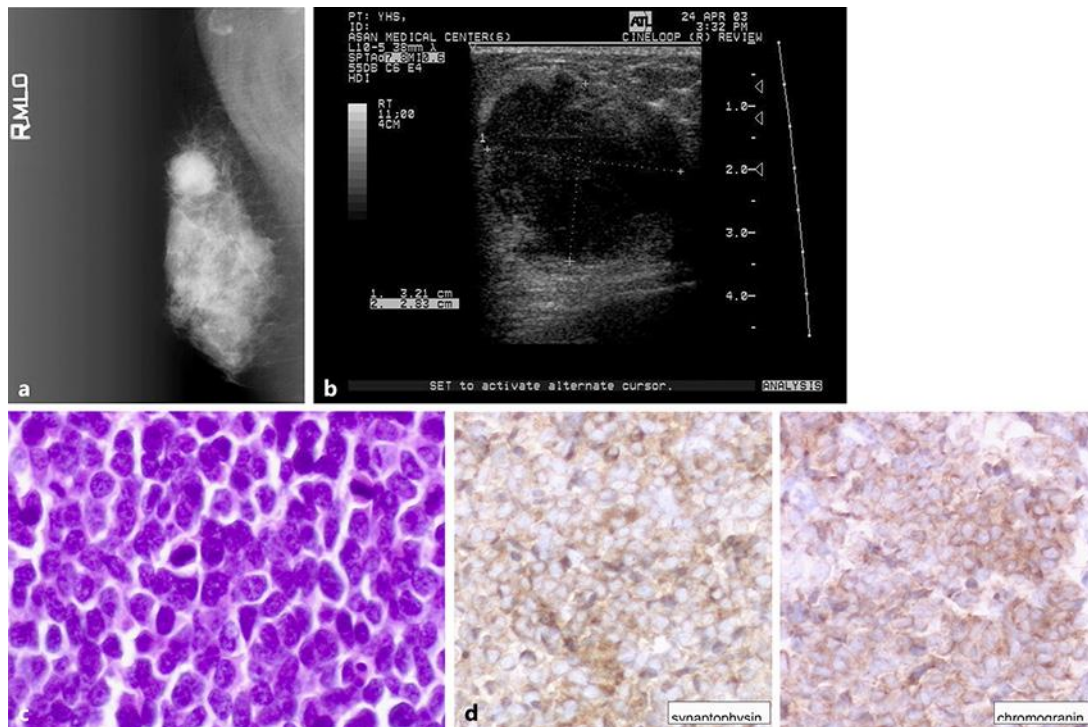


Fig. 2. **a** Mammograms showed a well-defined, round, and lobulated mass in the upper outer quadrant of the right breast. **b** Ultrasound examination demonstrated 3.0-cm sized heterogeneous, hypoechoic, irregular-margined masses of the right breast. **c** Microscopic findings of the mastectomy specimen were compatible with the diagnosis of metastatic small cell carcinoma. H&E stain. $\times 400$. **d** By immunohistochemical (IHC) staining, the tumor cells were strongly positive for synaptophysin and chromogranin. IHC stain. $\times 400$.