

Liver Abscess following Hematogenous Transmission due to Rectal Foreign Body Perforation

Martin Kobborg Rete Trap

Hospital of Southern Jutland, Aabenraa, Denmark

Key Words

Pyogenic liver abscess · Hematogenous transmission · Foreign body · Gastrointestinal perforation · Rectum perforation

Abstract

Liver abscess caused by hematogenous transmission from a gastrointestinal perforation by a foreign body is a rare but life-threatening condition. We present the case of a 57-year-old male with a pyogenic liver abscess generated on the basis of a foreign body perforation of the rectum. This has not been reported previously. During the examination of the patient, computed tomography scan showed not only the liver abscess but also an inflammatory presacral process, which communicated with the rectum through a 6.5-cm-long foreign body. Subsequent sigmoidoscopy showed a toothpick placed transmurally in the rectum; the toothpick was removed endoscopically. We discuss the importance of computed tomography scans and colonoscopies in relation to liver abscesses of unknown etiology, including the importance of detecting possible perforation caused by possible foreign bodies, polyps or cancer.

© 2013 S. Karger AG, Basel

Introduction

Liver abscesses are frequently the result of a defect of the bowel or gallbladder wall. There are two mechanisms that may lead to development of a liver abscess: firstly local transmission and secondly hematogenous transmission, where rupture or breakdown of the bowel wall allows portal drainage of bacterial material to the liver [1, 2].

Liver abscess due to hematogenous transmission from a gastrointestinal perforation caused by a foreign body is a rare and life-threatening condition [1–3]. This report describes

Martin Kobborg
Hospital of Southern Jutland
Kresten Philipsens Vej 15
DK-6200 Aabenraa (Denmark)
E-Mail martin.kobborg@rsyd.dk

a patient with a liver abscess caused by toothpick perforation of the rectum. Similar cases have not been described before. In this paper we discuss the advantages and disadvantages of the different diagnostic modalities.

Case Presentation

A 57-year-old male was referred for a colonoscopy due to bleeding from the rectum and rectal pain, but the colonoscopy could not be carried through as the patient was not sufficiently depleted. The next day the patient was admitted due to abdominal pain, hypotension and elevated white blood cell count (leukocytes $14 \times 10^9/l$) and C-reactive protein (200 mg/l). He was suspected to have cholecystitis and was started on antibiotic treatment, intravenous cefuroxime and metronidazole. Ultrasound examination showed no signs of cholecystitis but revealed a process of 5.5 cm in the right liver lobe, interpreted as a thrombosed hemangioma. The following magnetic resonance scan showed a liver abscess, which was drained percutaneously. Microbiological examination of the drain secretion only demonstrated growth of *Streptococcus gordonii*.

A computed tomography (CT) scan was performed to clarify the etiology of the abscess. To our surprise a 3-cm-large presacral process was found with connection to the rectum via a 6.5-cm-long foreign body, similar to a toothpick (indicated by the arrows in [fig. 1](#)). Subsequent sigmoidoscopy showed a toothpick placed transmurally in the rectum. During the sigmoidoscopy the toothpick was removed with a forceps ([fig. 2](#)). The patient had no memory of swallowing a toothpick.

After 15 days the patient was discharged, with a normal white blood cell count, C-reactive protein and a CT scan which verified regression of both the liver and sacral abscess.

Discussion

Pyogenic liver abscesses caused by endogenous transmission of pus-producing bacteria are rare. They are often caused by bacteria from the biliary tract, either in connection with illness, e.g. cholangitis, or in connection with interventions in the biliary tract, e.g. endoscopic retrograde cholangiopancreatography [3]. Other causes of pyogenic liver abscesses are appendicitis, pancreatitis, diverticulitis or perforation of the small or large intestine by foreign bodies, colonic cancer or high-grade polyps [3, 4]. In the case of foreign body perforation the liver abscess is often formed by perforation of the upper gastrointestinal tract directly into the liver, but in rare cases the abscess is formed due to hematogenous transmission. In such cases the bacteria are transmitted through the portal venous system to the liver, as seen in our case [2, 5].

If microbiological examination of the abscess material shows multiple microorganisms, this indicates direct perforation from the intestine into the liver. Detection of only one microorganism in the material indicates hematogenous transmission [2, 3]. *Escherichia coli*, *Streptococcus*, *Klebsiella* and *Bacteroides* species are often shown in connection with pyogenic abscesses [3]. This is in line with our findings of only one microorganism, *S. gordonii*.

In our case the liver abscess was formed due to perforation of the rectum by a toothpick. In most such cases the foreign body will pass through the gastrointestinal tract without complications, perforation only occurring in 1% of cases [2, 3, 5].

Diagnostic imaging of liver abscesses is undertaken by ultrasound or through CT scan. In most cases ultrasound will be the primary choice due to ease of access. However, in com-

parison with ultrasound, CT scanning has a higher sensitivity and specificity in detecting liver abscesses and is also advantageous in detecting other pathological processes [2, 3].

It is recommended that patients with liver abscesses without known etiology be examined by colonoscopy to exclude perforation due to colonic cancer [2, 3]. A colonoscopy study of patients with liver abscesses without known etiology found that 7.4% of patients had colonic cancer and 4.9% had polyps with high-grade dysplasia [4]. Moreover, colonoscopy is recommended to identify a perforation and in the removal of a foreign body [2, 3].

In the present case the liver abscess, the rectal perforation and the toothpick were shown by CT scan. Sigmoidoscopy showed the endoluminal perforation and the toothpick was readily removed. This case emphasizes the importance of causal investigation in patients with liver abscesses with unknown etiology. Liver abscess on the basis of hematogenous transmission due to foreign body perforation of the gastrointestinal tract should be considered [1], especially if supported by microbiological examination.

The advantage of using a CT scan is shown, as the abscess, the perforation and the foreign body were detected using this method. The advantage of colonoscopy is also demonstrated as the perforation and the foreign body were detected and the foreign body was endoscopically removed. At the same time, colonoscopy can be used to identify if the perforation is due to colonic cancer and/or polyps.

References

- 1 Gundara JS, Harrison R: An unusual zoonosis: liver abscess secondary to asymptomatic colonic foreign body. *HPB Surg* 2010;2010:794271.
- 2 Bilimoria KY, Eagan RK, Rex DK: Colonoscopic identification of a foreign body causing a hepatic abscess. *J Clin Gastroenterol* 2003;37:82–85.
- 3 Serwe S, Weber J, Strock P, Lens V: Liver abscess caused by an unnoticed swallowed toothpick perforating the colonic wall. *Z Gastroenterol* 2007;45:1060–1062.
- 4 Koo HC, Kim YS, Kim SG, Tae JW, Ko BM, Lee TI, Jeong SW, Jang JY, Kim HS, Lee SH, Kim BS: Should colonoscopy be performed in patients with cryptogenic liver abscess? *Clin Res Hepatol Gastroenterol* 2013;37:86–92.
- 5 Santos SA, Alberto SC, Cruz E, Pires E, Figueira T, Coimbra E, Estevez J, Oliveira M, Novais L, Deus JR: Hepatic abscess induced by foreign body: case report and literature review. *World J Gastroenterol* 2007;13:1466–1470.

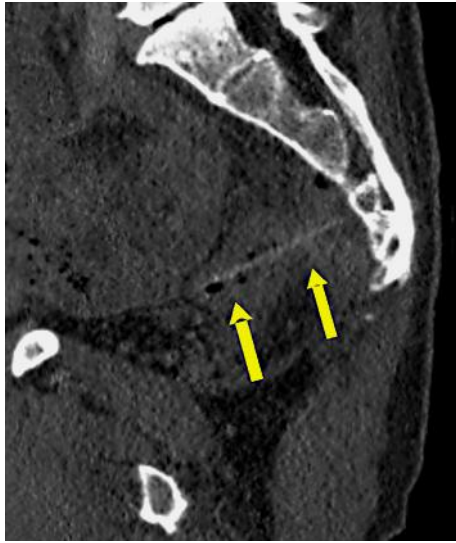

Fig. 1. CT scan showing a rectal perforation caused by a foreign body. The arrows indicate the toothpick perforating the rectum.

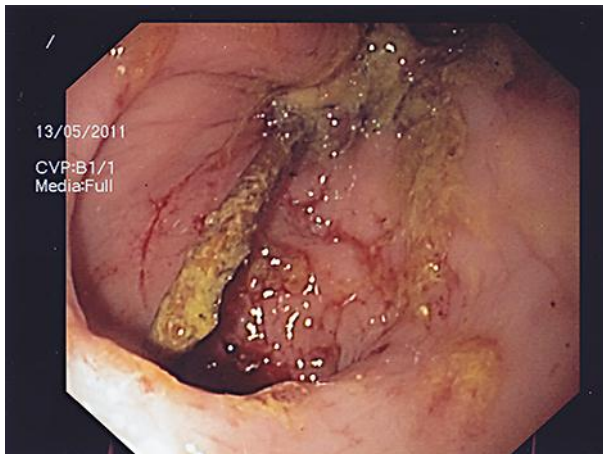


Fig. 2. Sigmoidoscopy image showing the toothpick perforating the rectal wall.