

Double-Balloon Enteroscopy to Remove a Strangulated Enteroclysis Catheter from the Small Bowel

Tom G. Moreels^a Bart Op de Beeck^b Paul A. Pelckmans^a

Divisions of ^aGastroenterology & Hepatology and ^bRadiology, Antwerp University Hospital, Antwerp, Belgium

Key Words

Magnetic resonance enteroclysis · Complication · Double-balloon enteroscopy

Abstract

We present the case of a 77-year-old male who was referred for magnetic resonance (MR) enteroclysis because of small bowel subobstruction. To optimise small bowel distention during MR, a nasojejunal balloon catheter was placed to perfuse iso-osmotic water solution into the small bowel. However, after deflation of the balloon, the catheter could not be removed by gentle traction. Subsequently, computed tomography (CT) of the abdomen revealed that the catheter was strangulated deep in the jejunum and traction resulted in painful backward intussusception of the small bowel. In order to avoid surgical intervention, we decided to perform urgent proximal double-balloon enteroscopy to remove the enteroclysis catheter. Under fluoroscopic guidance, the enteroscope was introduced into the jejunum until the tip of the enteroscope reached the tip of the catheter. By straightening the enteroscope, the catheter could then be retracted from the jejunum, using the enteroscope as a guide wire along the catheter. Urgent surgical intervention was avoided and the patient completely recovered the same day.

Introduction

Magnetic resonance (MR) enteroclysis has been shown to be a valuable radiologic tool to investigate small bowel pathology [1–3]. In order to achieve adequate luminal distention, iso-osmotic water solution is instilled into the small bowel by means of a nasojejunal balloon catheter [4, 5]. This catheter is introduced through the nose and is then manoeuvred into the duodenum under fluoroscopic or MR guidance. Then the balloon at the tip of the catheter is inflated with air in order to further introduce the

catheter beyond Treitz' angulus along with the small bowel peristalsis. Up to 2,000 ml of an iso-osmotic water solution is instilled into the small bowel with a controlled perfusion rate for optimal luminal distention and opacification. After the investigation, the balloon is deflated and the nasojejunal catheter is removed by gentle traction. The procedure is generally considered safe and no complications have been described using MR enteroclysis.

Case Report

We present the case of a 77-year-old male who was referred from another hospital for MR enteroclysis because of small bowel subobstruction. The 155-cm-long nasojejunal balloon catheter (TEC-100 Torino Enteroclysis Catheter Set, Cook, Denmark) was easily placed under fluoroscopic guidance. Next the balloon was inflated with 10 cm³ of air allowing deeper introduction into the jejunum by propulsive activity of small bowel peristalsis. No small bowel abnormalities were revealed by MR enteroclysis. After the investigation, the balloon of the catheter was easily deflated and the catheter was gently pulled back to remove it through the nose. However, this resulted in painful strangulation of the catheter within a jejunal loop distal from Treitz' angulus. This was confirmed by urgent computed tomography (CT) scan of the abdomen, showing backward intussusception of the jejunum at the level of the tip of the catheter ([fig. 1](#)). No explanation for the intussusception was apparent on the CT scan, besides the fact that the tip of the balloon catheter was stuck inside the lumen of the intussuscepted small bowel. Probably the intussusception was caused by mere friction of the deflated balloon onto the mucosa. It was impossible to safely remove it by gentle traction ([fig. 2](#)). After discussion with the abdominal surgeon, we decided to perform urgent proximal double-balloon enteroscopy in order to attempt to remove the strangulated catheter without the need for surgical intervention. Under conscious sedation (5 mg midazolam and 50 µg fentanyl intravenously) and fluoroscopic guidance, proximal enteroscopy was performed using the therapeutic Fujinon double-balloon enteroscope EN-450T5. During the stepwise push-and-pull endoscopy procedure, the catheter remained strangulated and could not be removed. Only when the tip of the enteroscope reached the distal tip of the catheter and after straightening the enteroscope, the catheter could finally be retracted from the jejunum, using the enteroscope as a guide wire along the catheter ([fig. 3](#), [fig. 4](#)). Apart from minor mucosal friction erosions along the tract of the catheter, no luminal pathology or complications were seen during the enteroscopy. The patient fully recovered and was discharged from the hospital the same day.

Discussion

MR enteroclysis has been shown to be a useful and safe technique to detect small bowel pathology, offering excellent image quality for assessing luminal, transmural and extramural abnormalities [1–3]. The use of a nasojejunal catheter is advocated in order to optimise small bowel luminal distention and opacification with an iso-osmotic water solution. In our hospital, the commercially available 155-cm-long TEC-100 Torino Enteroclysis Catheter (Cook, Denmark) is used to this purpose. After duodenal intubation, the balloon at the tip of the catheter is inflated with 10 cm³ of air in order to further progress the catheter along with small bowel peristalsis. Although the balloon was easily deflated after the MR enteroclysis, the catheter could not be withdrawn from the jejunum, although MR and urgent CT did not reveal underlying jejunal pathology. Traction upon the catheter resulted in painful backward intussusception of the jejunum. In order to avoid urgent surgical intervention to remove the strangulated catheter, we performed a proximal double-balloon enteroscopy, and we succeeded in pulling out the catheter using the straightened enteroscope as a guide wire adjacent to the catheter.

Double-balloon enteroscopy was developed in 2001 in order to allow complete endoscopic visualisation of the small bowel [6]. Two types of Fujinon double-balloon enteroscopes are currently available [7]. The polyvalent use of the double-balloon

enteroscope beyond mere endoscopic investigation of the small bowel has been illustrated before [8, 9].

The present case shows the usefulness of the double-balloon enteroscope to remove a strangulated enteroclysis catheter from the jejunum, avoiding urgent surgical intervention.

Fig. 1. CT image of the lower abdomen showing the tip of the enteroclysis catheter surrounded by intussuscepted jejunal folds (circle). No obstructive pathology was revealed by means of the CT scan, besides the fact that the catheter had progressed very deeply into the small bowel.

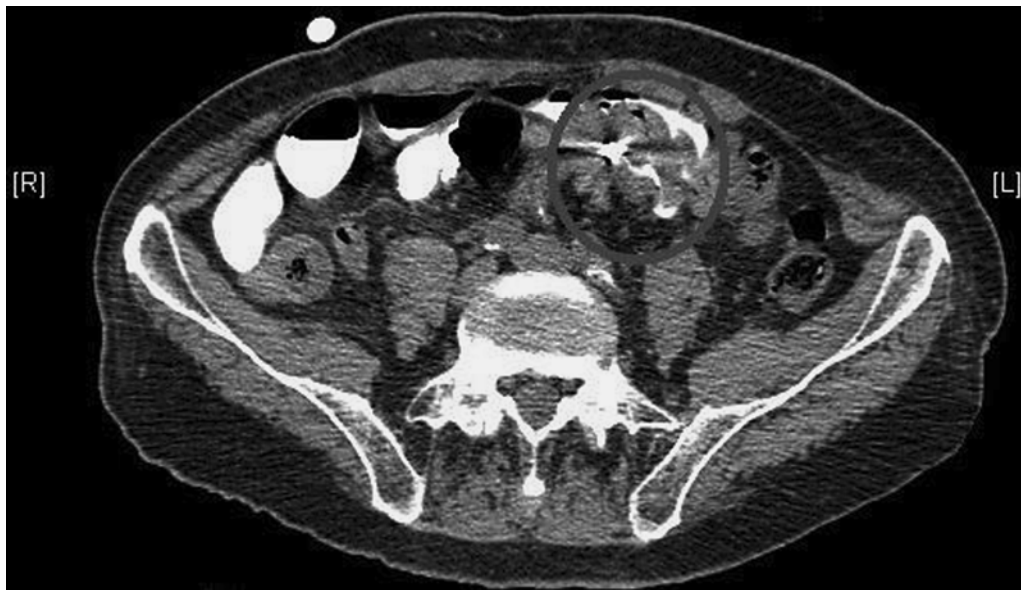

Fig. 2. Fluoroscopic position of the enteroclysis catheter deep into the small bowel with the distal tip fixed in the jejunal lumen. The catheter is introduced through the nose, passes the stomach along the lesser curvature, follows the duodenal curve and is spontaneously progressed several jejunal loops distally from Treitz' angulus.

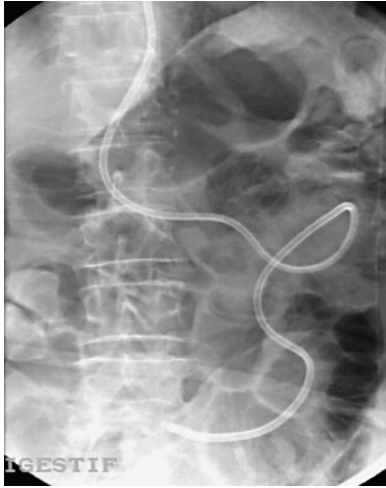


Fig. 3. Fluoroscopic position of the double-balloon enteroscope in the proximal small bowel along the enteroclysis catheter. When the enteroscope reached the distal tip of the enteroclysis catheter, it was straightened into two remaining jejunal loops. Then the enteroclysis catheter could finally be removed through the nose by gentle traction using the enteroscope as a guide wire.

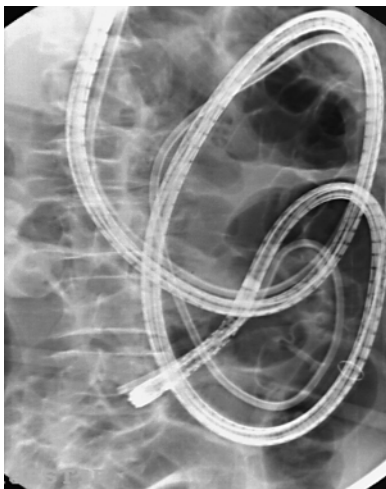
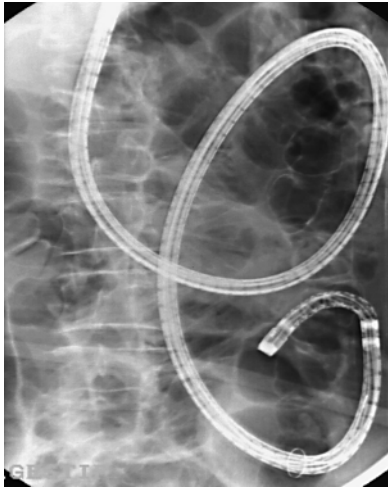

Fig. 4. Fluoroscopic control after removal of the enteroclysis catheter adjacent to the double-balloon enteroscope.



References

- 1 Ryan ER, Heaslip IS: Magnetic resonance enteroclysis compared with conventional enteroclysis and computed tomography enteroclysis: a critically appraised topic. *Abdom Imaging* 2008;33:34–37.
- 2 Fidler J: MR imaging of the small bowel. *Radiol Clin North Am* 2007;45:317–331.
- 3 Vandenbroucke F, Dujardin M, Ilsen B, Craggs B, Op de Beeck B, de Mey J: Indications for body MRI: Part II: retroperitoneum, intestines and pelvis. *Eur J Radiol* 2008;65:222–227.
- 4 Gourtsoyiannis N, Papanikolaou N, Grammatikakis J, Prassopoulos P: MR enteroclysis: technical considerations and clinical applications. *Eur Radiol* 2002;12:2651–2658.
- 5 Gourtsoyiannis N, Papanikolaou N, Karantanas A: Magnetic resonance imaging evaluation of small intestinal Crohn's disease. *Best Pract Res Clin Gastroenterol* 2006;20:137–156.
- 6 Yamamoto H, Sekine Y, Sato Y, Higashizawa T, Miyata T, Iino S, Ido K, Sugano K: Total enteroscopy with a nonsurgical steerable double-balloon method. *Gastrointest Endosc* 2001;53:216–220.
- 7 Yamamoto H: Double-balloon endoscopy. *Clin Gastroenterol Hepatol* 2005;3:S27–S29.
- 8 Moreels TG, Roth B, Vandervliet EJ, Parizel PM, Dutré J, Pelckmans PA: The use of the double-balloon enteroscope for endoscopic retrograde cholangiopancreatography and biliary stent placement after Roux-en-Y hepaticojejunostomy. *Endoscopy* 2007;39(suppl 1):E196–E197.
- 9 Moreels TG, Pelckmans PA: Double-balloon endoscope for failed conventional colonoscopy. *Clin Gastroenterol Hepatol* 2008;6:259.

Conflict of interest: There are no conflicts of interest for any of the authors.