

This article is licensed under the Creative Commons Attribution-NonCommercial 4.0 International License (CC BY-NC) (<http://www.karger.com/Services/OpenAccessLicense>). Usage and distribution for commercial purposes requires written permission.

Single Case

Recurrent Complete Pharyngo-Oesophageal Stricture Treated by Multidisciplinary Anterograde-Retrograde Endoscopic Dilatation

Paulo Castro Soares^a Salim Bouayed^b Pavel Dulguerov^b
Jean-Louis Frossard^a

^aDivision of Gastroenterology and Hepatology, Department of Internal Medicine, Geneva University Hospital, Geneva, Switzerland; ^bDepartment of Otolaryngology-Head and Neck Surgery, Geneva University Hospital, Geneva, Switzerland

Keywords

Radiation-induced pharyngo-oesophageal strictures · Anterograde-retrograde rendezvous technique · Combined anterograde-retrograde endoscopic dilatation

Abstract

Complete pharyngo-oesophageal stricture (PES) after radiotherapy for head and neck cancer is a relatively rare and difficult complication to manage. Historically this condition has been treated surgically, but endoscopic approaches are now available. We present a 61-year-old man with an epidermoid carcinoma of the supraglottic stage and a micro-invasive epidermoid carcinoma of the oropharynx treated surgically and subsequently by adjuvant radiotherapy. Eight months after the end of the radiotherapy, a complete PES was diagnosed and treated with a combined anterograde-retrograde endoscopic dilatation (CARD). The procedure was performed using a transoral anterograde progression with a rigid pharyngoscope and a retrograde progression with an extra-slim nasal endoscope using the percutaneous gastrostomy already in place. Using both transillumination and direct visualisation from both sides of the complete stenosis patency was restored between the neopharynx and the oesophagus. Despite the use of an endoprosthesis, the complete PES recurred and the technique had

to be performed a second time. Illustrating the complexity of the case different types of endoprosthesis and several dilations had to be performed for our patient to achieve and maintain a normal oral intake. This case report illustrates that even in complicated recurrent radiation-induced complete PES a CARD can be performed safely and successfully using different types of endoprosthesis.

© 2016 The Author(s)

Published by S. Karger AG, Basel

Introduction

Radiation-induced pharyngo-oesophageal strictures (PES) are relatively frequent complications in head and neck cancer patients. Complete PES is rarer and has been associated with several risk factors such as higher radiation exposure (over 50–60 Gy), radiation site (hypopharynx, pharyngeal constrictors and oesophagus), fractionation schedules, combined chemotherapy, laryngeal and hypopharyngeal cancers, female gender, high-grade mucositis and pre-treatment presence of nasogastric and gastrostomy tubes [1, 2].

Historically complete PES has been treated by surgical resection such as oesophagostomy with colonic interposition or gastric transposition, techniques associated with considerable morbidity and mortality [3]. The anterograde-retrograde rendezvous technique, also known as combined anterograde-retrograde endoscopic dilation (CARD), was first described by van Twisk et al. [4] in 1998. Even though it is not a very recent technique, only rare case series and case reports have been published and its use remains limited.

We report on a patient with a hypopharynx tumour treated with total circular pharyngolaryngectomy, pharyngeal reconstruction and adjuvant radiotherapy that developed a complete PES treated twice with CARD, due to recurrence, and requiring several different types of endoprosthesis and serial dilations to achieve and maintain a normal oral intake.

Case Presentation

A 61-year-old man presented a progressive odynophagia, dysphagia and a 15-kg weight loss over a 6-month period. He had considerable tobacco consumption (80 pack-years) and he usually drank 10 units of alcohol a day.

Physical examination revealed a mass occupying the larynx including both pyriform sinus and the epiglottic vallecula. A second suspect lesion was also observed at the posterior wall of the oropharynx at the palatine uvula level. Lymphadenopathies of the jugular lymph nodes were also palpable. The rest of the examination was unremarkable.

Endoscopy confirmed the pharyngolaryngeal lesions and another lesion was detected at the thyroid cartilage. Histology revealed an invasive, moderately differentiated epidermoid carcinoma of the supraglottic stage and a micro-invasive epidermoid carcinoma of the oropharynx.

Surgery was performed with total circular pharyngolaryngectomy, cervical lymph node dissection and pharyngeal reconstruction with a graft from the forearm. The final TNM classification after the resection was pT4a pN0 M0.

Soon after the surgery, a pharyngostoma developed delaying the start of the radiotherapy to the 11th week after resection. Thirty-three sessions of radiotherapy over 12 weeks were performed for a total dose of radiation of 66 Gy. A surgical percutaneous gastrostomy (PEG) was performed beforehand to ensure satisfactory nutrition.

Eight months after the end of the radiotherapy a videofluoroscopy was performed due to aphagia with salivary reflux (fig. 1). This examination showed a complete obstruction of the neopharynx with total blockage of the passage to the oesophagus. A CARD was then proposed for the treatment of this complication.

The following technique was performed:

- Anterograde progression performed transorally with a rigid pharyngoscope until visualisation of the complete stenosis of the neopharynx (fig. 2).
- Removal of the PEG tube and retrograde progression of the extra-slim nasal endoscope (Olympus, Tokyo, Japan) through the PEG tube gastrostomy into the stomach and then to the cervical oesophageal side of the stenosis.
- Using the transillumination by the extra-slim endoscope as point of reference, a trocar needle (Cook Medical, Winston Salem, N.C., USA) was used to puncture directly into the oesophagus.
- A guide-wire (Jagwire™ Boston Scientific, Natick, Mass., USA) with 0.025 in of outer diameter was advanced through the needle from the pharyngeal side to the upper oesophagus and recuperated with a biopsy forceps (Radial Jaw™ 4, Boston Scientific) (fig. 3).
- After removal of the trocar needle, a biliary balloon dilation catheter (Hurricane™ RX, Boston Scientific) with 40 mm in length and 10 mm of outer diameter was advanced through the stenosis and insufflated.
- After deflation, patency was established between the neopharynx and the cervical oesophagus. An endoprosthesis (WALLSTENT™, Boston Scientific) with 60 mm in length and 10 mm of outer diameter was used to keep the patency of the newly created passage (fig. 4).
- At the end of the intervention, a new button PEG tube was put in place.

No complications were reported and oral intake was reintroduced gradually with normal feeding achieved within weeks. In spite of the initial favourable evolution, 5 months after the procedure the patient presented once again with aphagia and salivary reflux. Due to endoprosthesis migration, the complete PES had recurred. A second CARD was performed and the same type of WALLSTENT™ endoprosthesis was used.

Two months after this second procedure, the patient presented with cervical anterior pain that was attributed to the presence of the metallic endoprosthesis and a third endoscopic intervention was performed to replace it by a plastic oesophageal reconstruction tube (Hood Laboratories®, Pembroke, Mass., USA).

Sixty days after the second intervention, solid dysphagia recurred due to the development of a partial stricture requiring a new dilation and replacement of the plastic oesophageal reconstruction tube for a self-expandable prosthesis (Silmet® 14 mm/40 mm, Novatech SA, France).

Thereafter, the patient required 3 prosthesis replacements due to stenosis, migration and kinking, respectively. Twenty-nine months after the first CARD, the last prosthesis was removed due to good clinical evolution with normal oral intake. During the 26 months of follow-up since then, several dilations due to variable degrees of dysphagia were performed, but no new prosthesis was required and the patient maintains a normal oral intake.

Discussion

The development of radiation-induced complete PES is related to mucositis with subsequent progression to obliterative endarteritis, ischemia and progressive fibrosis. These strictures are usually mucosal and luckily short in length, thereby amenable to puncture. Even though their reported incidence after combined chemoradiation treatment can vary between 4 and 5% [5, 6], the same type of lesion is much less frequent after radiotherapy alone, with an incidence of around 0.8% [7]. Our patient did not receive any chemotherapy treatment, but he presented several risk factors associated with increased risk of developing complete PES, namely high radiation exposure (>60 Gy), radiation site at increased risk of stricture and the presence of a gastrostomy tube.

Following radiotherapy, the timing for the onset of stricture is rather variable from 1 to 26 months, according to different studies, but on average they occur 6 months after the completion of treatment [7–9]. Our patient presented with total aphagia and salivary reflux 8 months after the end of radiotherapy. Nevertheless the initial development of the stricture likely began several weeks or even months before, remaining unnoticed until the stricture had completely blocked the passage between the hypopharynx and the oesophagus. The delayed diagnosis may be explained by other toxicity effects of the radiotherapy like xerostomia and also by the fact that with total circular pharyngolaryngectomy there is no cough reflex and the risk of bronchoaspiration is diminished.

Since its introduction for the treatment of complete PES, rare case series and case reports of the anterograde-retrograde rendezvous technique have been reported [10–16]. Despite some technical variations among groups, the two main advantages of this type of intervention are the following: (1) simultaneous anterograde and retrograde endoscopic guidance (with the aid of transillumination and/or fluoroscopic assistance) diminishes complication risks like perforation and fistula, and (2) smaller mortality and morbidity rates [6] when compared with the surgical alternatives. In our case, transillumination and slight pressure from both ends of the stenosis allowed the safe determination of the adequate site to perform the puncture between the hypopharynx and the oesophagus.

Our case was particularly complex; two CARD procedures were necessary due to recurrence of complete PES after migration of the first endoprosthesis. Furthermore, as described in the report, there were several additional complications associated with the endoprosthesis used: migration, cervical anterior pain, restenosis in spite of the presence of an endoprosthesis, and kinking. To surmount these difficulties, we used different types of prosthesis in order to adapt to each complication and, to the best of our knowledge, this is the first case to report the use of different types of prosthesis in the same patient in this clinical setting.

The anterograde-retrograde rendezvous technique has been shown to respond well to subsequent serial dilatations in case of recurrence without complete stricture [4, 10–12]. Most patients experience some degree of restenosis over time due to the anatomical and mucosal changes caused by surgery, radiotherapy and chemotherapy. Our patient also had several dilation procedures in order to maintain the patency of pharyngo-oesophageal passage.

In conclusion, CARD is a safe and effective technique for the treatment of radiation-induced complete PES, even in complex cases with recurrence of complete PES. Several different types of endoprosthesis can be used safely and effectively to maintain patency. Even though the patient can regain the capacity for a normal oral diet, serial dilations are necessary to maintain it.

Statement of Ethics

Approval from the local Ethics Committee was not required for this case report. The authors have no ethical conflicts to disclose.

Disclosure Statement

The authors have no conflict of interest and no sponsorship or funding arrangements to disclose.

References

- 1 Francis D, Hall E, Dang J, Vlachich G, Nettekville J, Vaezi M: Outcomes of serial dilation for high-grade radiation-related esophageal strictures in head and neck cancer patients. *Laryngoscope* 2014;125:856–862.
- 2 Prisman E, Miles B, Genden E: Prevention and management of treatment-induced pharyngo-oesophageal stricture. *Lancet* 2013;14:380–386.
- 3 Zhou JH, Jiang YG, Wang RW, et al: Management of corrosive esophageal burns in 149 cases. *J Thorac Cardiovasc Surg* 2005;130:449–455.
- 4 van Twisk JJ, Brummer RJ, Manni JJ: Retrograde approach to pharyngo-esophageal obstruction. *Gastrointest Endosc* 1998;48:296–299.
- 5 Lawson JD, Otto K, Grist W, Johnstone PA: Frequency of esophageal stenosis after simultaneous modulated accelerated radiation therapy and chemotherapy for head and neck cancer. *Am J Otolaryngol* 2008;29:13–19.
- 6 Guadagnolo BA, Haddad RI, Posner MR, et al: Organ preservation and treatment toxicity with induction chemotherapy followed by radiation therapy or chemoradiation for advanced laryngeal cancer. *Am J Clin Oncol* 2005;28:371–378.
- 7 Laurell G, Kraepelien T, Mavroidis P, Lind BK, Fernberg JO, Beckman M, et al: Stricture of the proximal esophagus in head and neck carcinoma patients after radiotherapy. *Cancer* 2003;97:1693–700.
- 8 Silvain C, Barrioz T, Besson I, Babin P, Fontanel JP, Daban A, Matuchansky C, Beauchant M: Treatment and long-term outcome of chronic radiation esophagitis after radiation therapy for head and neck tumors. A report of 13 cases. *Dig Dis Sci* 1993;38:927–931.
- 9 Eisbruch A, Lyden T, Bradford CR, Dawson LA, Haxer MJ, Miller AE, et al: Objective assessment of swallowing dysfunction and aspiration after radiation concurrent with chemotherapy for head-and-neck cancer. *Int J Radiat Oncol Biol Phys* 2002;53:23–28.
- 10 Petro M, Wein RO, Minocha A: Treatment of a radiation-induced esophageal web with retrograde esophagoscopy and puncture. *Am J Otolaryngol* 2005;26:353–355.
- 11 Maple JT, Petersen BT, Baron TH, Kasperbauer JL, Wong Kee Song LM, Larson MV: Endoscopic management of radiation-induced complete upper esophageal obstruction with an antegrade-retrograde rendezvous technique. *Gastrointest Endosc* 2006;64:822–828.
- 12 Oxford LE, Ducic Y: Retrograde balloon dilation of complete cervical esophageal and hypopharyngeal strictures. *J Otolaryngol* 2006;35:327–331.
- 13 Bertolini RM: Endoscopic dilation of complete oesophageal obstructions with a combined antegrade-retrograde rendezvous technique. *World J Gastroenterol* 2016;22:2366–2372.
- 14 Al-Haddad M, Pungpapong S, Wallace MB, Raimondo M, Woodward TA: Antegrade and retrograde endoscopic approach in the establishment of a neo-esophagus: a novel technique. *Gastrointest Endosc* 2007;65:290–294.
- 15 Moyer MT, Stack BC, Mathew A: Successful recovery of esophageal patency in 2 patients with complete obstruction by using combined antegrade retrograde dilation procedure, needle knife, and EUS needle. *Gastrointest Endosc* 2006;64:789–792.
- 16 Schembre D, Dever JB, Glenn M, Bayles S, Brandabur J, Kozarek R: Esophageal reconstitution by simultaneous antegrade/retrograde endoscopy: re-establishing patency of the completely obstructed esophagus. *Endoscopy* 2011;43:434–437.

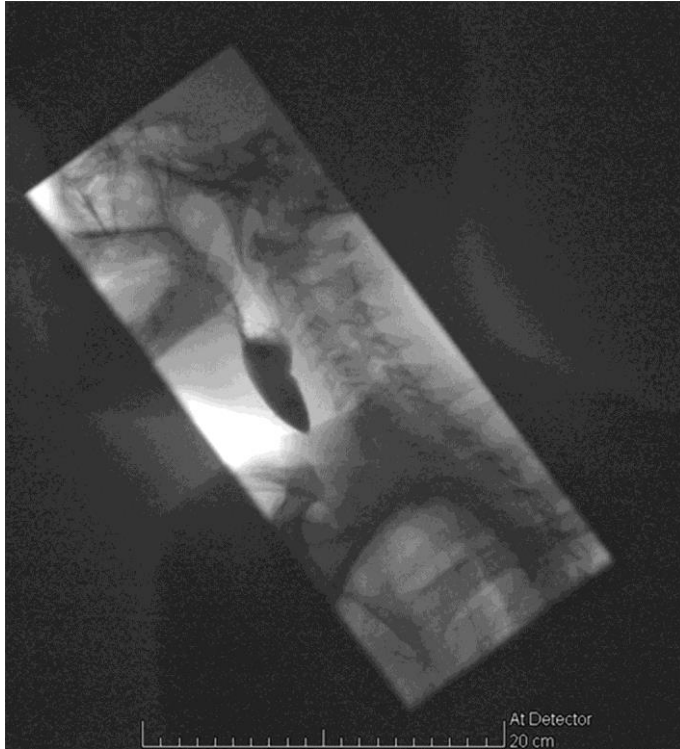

Fig. 1. Videofluoroscopy showing the complete PES.

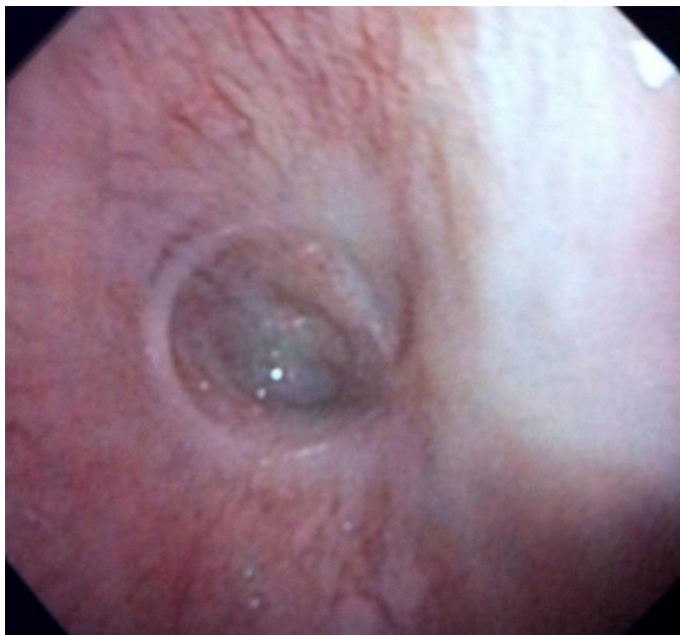

Fig. 2. Endoscopic view of the complete PES.

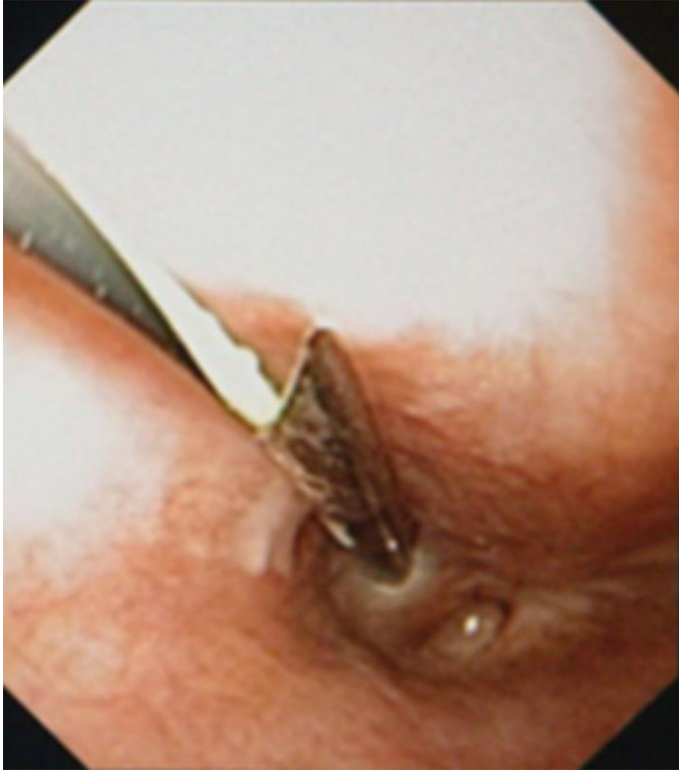


Fig. 3. Advancement of the guide wire through the trocar needle from the pharyngeal side to the upper oesophagus.

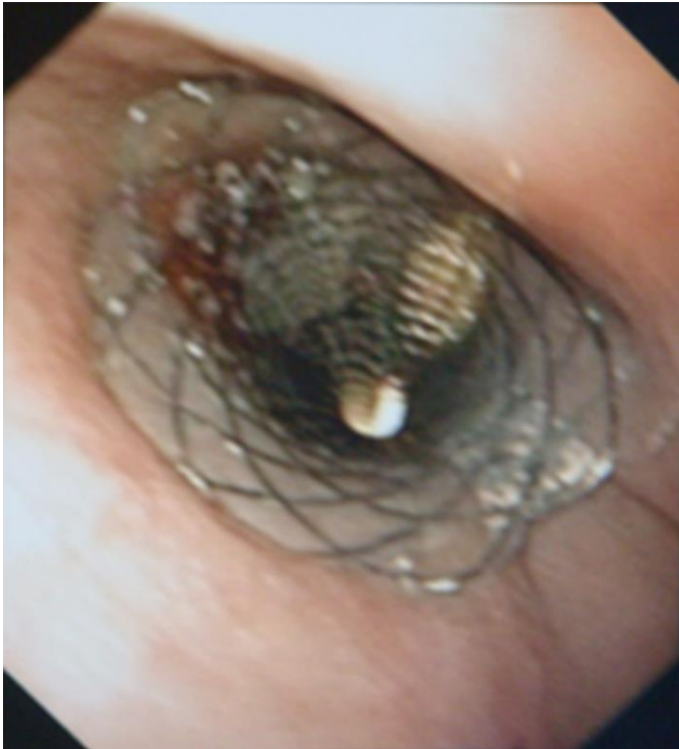


Fig. 4. Endoprosthesis in place after the dilation establishing the patency between the hypopharynx and the upper oesophagus.