

Case Report

Peripheral Retinal Neovascularization with Vitreous Hemorrhage in HIV Retinopathy

Kim Jiramongkolchai Tin Yan Alvin Liu J. Fernando Arevalo

Retina Division, The Wilmer Eye Institute, Johns Hopkins University School of Medicine, Baltimore, MD, USA

Keywords

Peripheral retinal neovascularization · Vitreous hemorrhage · HIV retinopathy

Abstract

We report a case of peripheral retinal neovascularization and vitreous hemorrhage in the setting of HIV retinopathy that can serve to extend the clinical spectrum of this condition. A 53-year-old African-American woman with AIDS was referred for decreased vision in the left eye and was found to have peripheral retinal neovascularization and vitreous hemorrhage. She had a workup that was negative for etiologies of retinal ischemia. Peripheral laser photocoagulation was used to treat areas of nonperfusion. To our knowledge, this is the first reported case of peripheral retinal neovascularization and vitreous hemorrhage in the setting of HIV retinopathy, and it can serve to extend the clinical spectrum of this condition.

© 2017 The Author(s)
Published by S. Karger AG, Basel

Introduction

Retinal macrovasculopathies, such as central retinal vein occlusion, branch retinal vein occlusion, central retinal arterial occlusion, and branch retinal arterial occlusion, have been reported in HIV-infected patients [1]. However, the most common ocular findings in patients

with HIV are noninfectious retinal microvascular abnormalities, which include cotton wool spots, intraretinal hemorrhages, Roth spots, and capillary nonperfusion [2–9].

The objective of this paper is to report a case of peripheral retinal neovascularization and vitreous hemorrhage in the setting of HIV retinopathy, and it can serve to extend the clinical spectrum of this condition.

Case Presentation

A 53-year-old African-American woman with AIDS was referred on the same day by her general ophthalmologist for possible retinitis in the left eye. She was diagnosed with AIDS 8 years prior to presentation, during a hospital admission for shortness of breath, fever, tachycardia, and headache. Her hospital course was complicated by pneumocystis pneumonia, cryptococcal meningitis with increased intracranial pressure, and dermatomal herpes zoster rash. At the time of AIDS diagnosis, her CD4+ count was 11. Her initial fundus exam was significant for diffuse intraretinal hemorrhages and cotton wool spots in both eyes. Fluorescein angiography (FA) showed an enlarged foveal avascular zone in both eyes but no peripheral retinal nonperfusion.

During the 8 years between her initial diagnosis of AIDS and her presentation, her medical history was notable for hospitalizations for acute stroke and pulmonary embolism, for which a hypercoagulability workup was performed. The workup, including protein C, antithrombin III, Factor II 20210 mutation, antiphospholipid antibody panel, and Russell's Viper Venom (RVVT), was normal except for a minimally diminished protein S activity of 55 (normal range 65–140). The etiology of her stroke was thought to be secondary to AIDS vasculopathy or her history of cryptococcal meningitis, which were both associated with an increased risk of strokes.

During her current presentation, her chief complaint was a gradual painless decrease in vision in her left eye of one-week duration. On our examination, her best-correct visual acuity was Snellen 20/20 in her right eye and Snellen 20/40 in her left eye. Intraocular pressures were within normal limits. Pupillary reflexes were normal without a relative afferent pupillary defect. A left homonymous visual field defect, which had been previously documented after her stroke, was noted. Slit-lamp examination was unremarkable. Fundus examination of the right eye was normal. Fundus examination of the left eye showed a pink optic nerve with a cup-to-disc ratio of 0.5, mild vitreous hemorrhage inferiorly, and 2 fibrovascular tufts with overlying preretinal hemorrhage in the inferotemporal peripheral retina. There was no vascular tortuosity or macula edema suggestive of a retinal vein occlusion. There was no peripheral chorioretinal scarring suggestive of previous CMV retinitis. Intraocular inflammation was absent. Ultrawide field FA transiting the left eye showed extensive nonperfusion in the temporal peripheral retina with leakage from retinal neovascularization in the left eye (Fig. 1) and small areas of nonperfusion in the nasal and temporal peripheral retina in the right eye (Fig. 2). A workup for retinal nonperfusion showed a negative sickle cell screen, a negative TB-spot test and a normal CBC, ACE level, PTT, INR, and chest X-ray. Her latest CD4+ count obtained 8 months prior to presentation was 462 and her latest HIV viral load obtained 1 month prior to presentation was <20 copies. Panretinal photocoagulation was applied to the area of nonperfusion in the temporal peripheral retina in the left eye. At her 1-week follow-up, the retinal neovascularization in the left eye had started to regress with decreased leakage on FA (Fig. 3).

Discussion

The differential for peripheral retinal neovascularization is broad and includes proliferative diabetic retinopathy, retinal vein occlusion, sickle cell retinopathy, hyperviscosity syndrome, sarcoidosis, and congenital causes (e.g., retinopathy of prematurity, familial exudative vitreoretinopathy, and incontinentia pigmenti).

Our patient's hypercoagulability workup done 8 years prior to her current presentation was negative. Additional workup for etiologies of retinal ischemia was negative, including hypertension, diabetes, sickle cell, leukemia, sarcoidosis, and tuberculosis. Thus, our patient's peripheral retinal ischemia in both eyes and retinal neovascularization with vitreous hemorrhage in the left eye could be attributed to her AIDS disease, especially given that she previously had documented extensive microvascular damage with intraretinal hemorrhages, cotton wool spots and macular capillary dropout. It is interesting that FA done 8 years prior to her current presentation showed enlarged foveal avascular zone consistent with macular ischemia but no peripheral retinal nonperfusion in either eye. Her current areas of retinal nonperfusion were either present 8 years ago but were not captured by the narrower field of view of older imaging platforms or they have developed over the years from progressive HIV retinopathy.

The exact cause of HIV microvasculopathy is unknown. Previous studies have suggested that immune complex deposition, HIV infection of retinal endothelial cells, or other hematologic factors may lead to HIV microvasculopathy [8, 10], which can in turn lead to focal capillary closure, axoplasmic stasis, and nerve fiber layer ischemia. Therefore, although cotton wool spots and intraretinal hemorrhages are more commonly associated with HIV retinopathy, peripheral retinal ischemia in the setting of HIV/AIDS is certainly possible from a pathophysiology point of view, especially given that macular ischemia is a known entity among HIV/AIDS patients [11–14].

To our knowledge, retinal neovascularization with vitreous hemorrhage in the setting of HIV retinopathy has never been reported before and this can serve to extend the clinical spectrum of HIV retinopathy.

Statement of Ethics

This case report is in compliance with standards on human research.

Disclosure Statement

None of the authors has a proprietary interest or conflicts of interest in the material presented.

References

- 1 Dunn JP, Yamashita A, Kempen JH, Jabs DA: Retinal vascular occlusion in patients infected with human immunodeficiency virus. *Retina* 2005;25:759–766.
- 2 Holland GN, Pepose JS, Pettit TH, Gottlieb MS, Yee RD, Foos RY: Acquired immune deficiency syndrome. Ocular manifestations. *Ophthalmology* 1983;90:859–873.

- 3 Freeman WR, Lerner CW, Mines JA, Lash RS, Nadel AJ, Starr MB, et al: A prospective study of the ophthalmologic findings in the acquired immune deficiency syndrome. *Am J Ophthalmol* 1984;97:133–142.
- 4 Newsome DA, Green WR, Miller ED, Kiessling LA, Morgan B, Jabs DA, et al: Microvascular aspects of acquired immune deficiency syndrome retinopathy. *Am J Ophthalmol* 1984;98:590–601.
- 5 Pepose JS, Holland GN, Nestor MS, Cochran AJ, Foos RY: Acquired immune deficiency syndrome. Pathogenic mechanisms of ocular disease. *Ophthalmology* 1985;92:472–484.
- 6 Freeman WR, Chen A, Henderly DE, Levine AM, Luttrull JK, Urrea PT, et al: Prevalence and significance of acquired immunodeficiency syndrome-related retinal microvasculopathy. *Am J Ophthalmol* 1989;107:229–235.
- 7 Jabs DA, Green WR, Fox R, Polk BF, Bartlett JG: Ocular manifestations of acquired immune deficiency syndrome. *Ophthalmology* 1989;96:1092–1099.
- 8 Engstrom RE Jr, Holland GN, Hardy WD, Meiselman HJ: Hemorheologic abnormalities in patients with human immunodeficiency virus infection and ophthalmic microvasculopathy. *Am J Ophthalmol* 1990;109:153–161.
- 9 Jabs DA: Ocular manifestations of HIV infection. *Trans Am Ophthalmol Soc* 1995;93:623–683.
- 10 Pomerantz RJ, Kuritzkes DR, de la Monte SM, Rota TR, Baker AS, Albert D, et al: Infection of the retina by human immunodeficiency virus type I. *N Engl J Med* 1987;317:1643–1647.
- 11 Akduman L, Feiner MA, Olk RJ, Kaplan HJ: Macular ischemia as a cause of decreased vision in a patient with acquired immunodeficiency syndrome. *Am J Ophthalmol* 1997;124:699–702.
- 12 Cunningham ET Jr, Levinson RD, Jampol LM, Engstrom RE Jr, Lewis H, Holland GN: Ischemic maculopathy in patients with acquired immunodeficiency syndrome. *Am J Ophthalmol* 2001;132:727–733.
- 13 Romano MR, Valldeperas X, Romano F: Bilateral ischemic maculopathy in a patient with AIDS. *Eur J Ophthalmol* 2006;16:761–763.
- 14 Turaka K, Reddy R, Golshani A, Khaw WY, Bryan JS: Bilateral ischemic maculopathy in acquired immune deficiency syndrome. *J Ophthalmic Inflamm Infect* 2013;3:15.

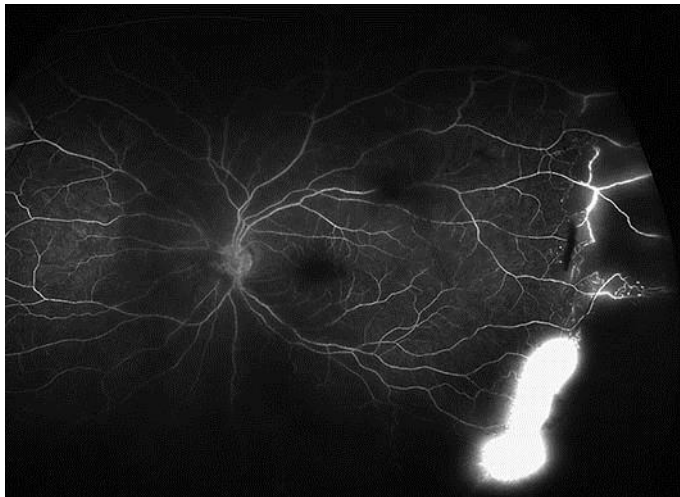


Fig. 1. Ultraslow field FA of the left eye showing extensive nonperfusion in the temporal peripheral retina with intense leakage from retinal neovascularization. FA, fluorescein angiography.

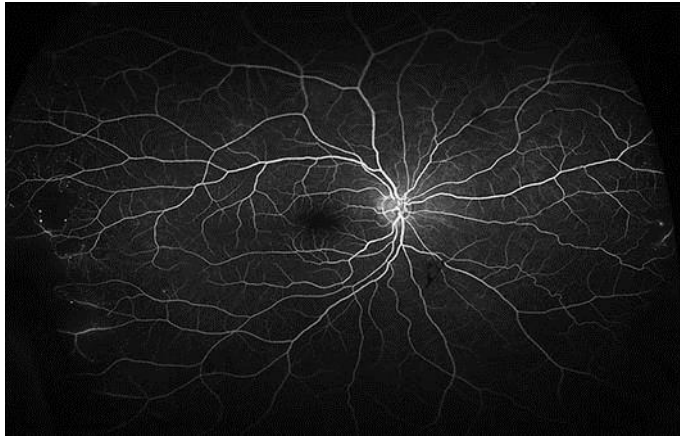


Fig. 2. Ultrawide field FA of the right eye showing microaneurysms and areas of nonperfusion in the far peripheral nasal and temporal retina. No leakage indicative of retinal neovascularization was seen. FA, fluorescein angiography.

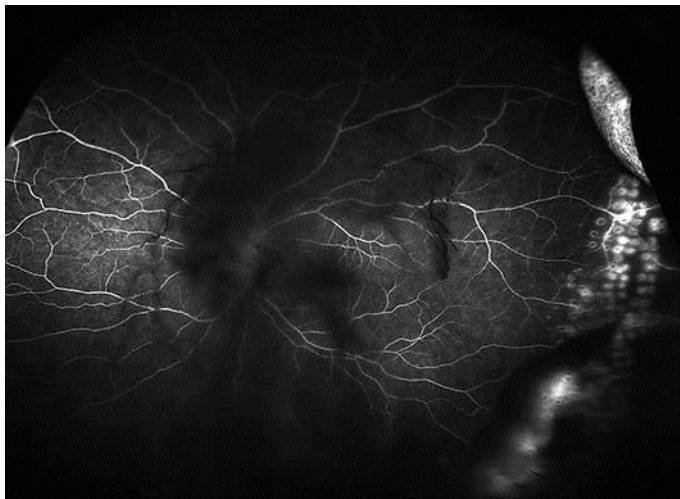


Fig. 3. Ultrawide field FA of the left eye obtained 1 week after treatment with regional panretinal photocoagulation showing staining of the new laser scars and marked decrease in leakage from retinal neovascularization. FA, fluorescein angiography.