

Myeloid Sarcoma in an Eyelid That Developed during Chemotherapy for Acute Myeloid Leukemia

Hyera Kang^{a, c} Yasuhiro Takahashi^a Emiko Takahashi^b
Hirohiko Kakizaki^a

^aDepartment of Ophthalmology, Aichi Medical University, and ^bDepartment of Pathology, Aichi Medical University Hospital, Nagakute, Japan; ^cDepartment of Ophthalmology, University of Seonam College of Medicine, Presbyterian Medical Center, Jeonju, Korea

Key Words

Myeloid sarcoma · Acute myeloid leukemia · Chemotherapy

Abstract

An 80-year-old female presented with a mass in the left upper eyelid margin that had developed during chemotherapy for acute myeloid leukemia. The mass was elastic, hard, and pinkish, with a relatively smooth surface but without madarosis. The histopathological findings corresponded to a myeloid sarcoma. No blast cells were shown in the peripheral blood at the time of biopsy, and she subsequently underwent an azacitidine injection regimen. The size of the eyelid tumor decreased 3 months after the biopsy, when the course of azacitidine injections was completed. However, acute myeloid leukemia recurred, and the patient died 5 months after her first examination.

© 2016 The Author(s)
Published by S. Karger AG, Basel

Introduction

Myeloid sarcoma is a rare extramedullary manifestation of leukemia that consists of immature cells of the granulocytic series [1]. Although myeloid sarcoma can involve any ocular tissue, a myeloid sarcoma in the eyelid is less common [2, 3]. Ocular myeloid sarcomas may appear at any time during the course of acute myeloid leukemia [3, 4], and they often develop simultaneously with acute myeloid leukemia during onset or relapse [1, 4]. In contrast, an ocular myeloid sarcoma that develops during chemotherapy is extremely rare, with only one reported case with an intraocular lesion [5].

In this case report, we present a case of a myeloid sarcoma in the upper eyelid that developed during chemotherapy for acute myeloid leukemia.

KARGER

Hirohiko Kakizaki
Department of Ophthalmology, Aichi Medical University
1-1, Yazakokarimata
Nagakute, Aichi 480-1195 (Japan)
E-Mail cosme@d1.dion.ne.jp

Case Report

The Institutional Review Board (IRB) of the Ethics Committee of Aichi Medical University approved this retrospective case report (2015-012), which adhered to the tenets of the 1964 Declaration of Helsinki. As the IRB requested us to obtain informed consent from the patient or a patient's kin before the collection of data for this retrospective case report, informed consent was obtained from the brother due to the patient's death. Informed consent was also obtained from the brother for the publication of this case report and any accompanying images.

An 80-year-old female was diagnosed with myelodysplastic syndrome 1 year before referral to our clinic. She underwent erythrocyte transfusion therapy for severe anemia. As the myelodysplastic syndrome progressed to acute myeloid leukemia 3 months after the initial diagnosis, she was administered two cycles of low-dose cytarabine (20 mg/m²/day) and aclarubicin hydrochloride (14 mg/m²/day) chemotherapy [6], followed by azacitidine injections (1 cycle, 75 mg/m²/day × 7 days). As the patient showed a hypocellular marrow, cytarabine and aclarubicin hydrochloride were administered for 5 (recommended medication days, 14 days) and 3 days (recommended medication days, 4 days), respectively, in each cycle of the chemotherapy for preventing a delayed recovery of a normal blood count after the chemotherapy. The interval between the cycles was approximately 4 weeks. As acute myeloid leukemia recurred immediately after the fourth cycle of the azacitidine injections, cytarabine (1 cycle, 20 mg/m²/day × 10 days), aclarubicin hydrochloride (1 cycle, 14 mg/m²/day × 3 days), and granulocyte colony-stimulating factor (granisetron hydrochloride; 1 cycle, 200 µg/m²/day × 10 days) (CAG) chemotherapy was started [6]. Between the second and third cycles of CAG chemotherapy, the patient noticed an eyelid mass with the size decreasing during the 3 cycles of CAG chemotherapy.

Upon the first examination after the 3 cycles of the CAG chemotherapy, an elastic, hard, pinkish, relatively smooth surface mass was observed in the left upper eyelid margin without madarosis (fig. 1). Systemic computed tomography did not reveal any other lesions. We then performed a biopsy under local anesthesia. The pathological examination revealed a proliferation and an infiltration of tumor cells, with a high nuclear/cytoplasmic ratio (fig. 2). Apoptosis and mitosis were observed in the lesion. Immunostaining was positive for cluster of differentiation (CD) 68 and CD117, but negative for CD34, terminal deoxynucleotidyl transferase, cytokeratin (AE1/AE3), and cytokeratin-20. The pathological diagnosis was myeloid sarcoma.

Due to the poor systemic condition of the patient and since no blast cells were shown in the peripheral blood at the time of the biopsy, she subsequently received azacitidine injections without an additional cycle of CAG chemotherapy. The residual eyelid tumor decreased in size at 3 months following the biopsy, when the course of the azacitidine injections was completed. However, acute myeloid leukemia recurred, and she died 5 months after her first examination.

Discussion

This is the first reported case of an eyelid myeloid sarcoma that developed during chemotherapy for acute myeloid leukemia. Although no blast cells were shown in the peripheral blood at the time of the biopsy, acute myeloid leukemia recurred, and the patient died. An eyelid myeloid sarcoma may be a sign of an incomplete remission of acute myeloid leukemia despite effective chemotherapy and poor prognosis [4].

The patient suffered from myelodysplastic syndrome before the onset of acute myeloid leukemia, which is one of the risk factors for developing acute myeloid leukemia. In cases with preexisting myelodysplastic syndrome, chemotherapy tends to be less effective for acute myeloid leukemia [7], possibly resulting in the development of an eyelid myeloid sarcoma, as it occurred in this patient.

The mass was elastic, hard, and pinkish, with a relatively smooth surface, but without madarosis. This appearance was different from other eyelid myeloid sarcomas described in previous reports that showed multiple erythematous lesions of varying sizes [8, 9]. In contrast, it was similar in appearance to malignant lymphomas [10] and Merkel cell carcinomas [11]. It may be difficult to diagnose similar masses that develop before the onset of acute myeloid leukemia [3, 10], although the patient described in this case report had a history of acute myeloid leukemia. Ophthalmologists and pathologists, therefore, need to know the variations in the appearance of eyelid myeloid sarcomas.

In conclusion, we report the first case of an eyelid myeloid sarcoma that developed during chemotherapy for acute myeloid leukemia. An eyelid myeloid sarcoma may be a sign of incomplete remission of acute myeloid leukemia during effective chemotherapy and poor prognosis.

Acknowledgements

The authors wish to acknowledge Dr. Shohei Mizuno from the Division of Hematology, Department of Internal Medicine, Aichi Medical University, for his advice on the hematological data.

Statement of Ethics

The Institutional Review Board (IRB) of the Ethics Committee of Aichi Medical University approved this retrospective case report (2015-012), which adhered to the tenets of the 1964 Declaration of Helsinki. As the IRB requested us to obtain informed consent from the patient or a patient's kin before the collection of data for this retrospective case report, informed consent was obtained from the brother due to the patient's death. Informed consent was also obtained from the brother for the publication of this case report and any accompanying images.

Disclosure Statement

The authors have no competing interests to declare.

References

- 1 Yilmaz AF, Saydam G, Sahin F, Baran Y: Granulocytic sarcoma: a systematic review. *Am J Blood Res* 2013;3:265–270.
- 2 Sharma T, Grewal J, Gupta S, Murray PI: Ophthalmic manifestations of acute leukemias: the ophthalmologist's role. *Eye* 2004;18:663–672.
- 3 Zimmerman LE, Font RL: Ophthalmologic manifestations of granulocytic sarcoma (myeloid sarcoma or chloroma). *Am J Ophthalmol* 1975;80:975–990.

Kang et al.: Myeloid Sarcoma in an Eyelid That Developed during Chemotherapy for Acute Myeloid Leukemia

- 4 Ohanian M, Borthakur G, Quintas-Cardama A, Mathisen M, Cortés JE, Estrov Z, Pemmaraju N: Ocular granulocytic sarcoma: a case report and literature review of ocular extra-medullary acute myeloid leukemia. *Clin Lymphoma Myeloma Leuk* 2013;13:93–96.
- 5 Rootman J, Gudauskas G: Treatment of ocular leukemia with local chemotherapy. *Cancer Treat Rep* 1985;69:119–122.
- 6 Yamada K, Furusawa S, Saito K, Waga K, Koike T, Arimura H, Aoyagi A, Yamato H, Sakuma H, Tsunogake S: Concurrent use of granulocyte colony-stimulating factor with low-dose cytosine arabinoside and aclarubicin for previously treated acute myelogenous leukemia: a pilot study. *Leukemia* 1995;9:10–14.
- 7 Liapis K, Cavenagh JD: Toward a better management of older patients with acute myeloid leukemia. *Future Oncol* 2015;11:715–718.
- 8 Thomas SA, Durairaj VD: Isolated myeloid sarcoma presenting in all four eyelids. *Ophthal Plast Reconstr Surg* 2007;23:336–338.
- 9 Yaghouti F, Nouri M, Mannor GE: Ocular adnexal granulocytic sarcoma as the first of acute myelogenous leukemia relapse. *Am J Ophthalmol* 1999;127:361–363.
- 10 van Veen S, Kluin PM, de Keizer RJW, Kluin-Nelemans HC: Granulocytic sarcoma (chloroma): presentation of an unusual case. *Am J Clin Pathol* 1991;95:567–571.
- 11 Sinclair N, Mireskandari K, Forbes J, Crow J: Merkel cell carcinoma of the eyelid in association with chronic lymphocytic leukemia. *Br J Ophthalmol* 2003;87:240.

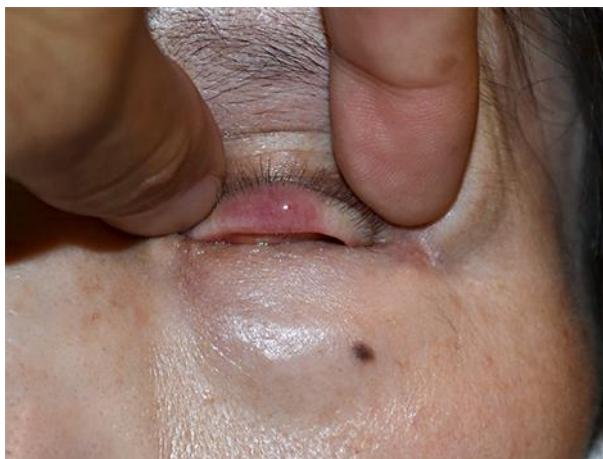

Fig. 1. Photograph of the patient's face. A mass is located in the upper eyelid margin without evidence of madarosis. The mass is pinkish with a relatively smooth surface.

Kang et al.: Myeloid Sarcoma in an Eyelid That Developed during Chemotherapy for Acute Myeloid Leukemia

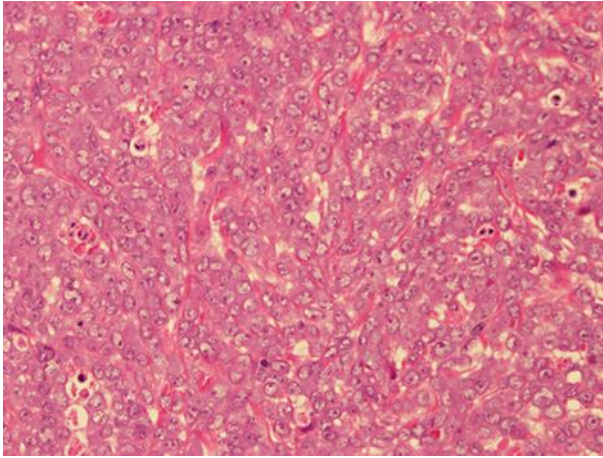


Fig. 2. Pathological finding. The biopsy sample shows proliferation and infiltration of tumor cells with a high nuclear/cytoplasmic ratio. HE. ×400.