

Isolated Optic Disc Tuberculosis

Ahmad M. Mansour^{a, c} Khalid F. Tabbara^{e–g} Zuhair Tabbarah^{b, d}

^aDepartment of Ophthalmology, and ^bDepartment of Internal Medicine, Infectious Disease Service, American University of Beirut, and Departments of ^cOphthalmology and ^dInternal Medicine, Rafic Hariri University Hospital, Beirut, Lebanon; ^eThe Eye Center and the Eye Foundation for Research in Ophthalmology, and ^fDepartment of Ophthalmology, College of Medicine, King Saud University, Riyadh, Saudi Arabia; ^gThe Wilmer Ophthalmological Institute of the Johns Hopkins University School of Medicine, Baltimore, Md., USA

Key Words

Optic neuropathy · Ocular tuberculosis · Systemic tuberculosis · Immunocompetence

Abstract

We present a healthy male subject who developed progressive visual loss in the left eye initially diagnosed as optic neuritis. Upon suspicion of infectious etiology, testing was positive for tuberculosis. There were no signs or symptoms of active systemic tuberculosis infection. The patient responded swiftly to antimycobacterial therapy with return of vision and resolution of disc swelling. Positive purified protein derivative skin test, negative chest radiograph, negative systemic workup, negative workup for other causes of unilateral optic neuritis and quick response to mycobacterial therapy reaffirm the entity of isolated optic disc tuberculosis similar to isolated choroidal tuberculosis without systemic manifestation. © 2015 S. Karger AG, Basel

Case Report

This 34-year-old man had progressive visual loss in the left eye of 2 months. He was diagnosed with left optic neuritis, and systemic corticosteroids were prescribed. Magnetic resonance imaging of the brain was normal. Automated visual fields were symmetrically normal. After seeking a second opinion 14 days later, best-corrected visual acuity (BCVA) of the left eye was 20/100 (6/30) with diffuse disc elevation and peripapillary nerve fiber hemorrhage (fig. 1a). There was absence of anterior chamber or vitreous flare and cells. He had no afferent pupillary defect and no red color desaturation. He had fluorescein dye leakage from the optic disc (fig. 2a). There was no evidence of retinal vasculitis. Optical coherence tomography (OCT) demonstrated optic nerve head swelling and thickening (fig. 3a).

Visual acuity was normal in the right eye with negative findings by 90-diopter slit-lamp exam, visual acuity, OCT, and fluorescein angiography. Detailed medical history was positive for a cough productive of clear sputum of recent duration, nonsmoking status, no exposure to cats, no ingestion of raw meat, and no extramarital relations. Tuberculosis was suspected. Physical exam and infectious workup were essentially negative (HIV, VDRL, *Borrelia burgdorferi*, *Brucella*, angiotensin-converting enzyme) including chest radiograph and chest CT. Purified protein derivative (PPD) skin test was strongly positive. Ten days after the initial consult, BCVA deteriorated further to 20/200 (6/60) in the left eye with increased disc swelling. He was started on treatment for presumed optic disc tuberculoma consisting of 2 months of rifampin, isoniazid, pyrazinamide, and ethambutol (respective doses: 150, 75, 400, and 275 mg) followed by 4 months of rifampin and isoniazid. One week after initiation of quadruple antituberculous therapy, vision improved to 20/30 (6/9) with decreased disc swelling. BCVA in the left eye was 20/20 (6/6) 2 weeks after initiation of therapy with a marked decrease in both disc elevation (fig. 1b) and fluorescein leakage (fig. 2b). Three months after initiation of therapy, funduscopy and OCT (fig. 3b) returned to normal. At follow-up 4 months after initiation of therapy, visual fields were unchanged. At the last follow-up 10 months after initiation of therapy, clinical examination was unchanged.

Discussion

Optic nerve tuberculomas are rarely reported [1–6], and their natural history, prognosis, and duration of required treatment remain unclear. Davis et al. [1] gathered a large series of optic disc tuberculosis in order to delineate the progress of the disease and propose the most authoritative therapeutic regimen.

In this analysis of 62 eyes from 49 patients with tuberculous optic neuropathy, papillitis was present in 51.6%, neuroretinitis in 14.5%, and optic nerve tubercle in 11.3%, with uveitis absent in 11.3% and extraocular tuberculosis absent in 63.3% of patients [1]. In our case, antituberculosis therapy was initiated, based on clinical evidence. The ocular findings improved remarkably with the antituberculosis treatment. An index of suspicion is required to diagnose ocular tuberculosis when all other systemic investigations are negative, especially in this part of the world where tuberculosis is endemic.

Isolated optic disc tuberculosis [1–6], similar to isolated choroidal [7] or ciliary body [8] tuberculosis, can be the presenting form of tuberculosis in immunocompetent subjects without extraocular clinical signs or symptoms. Tuberculosis should be considered in the diagnosis of papillitis, even in asymptomatic patients. Positive PPD skin test and rapid response to antimycobacterial therapy confirm the clinical diagnosis of presumed ocular tuberculosis [9].

Statement of Ethics

The authors have no ethical conflicts to disclose.

Disclosure Statement

The authors report no conflict of interests and did not receive funding support. Ahmad M. Mansour is a consultant for Bayer.

References

- 1 Davis EJ, Rathinam SR, Okada AA, Tow SL, Petrushkin H, Graham EM, Chee S-P, Guex-Crosier Y, Jakob E, Tugal-Tutkun I, Cunningham ET Jr, Leavitt JA, Mansour AM, Winthrop KL, Hills WL, Smith JR: Clinical spectrum of tuberculous optic neuropathy. *J Ophthalmic Inflamm Infect* 2012;2:183–189.
- 2 Wan Hazabbah WH, Rohaizan Y, Shatriah I: Isolated optic neuritis secondary to presumed tuberculosis in an immunocompetent child. *Med J Malaysia* 2012;67:102–104.
- 3 Mansour AM: Optic disc tubercle. *J Neuroophthalmol* 1998;18:201–203.
- 4 Ooi YL, Tai LY, Subrayan V, Tajunisah I: Combined optic neuropathy and central retinal artery occlusion in presumed ocular tuberculosis without detectable systemic infection. *Ocul Immunol Inflamm* 2011;19:370–372.
- 5 Asensio-Sánchez VM, Torreblanca-Agüera B, Martínez-Calvo S, Calvo MJ, Rodríguez R: Tuberculous papillitis (in Spanish). *Arch Soc Esp Ophthalmol* 2006;81:37–39.
- 6 Shetty SB, Bawtag MA, Biswas J: A case of subretinal tubercular abscess presenting as disc edema. *Indian J Ophthalmol* 2015;63:164–166.
- 7 Mansour AM, Haymond R: Choroidal tuberculomas without evidence of extraocular tuberculosis. *Graefes Arch Clin Exp Ophthalmol* 1990;228:382–383.
- 8 Al-Fraikh H, Al-Dahmash S: Rare presentation of definitive ocular tuberculosis in an immunocompetent young patient. *Saudi J Ophthalmol* 2010;24:31–33.
- 9 Bodaghi B, LeHoang P: Ocular tuberculosis. *Curr Opin Ophthalmol* 2000;11:443–448.

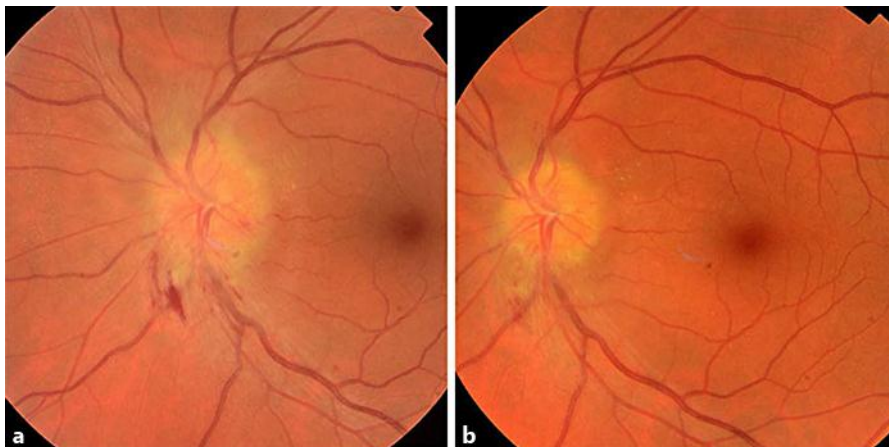

Fig. 1. **a** Fundus photograph. Posterior pole of the left eye demonstrates marked swelling of the optic disc with peripapillary hemorrhage. **b** Fundus photograph. Posterior pole of the left eye 2 weeks after initiation of antimycobacterial therapy shows marked resolution of the optic disc swelling.

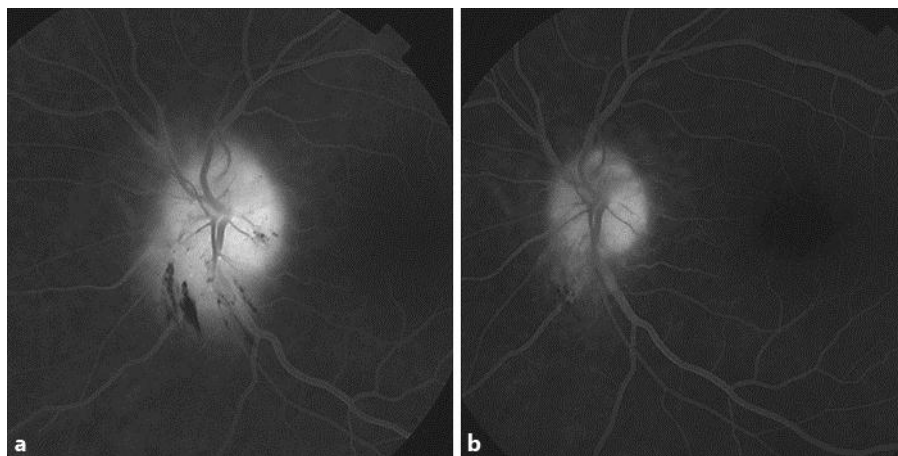


Fig. 2. **a** Intravenous fluorescein angiography (6 min 21 s after dye injection). The left optic disc shows profuse leakage well at the venous phase transit. **b** Intravenous fluorescein angiography (8 min after dye injection). The left disc shows minimal leakage at the venous phase transit 2 weeks after initiation of therapy.

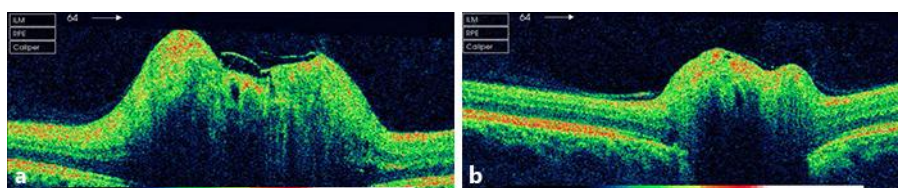


Fig. 3. **a** OCT. Horizontal scan through the center of the left optic disc shows marked swelling of optic nerve head. **b** OCT. Horizontal scan through the center of the left optic disc 3 months after initiation of therapy. The left disc swelling has resolved.