

This is an Open Access article licensed under the terms of the Creative Commons Attribution-NonCommercial-NoDerivs 3.0 License (www.karger.com/OA-license), applicable to the online version of the article only. Distribution for non-commercial purposes only.

Bilateral Implantation of Scleral-Fixated Cionni Endocapsular Rings and Toric Intraocular Lenses in a Pediatric Patient with Marfan's Syndrome

Howard V. Gimbel^{a, b} Gerardo D. Camoriano^a
Muhammad Aman-Ullah^a

^aGimbel Eye Centre, Calgary, Alta., Canada; ^bLoma Linda University, Loma Linda, Calif., USA

Key Words

Ectopia lentis · Marfan's syndrome · Toric intraocular lens · Cionni endocapsular ring

Abstract

The management of ectopia lentis in Marfan's syndrome is challenging. Multiple disease-associated factors conspire to deprive these patients of adequate vision. While optical correction with glasses and contact lenses is usually advocated early on, the irregular astigmatism and even partial aphakia that accompanies advanced cases generally warrant surgical intervention. Several surgical strategies have been devised to manage these challenging cases, including the combination of endocapsular or pars plana lensectomy and iris or scleral fixation of the intraocular lens (IOL) or IOL-bag complex. All of the reported cases have been implanted with IOLs that correct for myopia only. With toric lenses, it is now possible to correct for corneal astigmatism in these patients as well, provided that the capsular bag is maintained and can be properly centered. We report the combination of scleral-fixated Cionni endocapsular rings and toric IOLs in a pediatric patient with bilateral ectopia lentis secondary to Marfan's syndrome.

Introduction

The management of lens subluxation in Marfan's syndrome is complex. The same fibrillin gene defect that weakens the zonules also predisposes patients to high myopia and retinal pathology, including atrophic holes, pre- and post-equatorial breaks, giant

retinal tears, and rhegmatogenous retinal detachments [1]. In addition, when present in young children, ectopia lentis may result in bilateral functional ametropic amblyopia that is typically worse when the edge of the crystalline lens is within 1.3 mm of the visual axis [2]. While optical correction with glasses and contact lenses is usually advocated early on, the irregular astigmatism and even aphakia that accompanies advanced cases generally warrant surgical intervention [3]. Several surgical strategies have been devised to treat these challenging pediatric cases, including the combination of endocapsular or pars-plana lensectomy and iris or scleral fixation of the intraocular lens (IOL) or IOL-bag complex [4, 6]. All of these cases have been implanted with lenses that correct for myopia only. With the advent of spherocylindrical toric lenses, it is now possible to correct for corneal astigmatism in these patients as well, provided that the capsular bag is maintained and properly centered. To our knowledge, this is the first use of toric IOLs along with scleral fixation of the capsular bags using Cionni capsular tension rings (CTR) in a pediatric patient with Marfan's syndrome and bilateral ectopia lentis.

Case Report

A 16-year-old girl with Marfan's syndrome presented with a 6-month history of worsening binocular vertical diplopia and blurred vision in the right eye. Prior to this, she had been able to fuse with a myopic astigmatic correction and a 12 base-up prism in the right eye. In the past, she was not able to tolerate contact lenses due to dryness in both eyes. Over time, her prescription had become progressively more myopic, and she reported increasing difficulty reading with her glasses, implying a loss of accommodation and binocular fusion. Preoperative clinical data are shown in [table 1](#). On slit-lamp examination, superior lens subluxation was noted in both eyes, being more prominent in the right eye ([fig. 1](#)). In light of her poor vision and corneal astigmatism, the patient was offered refractive lens exchange with a toric IOL and scleral fixation of the capsular bag with a Cionni CTR in the right eye. Informed consent was obtained from both the patient and her parents. More specifically, the novelty of this surgical strategy in Marfan's syndrome patients and its lack of long-term outcome data were extensively discussed with the family. The target postoperative refraction was set at -1.25 sphere in the non-dominant right eye to minimize postoperative aniseikonia and provide the option of monovision in the future.

In December 2008, surgery was performed on the right eye. Preoperative astigmatism reference marks at the slit lamp were made at the limbus ([fig. 2](#)). After a retrobulbar block, preparation and draping were performed in the usual, sterile manner. A 6-0 silk superior rectus traction suture was placed for better exposure. Limbal paracenteses were made at 2, 4, and 8 o'clock, and preservative-free phenylephrine (2.5% in 1:4 solution) was instilled. After instillation of Healon5 (Advanced Medical Optics), a superior 3-mm fornix-based conjunctival flap and a Hoffman scleral pocket were made 2 mm posterior to the limbus in the meridian of greatest zonular separation. A continuous curvilinear capsulorhexis was performed with Utrata forceps. A Grieshaber iris hook was placed at 8 o'clock to engage the margin of the capsulorhexis to be able to achieve a central opening. The hook was left in place to stabilize the lens during hydrodissection and phacoemulsification/aspiration of the lens nucleus. The residual cortical material was removed by aspiration. Next, a Morcher 1L Cionni CTR (FCI Ophthalmics), with a preloaded double-armed 9-0 prolene suture, was inserted into the capsular bag. The two needles of the 9-0 prolene suture were passed through the pocket of the inferior Hoffman tunnel incision, looped out, and temporarily tied. The iris hooks were removed, and a 20.5 D^{+2.25 cyl} AcrySof® SN60T4 IOL (Alcon) was inserted in the bag and rotated to align it with the steep axis of corneal astigmatism (107 degrees). Acetylcholine chloride (Miochol) was then instilled, followed by irrigation of all viscoelastic material out of the anterior chamber. A small bolus of vancomycin (1 mg in 0.1 ml of balanced salt solution) was given behind the IOL in the capsular bag. When proper centration and orientation of the IOL were confirmed, the prolene suture was tied in a square knot and trimmed. The knot was then buried within the scleral tunnel. All corneal incisions were hydrated, and the conjunctiva over the superior incision was closed with two wing 10-0 vicryl sutures. The superior traction suture was removed, a drop of apraclonidine (Iopidine) 0.5% (Alcon)

and tobramycin 0.3%/dexamethasone 0.1% (Tobradex) ointment (Alcon) were applied, and the eye was patched. The patient tolerated the procedure well, and there were no intraoperative or postoperative complications. The surgical procedure may be viewed on <http://www.youtube.com/watch?v=40FpDHLLY2A>.

Given that the vertical diplopia persisted after the surgery, the patient was offered multiple spectacle prescriptions with vertical prism to help her fuse. She was also seen by a pediatric ophthalmologist, who diagnosed a left superior oblique palsy and performed a left inferior oblique recession. Although this surgery initially afforded some relief, the diplopia gradually relapsed. When she visited our clinic during her follow-up, it was decided to address the lens subluxation in the left eye, using the same technique as in the right eye, in hopes of also helping her diplopia. Informed consent was once again obtained from the patient and her parents. The postoperative target refraction for this eye was set at plano.

In April 2010, surgery was performed on the left eye. A similar procedure to that in the right eye was followed, with a few modifications. Briefly, paracenteses were made at 2, 3, and 4 o'clock. The fornix-based conjunctival flap and Hoffman scleral pocket were constructed inferiorly at 5 o'clock. Phacoemulsification of the crystalline lens was carried out mostly in the aspiration setting. The Morcher L1 Cionni CTR was anchored to the Hoffman scleral pocket using the same technique as in the right eye. A 21.5 D^{+2.25 cyl} AcrySof SN60T4 IOL (Alcon) was inserted in the capsular bag and oriented at 86 degrees. At the end of the surgery, the lens appeared well centered and stable. There were no intraoperative or postoperative complications, and the toric IOL with the scleral-sutured Cionni CTR remained stable. The patient was referred back by her optometrist at 32 months after surgery in the right eye for posterior capsular opacification, with complaints of hazy vision and glare at night. YAG laser capsulotomy was performed to create a central posterior capsular opening. The YAG laser opening was further extended after 1 month to improve her night vision. The capsular bags with the toric IOLs and Cionni CTRs have remained stable postoperatively in the right eye at the last examination at 34 months and at 18 months in the left eye ([fig. 3](#)). The latest postoperative results are shown in [table 2](#). At her most recent postoperative visit, the patient had no complaints of diplopia and is happy with her uncorrected distance vision. She remains spectacle-free for most of her activities of daily living with her current monovision.

Discussion

This case of bilateral lens subluxation in a pediatric patient with Marfan's syndrome illustrates the challenges associated with the management of these patients. Our strategy of correcting corneal astigmatism and capsular bag subluxation in the same surgery raises 4 theoretical concerns in this patient population: the corneal astigmatism may continue to change with age, the toric IOL may shift within the capsular bag leading to an unpredictable refractive change, the remaining zonules may weaken in the future leading to subluxation of the bag-toric IOL complex with concomitant worsening of the astigmatism, and the risk of retinal detachment after lens extraction with scleral fixation of the CTR.

Although corneal histopathological studies of patients with Marfan's syndrome have demonstrated significant abnormalities leading to flattening and corneal astigmatism, the lenticular and retinal changes appear to dominate the clinical picture [7]. In terms of the change in corneal astigmatism with age, pediatric studies have revealed that most of the change in corneal astigmatism occurs between birth and the age of 2 years. After this, the astigmatism tends to decrease by ages 4–6 years, essentially stabilizing in adolescence [8]. While these results do not necessarily apply to Marfan's syndrome patients, they do provide a starting point for the discussion. In addition, studies have shown that part of the cause for myopia progression in Marfan's syndrome is due to the increased curvature effect of the lens subluxation. Hence, if corrected at an early age, it

is not only possible to treat the ametropic amblyopia, but also to prevent worsening of the myopia and its associated complications [2]. While a similar teleological, corneal remodeling mechanism to counter long-standing lenticular astigmatism can be proposed in these patients, this has yet to be determined. In light of the stability in corneal astigmatism of older children and adolescent patients, with no published evidence to the contrary in Marfan's syndrome patients, it is not unreasonable to correct corneal astigmatism with toric lenses in highly motivated young patients. Other treatment modalities to treat the progressive refractive error/astigmatism after toric lens implantation in such patients can be also used, e.g. laser refractive surgery and corneal astigmatic surgery.

More data are becoming available regarding the long-term rotational stability of toric IOLs [9–11]. The main requirements for implantation of these lenses are the presence of regular corneal astigmatism and an integral, well-centered, and stable capsular bag. Given that the integrity of the capsular bag in Marfan's syndrome patients has been proven in multiple cases of endocapsular IOL implantation, there is no reason to believe that a toric IOL should behave any differently in these patients compared to others without the disease. In our patient, the toric IOL remained stable within the capsular bag for 34 months after surgery in the right eye.

The long-term stability of the bag-toric IOL complex in these patients is also a concern, and there is a potential of worsening astigmatism if further subluxation ensues. Several case reports of ectopia lentis managed with scleral-fixated Cionni CTRs have demonstrated excellent short-term results [12, 13]. More recently, a case series validated the safety and effectiveness of this technique in 15 adult eyes with Marfan's syndrome. These patients all achieved an uncorrected visual acuity better than 20/40 at a mean follow-up of 14 months, with the main complication reported being posterior capsule opacification [14]. In the potentially rare incidence of bag-IOL complex dislocation, we have also described the technique of scleral fixation of the subluxated IOL-bag complex through a fibrotic continuous curvilinear capsulorhexis with 3-point fixation to achieve a good centration [15].

Retinal detachment in Marfan's syndrome is multifactorial and related to axial myopia and lens subluxation. The rate of vitreous loss is higher in techniques employing complete lensectomy in these eyes with higher risk of retinal detachment. With our technique of preserving the capsular bag and maintaining the physical barrier to an anterior vitreous prolapse, the risk of subsequent retinal detachment should be much lower. The published results of successful retinal detachment surgery in Marfan's syndrome eyes are comparable to those in patients without the disease [1].

Our patient achieved an excellent refractive result in both eyes, but in the early postoperative period after the right eye surgery, she experienced recurrence in binocular vertical diplopia despite properly centered IOL and strabismus surgery. The patient could not tolerate myopic contact lens in the left eye, and the diplopia persisted. The diplopia improved gradually over a period of 6 months following the left eye surgery. This could be related to an improvement in her binocular fusion with better control of her ocular alignment without the subluxated crystalline lens.

In conclusion, we report the case of a pediatric patient with Marfan's syndrome and bilateral ectopia lentis who derived benefit from lens removal, implantation of scleral-

sutured Cianni rings and toric IOLs. This surgical strategy appears to be a safe and effective alternative for the visual rehabilitation of these challenging cases in the early postoperative period. The surgery is challenging in pediatric cases with ectopia lentis and Marfan’s syndrome and should be reserved as a late option after all lesser invasive alternatives (e.g. spectacles, contact lenses, etc.) have failed. The safety and effectiveness of this technique in pediatric eyes need to be further validated by studies with larger samples and longer follow-ups.

Disclosure Statement

The authors have no proprietary or financial interest concerning products or instruments described.

Table 1. Preoperative data

	BCVA	Manifest refraction	Keratometry, D
OD	20/70	-8.00, -2.50 × 65°	40.37 @ 17°, 42.35 @ 107°
OS	20/25	-6.00, -2.25 × 170°	40.96 @ 176°, 42.72 @ 86°

Table 2. Postoperative data

	Postoperative day 1					Last follow-up visit			
	UCVA	BCVA	manifest refraction	IOP	last follow-up	UCVA	BCVA	manifest refraction	IOP
OD	20/50	20/40	-1.50 sphere	10	34 months	20/50	20/25	-1.00, -0.50 × 100°	13
OS	20/40	20/25	-1.00 sphere	10	19 months	20/25	20/20	-0.50, -0.50 × 80°	13

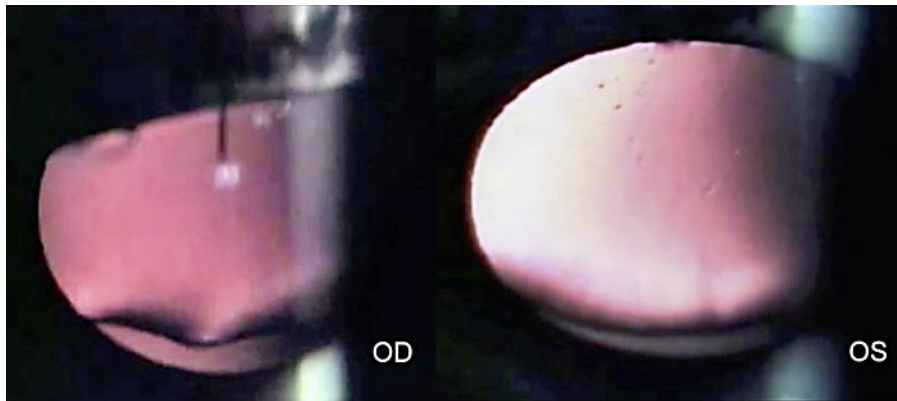


Fig. 1. Slit-lamp photograph showing bilateral lens subluxation, through mid-dilated pupils.

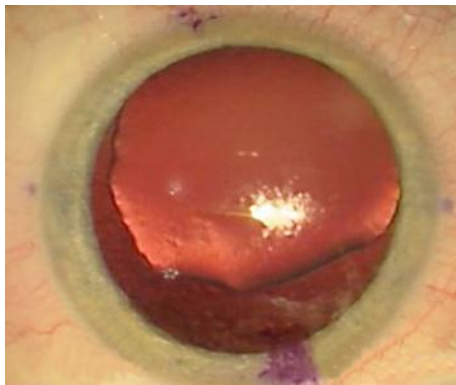


Fig. 2. Preoperative photograph of the right subluxated lens with reference astigmatism marks at the limbus.

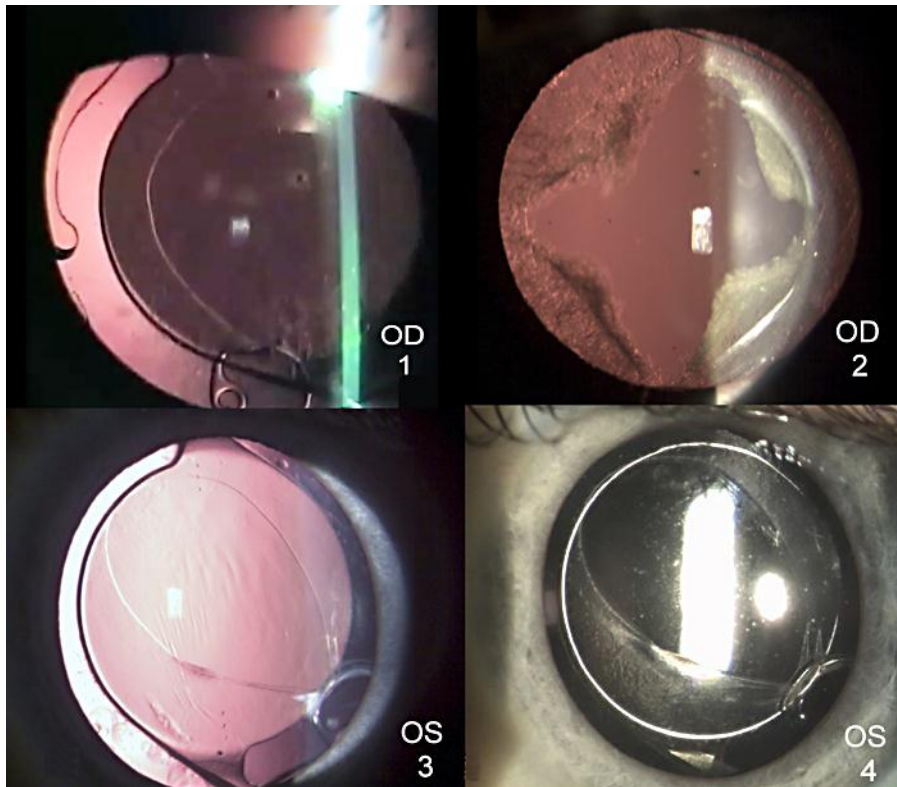


Fig. 3. Slit-lamp photograph status after bilateral implantation of scleral-fixed Cianni endocapsular rings and toric IOLs. (1) Right eye 27 months postoperatively. (2) Right eye 1 month after YAG capsulotomy, at the 34-month postoperative follow-up. (3) Left eye 12 months postoperatively. (4) Early posterior capsular opacification at 19 months postoperatively in the left eye.

References

- 1 Sharma T, Gopal L, Shanmugam M, Bhende P, Agrawal R, Shetty NS, Gopalakrishna M, Rao MK, Balusamy S: Retinal detachment in Marfan syndrome: clinical characteristics and surgical outcome. *Retina* 2002;22:423–438.
- 2 Romano P, Kerr N, Hope G: Bilateral ametropic functional amblyopia in genetic ectopia lentis: its relation to the amount of subluxation, an indicator for early surgical management. *Binocul Vis Strabismus Q* 2002;17:235–241.
- 3 Neely D, Plager D: Management of ectopia lentis in children. *Ophthalmol Clin North Am* 2001;14:493–499.
- 4 Asadi R, Kheirkhah A: Long-term results of scleral fixation of posterior chamber intraocular lenses in children. *Ophthalmology* 2008;115:67–72.
- 5 Kopel A, Carvounis P, Hamill M, Weikert MP, Holz ER: Iris-sutured intraocular lenses for ectopia lentis in children. *J Cataract Refract Surg* 2008;34:596–600.
- 6 Wu-Chen W, Letson R, Summers C: Functional and structural outcomes following lensectomy for ectopia lentis. *J AAPOS* 2005;9:353–357.
- 7 Maumenne I: The cornea in connective tissue disease. *Ophthalmology* 1978;85:1014–1017.
- 8 Gwiazda J, Sheiman M, Mohindra I, Held R: Astigmatism in children: changes in axis and amount from birth to six years. *Invest Ophthalmol Vis Sci* 1984;25:88–92.

- 9 Bauer N, Vries ND, Webers C, Hendrikse F, Nuijts RM: Astigmatism management in cataract surgery with the AcrySof toric intraocular lens. *J Cataract Refract Surg* 2008;34:1483–1488.
- 10 Horn J: Status of toric intracocular lenses. *Curr Opin Ophthalmol* 2007;18:58–61.
- 11 Sun X, Vicary D, Montgomery P, Griffiths M: Toric intraocular lenses for correcting astigmatism in 130 eyes. *Ophthalmology* 2000;107:1776–1781.
- 12 Vasavada V, Vasavada V, Hoffman R, Spencer TS, Kumar RV, Crandall AS: Intraoperative performance and postoperative outcomes of endocapsular ring implantation in pediatric eyes. *J Cataract Refract Surg* 2008;34:1499–1508.
- 13 Konradsen T, Kugelberg M, Zetterstrom C: Visual outcomes and complications in surgery for ectopia lentis in children. *J Cataract Refract Surg* 2007;33:819–824.
- 14 Bahar I, Kaiserman I, Rootman D: Cionni endocapsular ring implantation in Marfan's syndrome. *Br J Ophthalmol* 2007;91:1477–1480.
- 15 Gimbel HV, Brucks M, Dardzhikova AA, Camoriano GD: Scleral fixation of a subluxated intraocular lens-capsular bag complex through a fibrotic continuous curvilinear capsulorhexis. *J Cataract Refract Surg* 2011;37:629–632.