

This is an Open Access article licensed under the terms of the Creative Commons Attribution-NonCommercial-NoDerivs 3.0 License ([www.karger.com/OA-license](http://www.karger.com/OA-license)), applicable to the online version of the article only. Distribution for non-commercial purposes only.

# Post-Cataract Surgery Visual Disturbance in a Retinitis Pigmentosa Patient with Asteroid Hyalosis

Yoko Jingami Atsushi Otani Hiroshi Kojima  
Yukiko Makiyama Nagahisa Yoshimura

Department of Ophthalmology, Kyoto University Graduate School of Medicine,  
Kyoto, Japan

## Key Words

Retinitis pigmentosa · Cataract surgery · Asteroid hyalosis · Pars plana vitrectomy

## Abstract

A patient with retinitis pigmentosa showed visual disturbances following successful cataract surgery. He had a dense asteroid hyalosis in the eye before cataract surgery. After the surgery he noticed that his vision became worse. The visual disturbance was explained as being caused by the progression of retinal degeneration. Although the electroretinogram was non-recordable, the degeneration of macular area appeared relatively small. We considered that dense asteroid hyalosis was responsible for his visual disturbances, and pars plana vitrectomy (PPV) was performed to remove the asteroid hyalosis. After the PPV, rapid improvement of his visual acuity was observed. Cataract surgery may affect the status of asteroid hyalosis and cause rapid visual loss. PPV should be considered for retinitis pigmentosa patients with dense asteroid hyalosis, especially when a large decrease in visual acuity is noted shortly after cataract surgery.

## Introduction

Asteroid hyalosis is a common, usually asymptomatic, benign vitreous disease that affects older individuals [1]. When dense asteroid hyalosis occurs, it can sometimes lead to visual disturbances. In such cases, pars plana vitrectomy (PPV) has been used to help these patients recover their visual acuity [2]. However, asteroid hyalosis in patients with retinitis pigmentosa (RP) has been rarely reported [3] and as far as we know, there have been no cases of asteroid hyalosis removal in RP patients.

In the current case, a patient with RP showed visual disturbances following successful cataract surgery. After undergoing PPV, rapid improvement of his visual acuity was observed.

### Case Report

A 58-year-old man diagnosed with RP and asteroid hyalosis was referred to our hospital after complaining of visual disturbance following cataract surgery in his left eye. The patient's previous small-incision phacoemulsification with implantation of a posterior chamber intraocular lens was uneventful. His best corrected visual acuity (BCVA) was 20/40 prior to his initial surgery. However, visual acuity began to decrease, which led to laser capsulotomy. By the time he was first seen in our clinic, his BCVA had been reduced to hand motion only. Slit-lamp and fundus examinations revealed dense asteroid hyalosis in the vitreous cavity (fig. 1a), perivascular atrophy of the retinal pigment epithelium, and vessel attenuation and bone spicule pigmentations at the peripheral retina (fig. 1b). Although the electroretinogram was non-recordable, the degeneration of macular area appeared relatively small, which was supported by both the Goldmann perimetry (fig. 1c) and optical coherence tomography results. Since our findings suggested that dense asteroid hyalosis was responsible for his visual disturbances, we performed a 23-gauge PPV to remove the asteroid hyalosis in conjunction with the creation of a posterior vitreous detachment using triamcinolone acetate to visualize vitreous. In this case, posterior vitreous detachment could easily be done, unlike typical RP cases that have abnormal vitreoretinal interface. BCVA improved to 20/30 at 1 week after surgery, and this level has been maintained for 6 months. Fundus examination and optical coherence tomography in the patient revealed a relatively well-preserved macula (fig. 1d, e).

### Discussion

Cataract is one of the major complications seen in RP patients. Although favorable results have been reported for cataract surgeries performed in RP patients, there are several risk factors that can potentially affect the outcome, and in some cases, actual worsening of visual acuity has been reported [4–6]. In the current case, the BVCA worsening was thought to be due to posterior capsular opacification and retinal atrophy, including phototoxic retinal damage. Since cataract surgery is also known to affect the vitreous shape, retinal tears and posterior vitreous detachment can occur [7, 8]. Therefore, it is possible that the cataract surgery could have affected this patient's asteroid hyalosis condition and ultimately caused his sudden BCVA loss.

The efficacy of PPV for asteroid hyalosis removal remains controversial [2, 9]. When choosing PPV, careful preoperative examinations are required in order to diagnose the macular conditions. In our patient, intensive preoperative examinations suggested that his macular functions remained relative to his visual acuity.

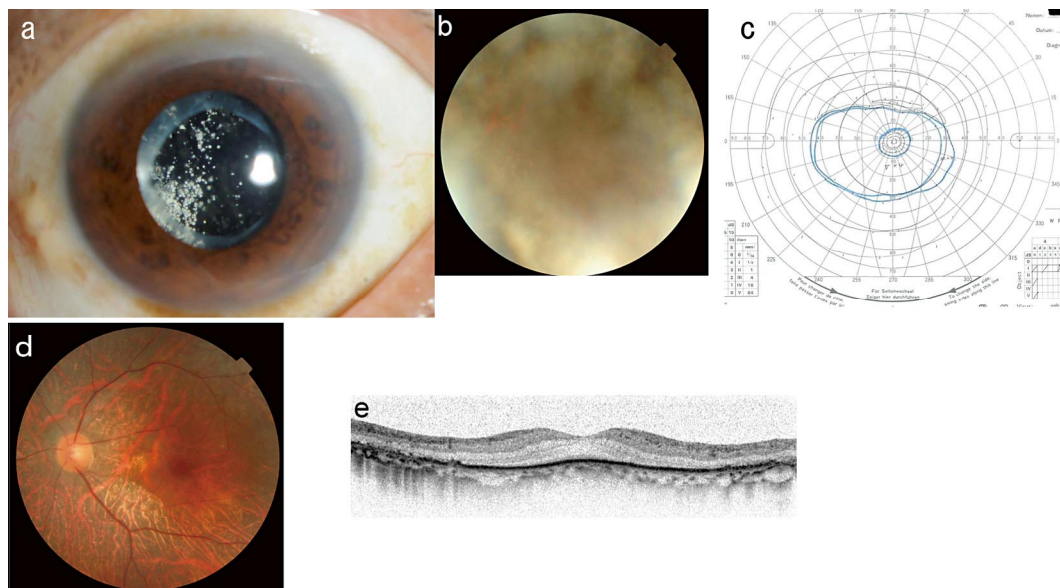
Overall, our current findings suggest that cataract surgery may affect the status of asteroid hyalosis and cause visual disturbance, especially in RP patients with visual field loss. PPV should be considered as a potentially effective treatment option for RP patients with dense asteroid hyalosis when a large decrease in the visual acuity is noted shortly after cataract surgery.

### Acknowledgement

This work was supported by the Ministry of Education, Science, Sports and Culture, Tokyo, Japan (grant-in-aid No. 17689045).

### Disclosure Statement

The authors declare that they have no conflict of interest.



**Fig. 1.** **a** Photograph of preoperative slit-lamp biomicroscopy. Dense asteroid hyalosis in the vitreous cavity is seen. **b** Preoperative fundus photograph. Details of the fundus can hardly be seen due to the dense asteroid hyalosis. **c** Goldmann perimetry. The region circled by the blue line indicates the annular scotoma. **d** Postoperative fundus photograph. **e** Optical coherence tomographic image. Foveal thickness appears to be normal.

## References

- 1 Mitchell P, Wang MY, Wang JJ: Asteroid hyalosis in an older population: the Blue Mountains Eye Study. *Ophthalmic Epidemiol* 2003;10:331–335.
- 2 Parnes RE, Zakov ZN, Novak MA, Rice TA: Vitrectomy in patients with decreased visual acuity secondary to asteroid hyalosis. *Am J Ophthalmol* 1998;125:703–704.
- 3 Hwang JC, Barile GR, Schiff WM, et al: Optical coherence tomography in asteroid hyalosis. *Retina* 2006;26:661–665.
- 4 Bastek JV, Heckenlively JR, Straatsma BR: Cataract surgery in retinitis pigmentosa patients. *Ophthalmology* 1982;89:880–884.
- 5 Newsome DA, Stark WJ, Maumane IH: Cataract extraction and intraocular lens implantation in patients with retinitis pigmentosa or Usher's syndrome. *Arch Ophthalmol* 1986;104:852–854.
- 6 Jackson H, Garway-Heath D, Rosen P, Bird AC, Tuft SJ: Outcome of cataract surgery in patients with retinitis pigmentosa. *Br J Ophthalmol* 2001;85:936–938.
- 7 Mirshahi A, Hoehn F, Lorenz K, Hattenbach LO: Incidence of posterior vitreous detachment after cataract surgery. *J Cataract Refract Surg* 2009;35:987–991.
- 8 Ripandelli G, Coppé AM, Parisi V, Olzi D, Scassa C, Chiaravalloti A, Stirpe M: Posterior vitreous detachment and retinal detachment after cataract surgery. *Ophthalmology* 2007;114:692–697.
- 9 Feist RM, Morris RE, Witherspoon CD, et al: Vitrectomy in asteroid hyalosis. *Retina* 1990;10:173–177.