

Single Case

Severe Clozapine Poisoning Treated by Extracorporeal Blood Purification Therapy

Andreas Hartjes^a Matthäus Machnik^a Christa Kubasta^b Karl Schratlbauer^c

^aDepartment for Anesthesia and Intensive Care Medicine, Krankenhaus der Barmherzigen Schwestern Ried, Ried, Austria; ^bInstitute for Medical and Chemical Laboratory Diagnostics, Blood Depot, Tissue Bank, Kepler University Hospital Linz, Linz, Austria; ^cInstitute for Laboratory Diagnostics, Krankenhaus der Barmherzigen Schwestern Ried, Ried, Austria

Keywords

Intoxication · Poisoning · Clozapine · Extracorporeal blood purification therapy · Hemoadsorption · CytoSorb · Case report

Abstract

Clozapine is a frequently used antipsychotic that, in case of overdose, can cause severe adverse side effects, such as hematological, cardiovascular, and neurological complications. As there is no specific antidote or reversal agent available, extracorporeal techniques such as CytoSorb hemoadsorption might represent a viable option, having already been used in a variety of intoxication scenarios with favorable rates of success. A 56-year-old male was admitted with generalized epileptic seizures and arrhythmias following ingestion of clozapine in a suicide attempt (5,000 mg). Subsequently, conventional supportive care was initiated. To accelerate drug removal, continuous veno-venous hemodiafiltration including the application of CytoSorb hemoadsorption therapy was started. Serial measurements confirmed rapid reduction of clozapine plasma levels. The patient remained hemodynamically stable throughout this period. Furthermore, there were no cardiac arrhythmias detected and liver values were normal. The patient improved and was successfully extubated 3 days after admission with good vigilance and no residual neurological abnormalities. This is the first clinical case report on the use of CytoSorb hemoadsorption in severe clozapine intoxication which helped quickly and efficiently reduce clozapine levels to nontoxic serum levels while preserving organ function. Therefore, CytoSorb might represent an alternative treatment modality to be considered for potentially lethal clozapine intoxications.

© 2023 The Author(s).
Published by S. Karger AG, Basel

Correspondence to:
Andreas Hartjes, Andreas.Hartjes@bhs.at

Introduction

Clozapine is a frequently used benzodiazepine-derived atypical antipsychotic. Despite its effectiveness, the drug remains underutilized given its severe adverse side effects, such as hematological (agranulocytosis), cardiovascular (hypotension, tachycardia), and neurological complications (sedation, seizures) [1]. As there is no specific antidote or reversal agent available in cases of overdose, supportive care is the only available treatment option, highlighting the urgent need for alternative countermeasures. Due to its ability to eliminate lipophilic substances, the CytoSorb hemoadsorption cartridge might represent such an option. This technology is based on highly porous, biocompatible beads capable of removing substances in the middle molecular range (up to 60 kDa) via size exclusion and hydrophobic interactions. While initially intended for the removal of inflammatory mediators, its ability to also remove exogenous substances such as commonly used drugs [2], has meanwhile been reported in a variety of intoxication scenarios with favorable rates of success, thus providing an opportunity for a therapeutic use in detoxification also for drugs like clozapine.

Case Report

We report on a 56-year-old male who was admitted to the emergency department by ambulance after being found to have generalized epileptic seizures and arrhythmias (extrasystole and QRS widening) surrounded by several empty medication blisters of clozapine. The presumed ingested dose was 5,000 mg (toxic dose: 500 mg). Preexisting medical conditions included obesity (BMI: 44.98 kg/m²), arterial hypertension, hyperlipidemia, paranoid schizophrenia/schizoaffective disorder, type 2 diabetes mellitus, as well as Hodgkin lymphoma (currently no therapy is required, under observation). The patients' premedication is depicted in Table 1. On arrival, the patient suffered a recurrent generalized seizure, requiring protective intubation, controlled ventilation, and analgosedation with propofol and remifentanyl. A cerebral CT on admission was unremarkable (initial Glasgow Coma Scale 8). Physiologic and laboratory data on admission are depicted in Table 2. Baseline serum creatinine levels measured 6 months before admission were 1.07 mg/dL. Within only 1 h after being found by the ambulance, the patient was transferred to the intensive care unit, where a gastric tube was inserted and 50 g of activated charcoal administered. In addition, prokinetic therapy was started. Due to the cardiac (QRS complex widening, pronounced extrasystole, bradycardia) and neurological side effects (generalized seizure), 100 mL of sodium bicarbonate was administered intravenously in order to increase the plasma protein binding of the neuroleptic drug through metabolic alkalosis and thus reduction of the free (active) fraction. To accelerate drug removal, continuous venovenous hemodiafiltration (CVVHDF) including the application of CytoSorb hemoadsorption therapy (2 adsorbers for 12 h each) was started 4–6 h after the suspected clozapine ingestion. Systemic clozapine drug concentration before initiation of combined CVVHDF and hemoadsorption was 4,779 ng/mL (see first value pre-adsorber) and serial measurements confirmed rapid reduction of clozapine plasma levels (Fig. 1). The patient remained hemodynamically stable throughout this period (maximum norepinephrine dosage: 0.0038 µg/kg/min). Furthermore, there were no cardiac arrhythmias detected and liver values were normal. Due to questionable aspiration and increasing inflammatory parameters, antibiotic therapy was initiated with ampicillin/sulbactam. After completion of the 2nd hemoadsorption treatment, an awakening trial was performed. The patient was disoriented following completion of analgesia with propofol/remifentanyl, and a one-time generalized seizure was suspected. Therefore, the patient was again sedated more deeply with RASS –4, this time with sufentanil and midazolam, which

Table 1. Premedication of the patient prior to admission

	Dose	Daily application interval
Escitalopram	10 mg	1-0-0
Lithium carbonate	450 mg	1-0-0
Lorazepam	1 mg	0-0-0-1
Haloperidol	1 mg	1-0-2
Ramipril	5 mg	1-0-0
Sitagliptin/metformin	50 mg/850 mg	1-0-0

were stopped after 24 h. The patient however showed prolonged regain of responsiveness which is why midazolam was antagonized with 0.4 mg flumazenil after 20 h. Consequently, the patient awoke but was not oriented. To exclude a central anticholinergic syndrome, physostigmine was administered as a bolus and maintained thereafter for 24 h via perfusor. Consequently, the patient improved and was successfully extubated 3 days after admission with good vigilance and no residual neurological abnormalities (see Table 1 for physiologic and laboratory data post-hemoadsorption treatment). Due to his condition (3rd suicide attempt), the patient was transferred to the psychiatric department of a specialized hospital. The CARE Checklist has been completed by the authors for this case report, attached as online supplementary material (for all online suppl. material, see <https://doi.org/10.1159/000531130>).

Discussion

To our knowledge, this is the first clinical case report on the use of CytoSorb hemoadsorption in severe clozapine intoxication. The use of combined CVVHDF and CytoSorb hemoadsorption therapy helped quickly and efficiently reduce clozapine levels to nontoxic serum levels, while preserving organ function. We calculated pharmacokinetics, i.e., spontaneous elimination of clozapine and its metabolite norclozapine considering their half-lives (assuming linear kinetics even in high concentrations) [3] and were able to show that removal was accelerated under extracorporeal therapy (Fig. 1). In the setting of acute overdose, elimination half-life times of 16.9 h for clozapine and 22.5 h norclozapine have been reported [3]. Clozapine is quickly and almost completely absorbed after oral administration with time to maximum plasma concentration (T_{max}) of 1.5–2 h in which the maximum effect of the drug appears approximately 4 h after administration [4]. However, its bioavailability is only about 27%–50% due to the first-pass metabolism. In addition, approximately 95% of the drug is bound to plasma proteins [4]. The primary mode of elimination for clozapine is extensive hepatic metabolism, which generates two primary metabolites: N-desmethylclozapine (norclozapine) and clozapine N-oxide. Both metabolites are characterized by a longer half-life time and a similar affinity for D2 dopamine and 5-HT₂ serotonin receptors. This metabolic process involves the activity of several cytochrome P450 (CYP) isoenzymes, particularly CYP1A2, as well as enzymes 3A4, 2C19, and 2D6 [4]. The pharmacokinetics of clozapine are described as a one-compartment model with a median volume of distribution of 508 L for clozapine and 624 L for norclozapine. Elimination is best described as first order with a median clearance value of 30.3 L/h for clozapine and 46.3 L/h for norclozapine [5]. Clozapine serum levels vary significantly by dose, sex, smoking status, body weight, and induction or inhibition of cytochrome P enzymes. With regard to our patient's concomitant medication, we found that there was no relevant enzyme induction or inhibition which is to be expected. Of note, according to various sources, it is questionable whether renal replacement therapy has an impact on drug

Case Reports in Nephrology and Dialysis

DOI: 10.1159/000531130

© 2023 The Author(s). Published by S. Karger AG, Basel
www.karger.com/cnd

Hartjes et al.: Hemoadsorption in Severe Clozapine Intoxication

Table 2. Physiologic and laboratory data before (day 1) and in the post-hemoadsorption treatment period (days 2–4)

	Day 1	Day 2	Day 3	Day 4
pH	7.51	7.41	7.4	7.46
pCO ₂ , mm Hg	31	43	47	37
pO ₂ , mm Hg	96	98	83	96
PaO ₂ /FiO ₂ , mm Hg	384	392	312	384
FiO ₂ , %	25	25	25	25
SpO ₂ , %	98	98	98	98
MV, L/min	9.2	5.7	6.6	6
Base excess, mmol/L	2.5	2.3	3.7	3.1
Bicarbonate, mmol/L	25	27	28.5	26.4
Urea, mg/dL	45	20	26	30
Creatinine, mg/dL	1.27	0.74	0.96	0.91
Diuresis, mL/24 h	2,760	2,150	2,380	8,140
Estimated glomerular filtration rate, mL/min	585	109	N/A	N/A
Fluid balance, mL	2,859	3,143	281	-5,173
Na, mmol/L	143	138	141	140
K, mmol/L	4.4	3.7	4.3	3.9
Cl, mmol/L	107	105	109	108
Mg, mmol/L	0.95	0.8	0.91	0.86
Bilirubin, mg/dL	0.9	0.4	0.2	0.2
AST, U/L	20	27	20	20
Alt, U/L	19	12	12	11
AP, U/L	88	72	67	73
gGT, U/L	20	14	14	22
LDH, U/L	236	156	129	131
Hemoglobin, g/dL	13	11.5	10.1	10.6
Hct, %	37	33	30	31
Leucocytes, G/L	16.5	11.9	9.66	8.17
Platelets, G/L	267	200	180	184
C-reactive protein, mg/L	19	59	88	68
Procalcitonin, ng/mL	0.08	0.06	N/A	0.06
Interleukin-6, pg/mL	15	N/A	N/A	N/A
INR	1	1.4	1	1
Fibrinogen, mg/dL	316	341	459	660
aPTT, s	30.7	36.3	34.2	36.3

removal [6, 7]. However, to enable regional citrate anticoagulation we did not use the adsorber in a standalone, hemoperfusion-like set-up, but in combination with a hemofilter in CVVHDF mode. Pre- and post-measurements showed direct removal of clozapine and its metabolite by CytoSorb, even if saturation seemed to happen after around 6 h. Given the fact that clozapine is 95% protein-bound (predominantly to albumin), adsorption by the device is also likely from a theoretical point of view. Drug removal by CytoSorb in intoxications is not covered by the

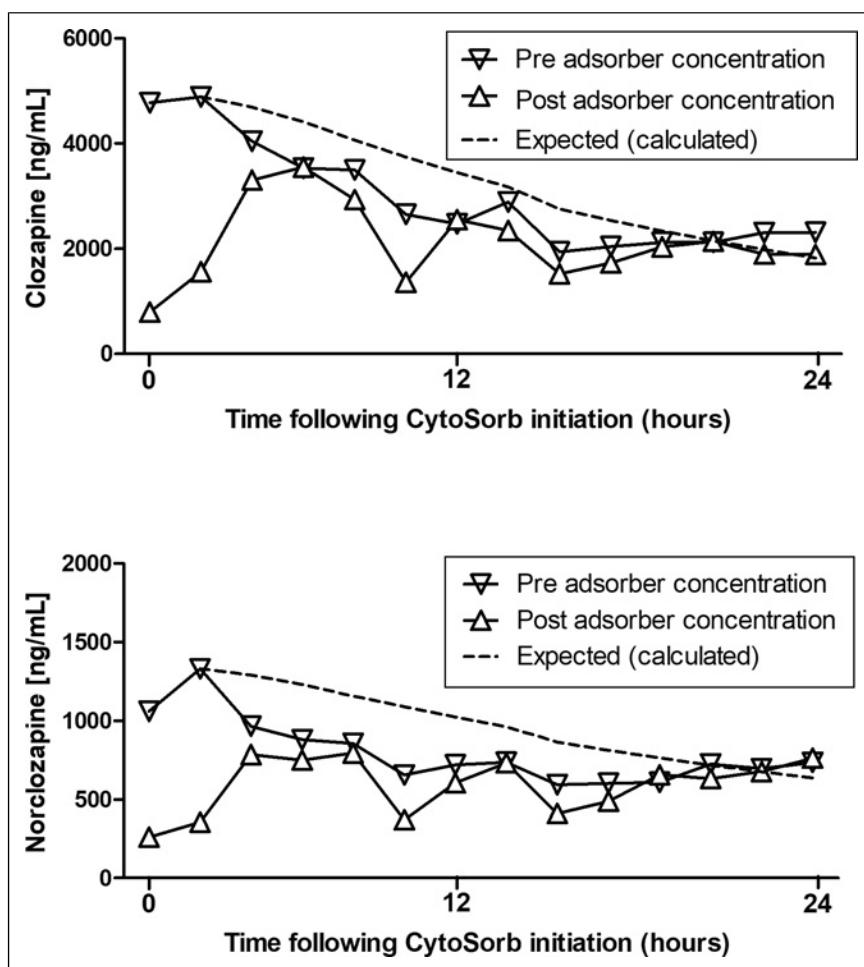


Fig. 1. Plasma levels of clozapine and its metabolite norclozapine during the course of continuous venovenous hemodiafiltration (CVVHDF) + CytoSorb hemoadsorption treatment. The dashed line indicates the expected (calculated) spontaneous elimination considering the half-life period of both compounds (assuming linear kinetics even in high concentrations). Each CytoSorb treatment was run for 12 h.

current IFU, but a number of case reports are meanwhile published and also a recent review on this field of use is available [2]. Not in all those cases a direct impact of the adsorber could be proven, but the use of CytoSorb in intoxications could also be reasonable to address complications like rhabdomyolysis, liver failure, or systemic hyperinflammation. Reuchsel et al. [8], however, had measured pre- and post-adsorber levels when using CytoSorb in the setting of lamotrigine intoxication and also suspected saturation much earlier than after the maximum use time per adsorber of 24 h. Reduced elimination can of course also occur due to the concentration-dependency of CytoSorb removal with reduced efficacy in low(er) concentrations, but an appropriate dosing of therapy, which is the length of the overall therapy (i.e., number of adsorbers applied) as well as its intensity (i.e., time interval per adsorber), is becoming generally more and more recognized as an important aspect to ensure therapeutic success. So also in the classic field of septic/vasoplegic shock, recommendations by the manufacturer are given to exchange the adsorber after 12 h in case of ongoing (or newly developing) instability, however, a structured investigation of this approach is not yet available. In light of our findings and in line with previous reports on the use of CytoSorb in intoxications, we would like to conclude that the use of CytoSorb might also represent an alternative treatment modality to be considered for potentially lethal clozapine intoxications.

Statement of Ethics

The research was conducted ethically in accordance with the World Medical Association Declaration of Helsinki. Ethical approval was not required for this single case report in accordance with local guidelines. The patient's legal representative has given written informed consent to publish their medical case and any accompanying images.

Conflict of Interest Statement

The authors have no conflicts of interest to declare.

Funding Sources

The authors declare no funding relevant to the study.

Author Contributions

A.H. and M.M. treated the patient, discussed the data, and performed the manuscript preparation. C.K. revised the manuscript and provided significant intellectual input to the treatment of the reported patient and the manuscript. K.S. analyzed and interpreted the data. All authors have approved the final version of the manuscript. A.H. is the guarantor of this work.

Data Availability Statement

All data generated or analyzed during this study are included in this article and can be obtained from the corresponding author upon reasonable request.

References

- 1 Dragoi AM, Radulescu I, Năsui BA, Pop AL, Varlas VN, Trifu S. Clozapine: an updated overview of pharmacogenetic biomarkers, risks, and safety-particularities in the context of COVID-19. *Brain Sci.* 2020 Nov 11; 10(11):840.
- 2 Mitrovic D, Huntjens DW, de Vos EAJ, van Tellingen M, Franssen EJJ. Extracorporeal hemoadsorption with the CytoSorb device as a potential therapeutic option in severe intoxications: review of the rationale and current clinical experiences. *J Clin Pharm Ther.* 2022 Sep;47(9):1444–51.
- 3 Renwick AC, Renwick AG, Flanagan RJ, Ferner RE. Monitoring of clozapine and norclozapine plasma concentration-time curves in acute overdose. *J Toxicol Clin Toxicol.* 2000;38(3):325–8.
- 4 Jovanović M, Vučićević K, Miljković B. Understanding variability in the pharmacokinetics of atypical antipsychotics - focus on clozapine, olanzapine and aripiprazole population models. *Drug Metab Rev.* 2020;52:1–18.
- 5 Albitar O, Harun SN, Zainal H, Ibrahim B, Sheikh Ghadzi SM. Population pharmacokinetics of clozapine: a systematic review. *BioMed Res Int.* 2020 Jan 7;2020:9872936.
- 6 Available from: https://www.accessdata.fda.gov/drugsatfda_docs/label/2010/019758s062lbl.pdf.
- 7 Jacob A, Zahr N, Hulot JS, Boussouar S, Vilain J, Lafont-Rapnouil S, et al. Therapeutic drug monitoring of clozapine in a hemodialysed smoking patient with schizophrenia. *Ther Drug Monit.* 2009;31(3):281–2.
- 8 Reuchsel C, Gonnert FA. Successful treatment of severe lamotrigine intoxication with CytoSorb hemoadsorption. *Blood Purif.* 2022;51(8):679–82.