

Cerebrovasc Dis 2013;36:155–157
DOI: [10.1159/000352065](https://doi.org/10.1159/000352065)**Rapid Progression of Unilateral Moyamoya Disease in a Patient with a Family History and an *RNF213* Risk Variant**Yohei Mineharu^{a,d} Yasushi Takagi^c Jun C. Takahashi^c
Hirokuni Hashikata^e Wanyang Liu^d Toshiaki Hitomi^d
Hatasu Kobayashi^d Akio Koizumi^d Susumu Miyamoto^c^aDivision of Neuroendovascular Therapy, Institute of Biomedical Research and Innovation, and ^bDepartment of Neurosurgery, Kobe City Medical Center General Hospital Kobe, Departments of ^cNeurosurgery and ^dHealth and Environmental Sciences, Kyoto University Graduate School of Medicine, Kyoto, and ^eDepartment of Neurosurgery, Kitano Hospital, Tazuke Kofukai Medical Research Institute, Osaka, Japan**Introduction**

Moyamoya disease (MMD) is a progressive steno-occlusive vasculopathy that involves large intracranial arteries accompanied by moyamoya collaterals [1, 2]. It was demonstrated that the p.R4810K missense variant (rs 112735431) in the *RNF213* gene on the 17q25.3 locus [3–5] increases susceptibility to MMD in East Asian populations [6]. Genetic diagnosis enabled us to find pre-symptomatic patients with MMD.

Case Report

A 36-year-old woman, who had no past medical history, received MRI screening examination to check for MMD because her mother and her aunt had the disease. The initial examination in August 2005 showed no apparent intracranial arterial stenosis (fig. 1a). One year later, she received the second MRI scan, which showed proximal right middle cerebral artery (MCA) occlusion (fig. 1b). Conventional angiography confirmed MCA occlusion with minor moyamoya collaterals at the base of the brain (fig. 1c). No stenosis was observed on the contralateral side. Despite rapid progression of the arterial occlusion, the patient did not develop any neurological symptoms or ischemic brain lesions on MRI. She was conservatively followed up by annual MRI examinations without surgical intervention. The occlusive lesion has remained stable for 6 years without any progression.

The patient and her family members, including unaffected members, received both genetic testing for *RNF213* and MRI examination in 2005; the family is pedigree 18 in our previous paper [6]. Sequencing of *RNF213* in the patient's mother and aunt re-

vealed two haplotypes carrying p.R4810K: allele A₂, which is common among patients with MMD, and allele A₁, which is rare among patients with MMD [6]. The patient inherited an A₁ allele for p.R4810K (fig. 1d). On the other hand, her elder and younger sisters inherited an A₂ allele from their mother for p.R4810K, and no arterial stenosis was identified in either the initial or annual follow-up MRI examinations.

Ethical approval for this study was given by the Institutional Review Board and Ethics Committee of the Kyoto University School of Medicine, Kyoto University, Japan.

Discussion

Due to incomplete penetrance of the p.R4810K variant, *RNF213* is considered to be a susceptibility gene and other genetic or environmental factors may be associated with MMD. However, the genome-wide linkage and association analysis only showed a significant signal in *RNF213* on 17q25.3, indicating that other genetic factors have a much lower effect as compared with *RNF213* [3, 6]. p.R4810K or other mutations in *RNF213* were observed in all familial cases of MMD including Japanese, Korean and European populations and p.R4810K was associated with an increased risk of MMD with an odds ratio of as much as 338.9 for a Japanese population [6], which was confirmed in independent studies [5, 7]. These results indicate that p.R4810K screening would be a most appropriate approach to identify asymptomatic patients, especially those who have a family history of MMD.

In the present study, a 36-year-old woman, who was positive for *RNF213*, had de novo progression of unilateral MMD within only a year. In the past reports, a 59-year-old woman showed de novo progression of bilateral MMD within a 5-year interval and a 46-year-old woman developed unilateral MMD between 2004 and 2009 [8, 9]. Albeit not adult cases, Amlie-Lefond et al. [10] reported a 3-month-old patient with MMD and reviewed other 8 cases of early infancy before the age of 1 year, suggesting that MMD can develop very rapidly. Therefore, frequent follow-ups by MRI should be recommended for those who were diagnosed as having genetic risk factors for MMD.

Although the elder and younger sisters of the patient had the p.R4810K variant, they have not developed MMD. Since they may develop MMD several years later, a close follow-up is necessary. Alternatively, the discordant phenotype of the sisters may represent allelic differences between A₁ and A₂ [6]. The patient and the affected mother and aunt share p.R4810K on the same allele (A₁), whereas the unaffected sisters have A₂, suggesting a possibility that the 5' portion of *RNF213* may have a modifier effect on the steno-occlusive phenotype. Still another possibility includes environmental factors, which may affect the pene-

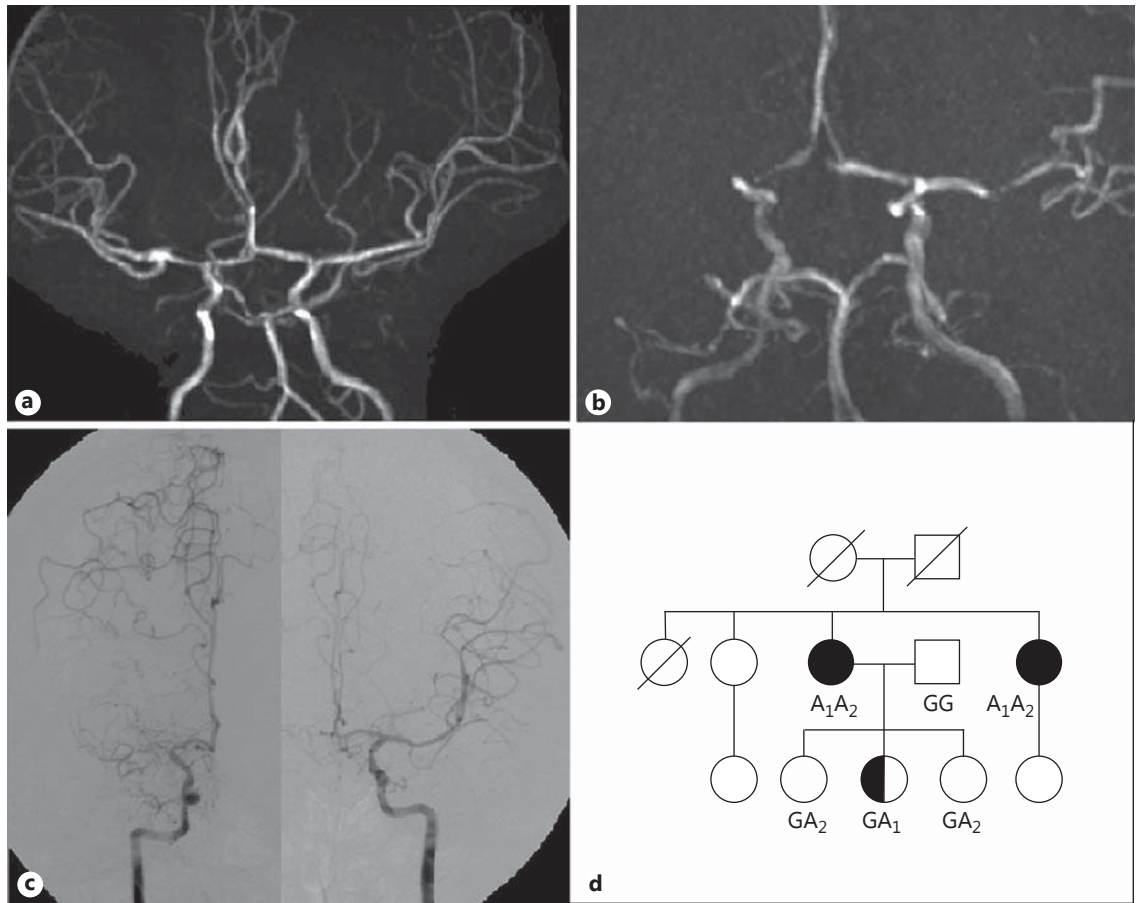


Fig. 1. **a** Initial magnetic resonance angiography (MRA; 1.5 tesla) of the patient. No arterial stenosis was observed. **b** Second MRA (1.5 tesla) study 1 year after the initial examination showed disruption of the right MCA. **c** Digital subtraction angiography following the second MRA examination revealed right MCA occlusion and the formation of collateral circulation at the base of the brain. Distal MCA was filled with contrast media via collaterals. **d** The family with familial MMD. Filled symbols indicate patients with MMD; half-filled symbols, patients with unilateral MMD; circles,

women; squares, men; crossed symbols, deceased people. The half-filled symbol in the third generation represents the 36-year-old patient in this report. Genotypes of the risk allele of *RNF213* are shown. GG represents wild type; GA, homozygote for the risk variant, AA heterozygote for the risk variant. Numbers are attached to the variant 'A' to discriminate the two different alleles. The patient and her affected mother and aunt share the risk variant on the same allele (A₁).

trance, although we could not identify any environmental differences between the affected patient and the unaffected sisters. The patient had one A allele (heterozygote) and developed unilateral MMD, whereas her mother and aunt had two A alleles (homozygote) and developed bilateral MMD. Miyatake et al. [7] reported that the number of risk alleles in *RNF213* is associated with earlier age at onset and a severe form of the disease. Bilateral progression may also be associated with the number of risk alleles. Further follow-ups and investigations are warranted for this family.

Acknowledgements

This work was partly supported by grants from the Ministry of Education, Science, Sports and Culture of Japan (Kiban Kenkyu A: 14207016 and 22249020, S: 17109007, Tokutei Kenkyu: 15012231, 16012232, 17019034 and 18018022) and Research Committee on Moyamoya Disease of the Ministry of Health, Labor and Welfare, Japan.

Disclosure Statement

None.

References

- 1 Guidelines for diagnosis and treatment of moyamoya disease (Spontaneous Occlusion of the Circle of Willis). *Neurol Med Chir (Tokyo)* 2012; 52:245–266.
- 2 Czabanka M, Peña-Tapia P, Schubert GA, Heppner FL, Martus P, Horn P, et al: Proposal for a new grading of Moyamoya disease in adult patients. *Cerebrovasc Dis* 2011;32:41–50.
- 3 Mineharu Y, Liu W, Inoue K, Matsuura N, Inoue S, Takenaka K, et al: Autosomal dominant moyamoya disease maps to chromosome 17q25.3. *Neurology* 2008;70:2357–2363.
- 4 Mineharu Y, Takenaka K, Yamakawa H, Inoue K, Ikeda H, Kikuta K-I, et al: Inheritance pattern of familial moyamoya disease: autosomal dominant mode and genomic imprinting. *J Neurol* 2006;77:1025–1029.
- 5 Kamada F, Aoki Y, Narisawa A, Abe Y, Komatsuzaki S, Kikuchi A, et al: A genome-wide association study identifies RNF213 as the first Moyamoya disease gene. *J Hum Genet* 2010;56:1–7.
- 6 Liu W, Morito D, Takashima S, Mineharu Y, Kobayashi H, Hitomi T, et al: Identification of RNF213 as a susceptibility gene for moyamoya disease and its possible role in vascular development. *PLoS One* 2011; 6:e22542.
- 7 Miyatake S, Miyake N, Touho H: Homozygous c.14576G>A variant of RNF213 predicts early-onset and severe form of moyamoya disease. *Neurology* 2012;78:803–810.
- 8 Fukaya R, Yoshida K, Akiyama T, Kawase T: De novo development of moyamoya disease in an adult female. Case report. *J Neurosurg* 2009;111: 943–946.
- 9 Shimoda Y, Fujimura M, Inoue T, Shimizu H, Tominaga T: Temporal profile of de novo development of moyamoya vasculopathy in an adult. *Neurol Med Chir (Tokyo)* 2012;52:339–342.
- 10 Amlie-Lefond C, Bernard TJ, Sébire G, Friedman NR, Heyer GL, Lerner NB, et al: Predictors of cerebral arteriopathy in children with arterial ischemic stroke: results of the International Pediatric Stroke Study. *Circulation* 2009;119:1417–1423.