

'Six Memos' for Lymph Node Fine-Needle Cytology and Flow Cytometry

Pio Zeppa

Department of Pathology, Hospital 'San Giovanni di Dio e Ruggi d'Aragona' of Salerno, Salerno, Italy

When dealing with a specific subject, we may happen to recall or figure out something irrelevant or completely unrelated to the subject we are dealing with. This phenomenon has been widely explored and defined as 'involuntary memory' or 'stream of consciousness' in some literary masterpieces of the 20th century [1, 2]. Nowadays, in psychiatry, it is known as 'involuntary autobiographical memory chains' [3], and it may occur in one's professional life too. While I was conceiving my contribution to this issue of *Acta Cytologica*, dedicated to lymph node (LN) fine-needle cytology (FNC) and flow cytometry (FC), I often and involuntarily recalled the book *Six Memos for the Next Millennium*, also known as *The American Lessons* by the Italian writer Italo Calvino. The work was conceived as a cycle of conferences on the qualities of literature to be held at Harvard University. Sadly, Calvino died before lecturing and the writings were published after his death [4]. Since then, *The American Lessons* has become a classic of international literature, and has been translated into several different languages. It was hard for me to understand the relation between Calvino's *Memos* and FC but, browsing the book, I discovered the 'memory chain'. In fact Calvino's *Memos* refer to six qualities of literature, namely lightness, quickness, exactitude, visibility, multiplicity and consistency, which he believed to be the legacy of literature to the third millennium (fig. 1). I immediately recognized these items as specific qualities

of FC too, which I shall now consider in turn. Lightness: just 10 ml of cell suspension is enough for a complete and extensive analysis, with minimum waste; only few bites are needed to store the obtained data indefinitely. Quickness: less than 2 h for a complete phenotypization and an accurate analysis. Exactitude: thousands of cells counted, singularly evaluated and classified as positive or negative for each tested antigen. Visibility: single events displayed on comprehensive, analytical and ichnographic dot plots and histograms. Multiplicity: simultaneous evaluation of different antigen expressions. Consistency: strong correspondence with clinical, cytological and phenotypical data. The only condition for an accurate and effective FC analysis is having a suspension of isolated, vital cells; therefore, LN-FNC perfectly fits with FC, conveniently exploiting the above reported 'memos'. Since the pioneering studies on the subject [5, 6], hundreds of articles and dozens of books have explored this subject. This issue offers a number of comprehensive reviews that describe the state of the art of LN FNC-FC and all its possible applications. FNC and FC are two independent procedures that can conveniently meet and merge, in specific conditions and for specific purposes. Perfect technical procedures and preanalytical interpretation of the smear are essential conditions for a successful analysis. The article by Barroca and Marques [7] describes the technical basis and preanalytical evaluations of FC, as well as the basis for a cor-

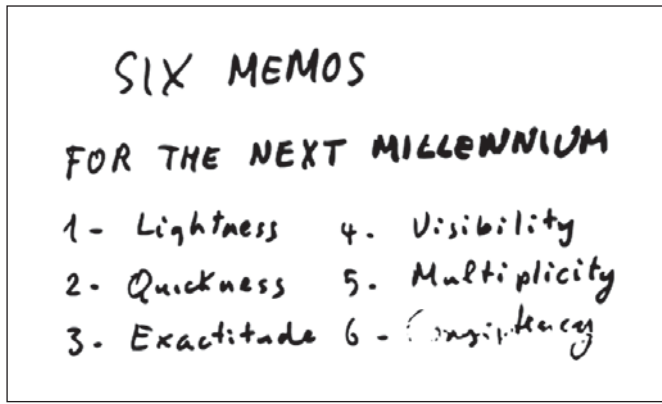


Fig. 1. Calvino's notebook [4] reporting the six qualities of literature that the author believes to be a valued legacy for the third millennium. The same qualities fit with FC applied to LN FNC.

rect application. FNC diagnosis and classification of non-Hodgkin lymphoma (NHL), which was once considered impossible, is now an acknowledged diagnostic possibility, despite its limitations. The article by Cozzolino et al. [8] provides a description and a critical evaluation of the diagnostic algorithms for FNC-FC diagnosis and classification of NHL, as they have been developed in different experiences. One of the main features of NHL is the involvement of extranodal sites, either as primary or secondary processes. Many nonlymphomatous proliferations arise in extranodal sites, mainly along autoimmune processes, and may be the background for the onset of NHL [9]. Therefore, reactive or lymphomatous processes are also observed in extranodal FNC samples from the thyroid, salivary glands, lung and other organs. In these cases, ROSE (rapid on-site evaluation) and additional FC passes for FC may turn a cytological diagnostic difficulty into an accurate FNC diagnosis. Notably, the value of a preoperative diagnosis is enhanced when such a diagnosis occurs in extranodal organs, where a diagnostic biopsy may be complex and even useless. Stacchini et al. [10] provide an interesting review of FNC-FC main applications with extranodal lymphoproliferative processes. An FNC-FC diagnosis of benign and malignant lymphoproliferative processes is very helpful, and greater advantages may be obtained in the case of deeply located LNs. Transesophageal endoscopic ultrasound (EUS) and endobronchial ultrasound (EBUS) have gained a central role in the diagnosis of deeply located LNs [11–13]. Their application is focused on the staging of tumors from lung and other organs but, dealing with LNs, EUS/EBUS also explore lymphoproliferative processes. FNC-FC provides a

significant contribution to EUS/EBUS, and the advantages of this application are widely reported in the article by Jin and Wakely [14]. The diagnosis of lymphoproliferative processes is the main application of FNC-FC but, given that FNC is a first-line procedure in LN enlargement, the occurrence of metastases or tumors of unknown nature or origin may occur, and FC is extremely helpful in these cases [15]. Moreover, whereas NHL diagnosis and classification are crucial points of LN pathology, the identification of nonneoplastic, reactive LN enlargements has a greater clinical relevance, both to avoid useless biopsies and to identify possible causes and specific agents. These advantages are enhanced in the case of pediatric patients, where an invasive biopsy is a demanding task both for patients and clinicians. FNC-FC can offer a substantial contribution to the identification of these entities and all the issues of this application have been widely described [16]. The occurrences of pleural and peritoneal effusions or CSF involvement are frequent in lymphoproliferative processes and in the rare primary effusion lymphoma. Chronic NHL, which is frequently associated with immunodeficiency, may cause reactive and infectious processes possibly caused by lymphocytes. Moreover, immunodeficiency may also cause a second neoplasm. As a consequence, the cytological evaluation of effusions may be complex and not effective in the case of scanty or heterogeneous cellularity. FC may be helpful in these cases, especially in the differentiation between low-grade NHL and reactive processes, which are a main diagnostic problem in CSF and effusions. FC applications on cytological samples are described by Bode-Lesniewska [17]. As reported above, effusions may also be caused by nonlymphomatous neoplasms and FC also contributes, to a lesser extent, to the diagnosis of these tumors. Davidson [18] provides a comprehensive review of FC applications with metastatic effusions, further expanding its possible applications. Despite the reported advantages, FC has its own limitations, including a small percentage of undefined cases and a variable accuracy in NHL subtyping. Recent genetic and molecular techniques and new technologies have addressed the diagnosis of NHL, aiming at greater accuracy and tailored therapies. Taking this into account, the phenotypical definition of NHL may not be sufficient in terms of clinical needs. Numerous studies showed that FNC is suitable for different molecular procedures and LN FNC-FC plays a key role in guaranteeing the best management of the available material. The article by Peluso et al. [19] describes the most common molecular procedures used for NHL and their potential application on FNC material, and the article by Stacchini et al. [20]

focuses on small samples and specific technical solutions. In conclusion, the six features highlighted by Calvino identify qualities shared by FC, which can be fully exploited in the diagnosis of LN-FNC and represent the basis for the application of specific molecular procedures.

Acknowledgements

The author would like to thank all the authors who have generously contributed to this issue, Prof. Kari Syrjänen for promoting and encouraging the issue, and Rebecca Ganz and Manuela Obrist for their precious assistance.

References

- 1 Proust M: *A la recherche du temps perdu*. Paris, Gallimard, 1999.
- 2 Wolf V: *Mrs Dalloway*. London, Penguin, 2000.
- 3 Mace JH, Clevinger AM, Bernas RS: Involuntary memory chains: what do they tell us about autobiographical memory organization? *Memory* 2013;21:324–335.
- 4 Calvino I: *Six Memos for the Next Millennium*. London, Penguin, 2009.
- 5 Katz RL, et al: Fine-needle aspiration cytology of peripheral T-cell lymphoma: a cytologic, immunologic, and cytometric study. *Am J Clin Pathol* 1989;91:120–131.
- 6 Sneige N, et al: Cytomorphologic, immunocytochemical, and nucleic acid flow cytometric study of 50 lymph nodes by fine-needle aspiration: comparison with results obtained by subsequent excisional biopsy. *Cancer* 1991;67:1003–1007.
- 7 Barroca H, Marques C: A basic approach to lymph node and flow cytometry fine-needle cytology. *Acta Cytol* 2016;60:284–301.
- 8 Cozzolino I, Rocco M, Villani G, Picardi M: Lymph node fine-needle cytology of non-Hodgkin lymphoma: diagnosis and classification by flow cytometry. *Acta Cytol* 2016;60:302–314.
- 9 Zeppa P, Cozzolino I, Peluso AL, Troncone G, Lucariello A, Picardi M, Carella C, Pane F, Vetrani A, Palombini L: Cytologic, flow cytometry, and molecular assessment of lymphoid infiltrate in fine-needle cytology samples of Hashimoto thyroiditis. *Cancer* 2009;117:174–184.
- 10 Stacchini A, Demurtas A, Aliberti S: Extracapsular lymphoproliferative processes and flow cytometry. *Acta Cytol* 2016;60:315–325.
- 11 VanderLaan PA, Wang HH, Majid A, Folch E: Endobronchial ultrasound-guided transbronchial needle aspiration (EBUS-TBNA): an overview and update for the cytopathologist. *Cancer Cytopathol* 2014;122:561–576.
- 12 Harris CL, Toloza EM, Klapman JB, Vignesh S, Rodriguez K, Kaszuba FJ: Minimally invasive mediastinal staging of non-small-cell lung cancer: emphasis on ultrasonography-guided, fine-needle aspiration. *Cancer Control* 2014;21:15–20.
- 13 Zeppa P, Barra E, Napolitano V, Cozzolino I, Troncone G, Picardi M, De Renzo A, Mainenti PP, Vetrani A, Palombini L: Impact of endoscopic ultrasound-guided fine needle aspiration (EUS-FNA) in lymph nodal and mediastinal lesions: a multicenter experience. *Diagn Cytopathol* 2011;39:723–729.
- 14 Jin M, Wakely PE: Endoscopic/endobronchial ultrasound-guided fine needle aspiration and ancillary techniques, particularly flow cytometry, in diagnosing deep-seated lymphomas. *Acta Cytol* 2016;60:326–335.
- 15 Pillai V, Dorfman DM: Flow cytometry of non-hematopoietic neoplasms. *Acta Cytol* 2016;60:336–343.
- 16 Silowash R, Pantanowitz L, Craig FE, Simons JP, Monaco SE: Utilization of flow cytometry in pediatric fine-needle aspiration biopsy specimens. *Acta Cytol* 2016;60:344–353.
- 17 Bode-Lesniewska B: Flow cytometry and effusions in lymphoproliferative processes and other hematologic neoplasias. *Acta Cytol* 2016;60:354–364.
- 18 Davidson B: Malignant nonhematological effusion characterization by flow cytometry. *Acta Cytol* 2016;60:365–371.
- 19 Peluso AL, Ieni A, Mignogna C, Zeppa P: Lymph node fine-needle cytology: beyond flow cytometry. *Acta Cytol* 2016;60:372–384.
- 20 Stacchini A, Demurtas A, Aliberti S, Barreca A, Novero D, Pacchioni D: Single-tube flow cytometry assay for the detection of mature lymphoid neoplasms in paucicellular samples. *Acta Cytol* 2016;60:385–394.